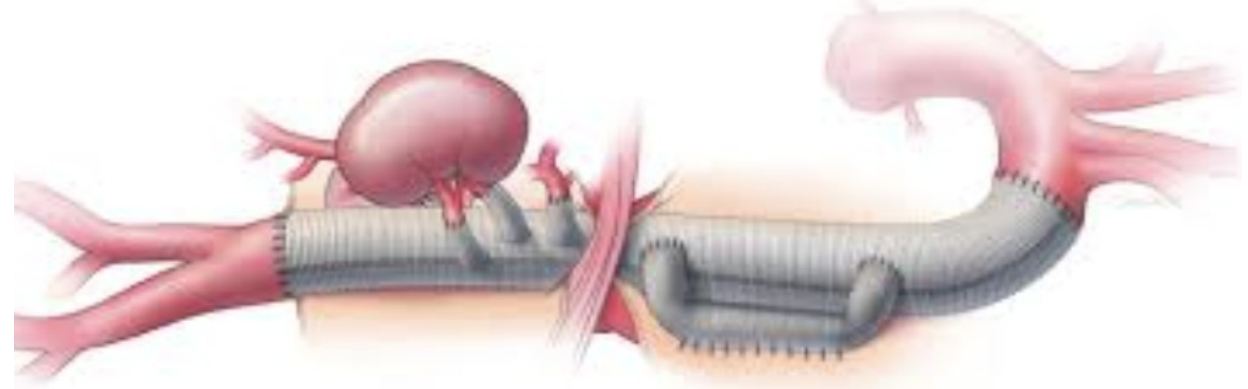




THE UNIVERSITY OF
CHICAGO
MEDICINE



Split- Body Circulation with Continuous Cerebral, Abdominal and Spinal Cord Prefusion for Thoracoabdominal Aortic Aneurysm Repair: A Novel Technique and Perfusion Strategy

Miroslav Peev, MD FACS FACC

Assistant Professor in Surgery

Associate Director, Residency Program in Cardiac and Thoracic Surgery



University of Chicago Medicine Center for Aortic Diseases (UCCAD)

03/07/2026

Background

Outcomes of 3309 thoracoabdominal aortic aneurysm repairs

Read at the 95th Annual Meeting of The American Association for Thoracic Surgery, Seattle, Washington, April 25-29, 2015.

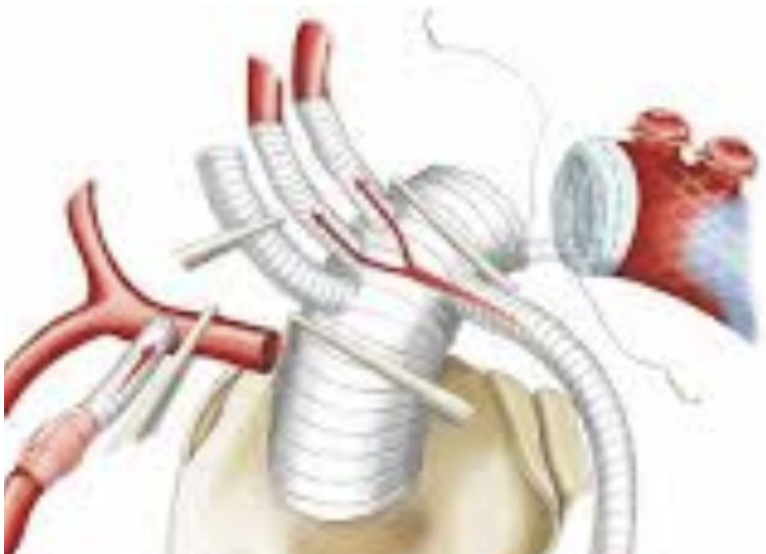Joseph S. Coselli MD^{a d e}  , Scott A. LeMaire MD^{a b c d e}, Ourania Preventza MD^{a d e}, Kim I. de la Cruz MD^{a d e}, Denton A. Cooley MD^d, Matt D. Price MS^{a d}, Alan P. Stolz MEd^{a d}, Susan Y. Green MPH^{a d}, Courtney N. Arredondo MSPH^b, Todd K. Rosengart MD^{a c d e}

- mortality 7.5%
- paraplegia 2.4%
- permanent renal failure
- permanent stroke 2.5%
- composite adverse events 19%

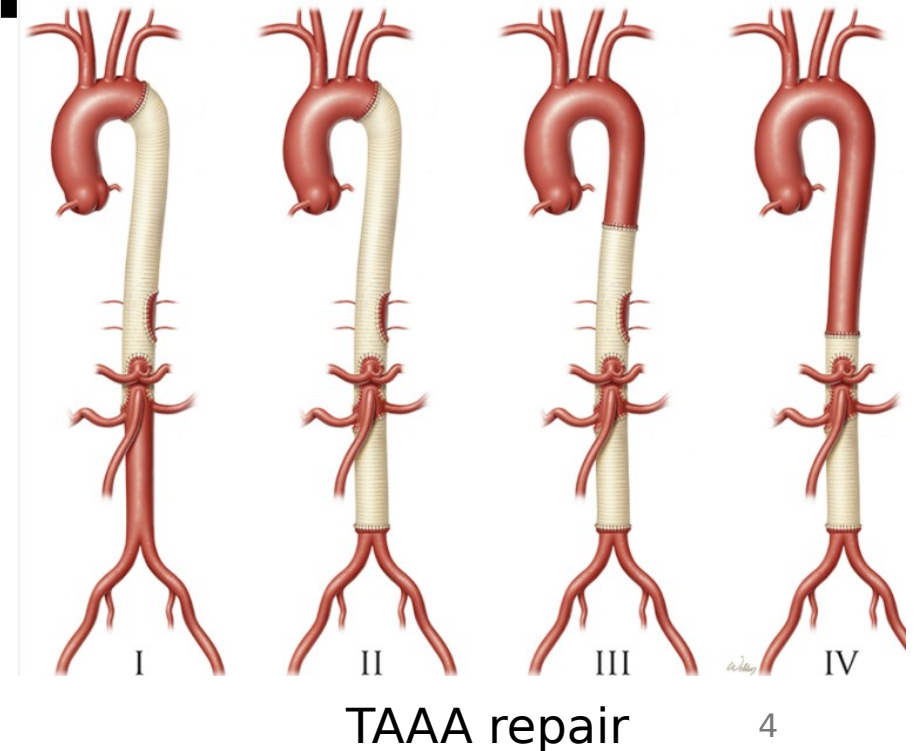
How to Improve the TAAA **OPEN**
repair outcomes?

Our Technique

Split- Body Circulation with Continuous Cerebral, Abdominal and Spinal Cord Prefusion for Thoracoabdominal Aortic Aneurysm Repair: A Novel Technique and Perfusion Strategy



Aortic Arch Surgery



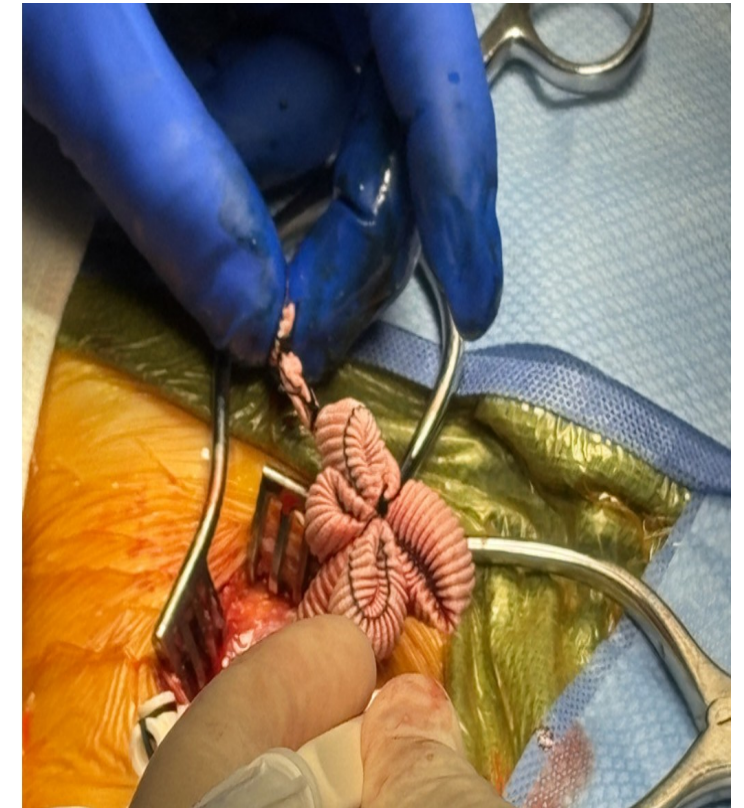
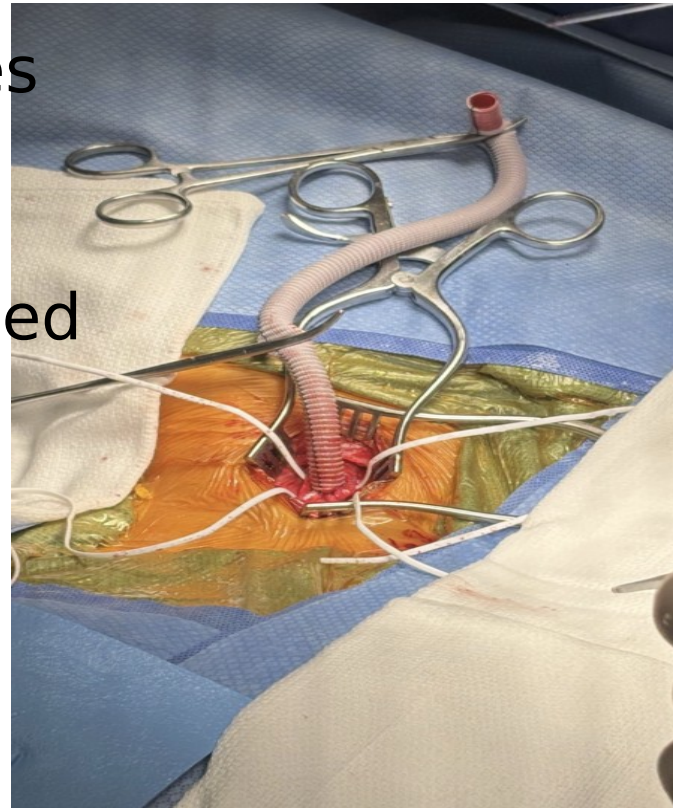
TAAA repair

Main Principle

Maintain constant body perfusion

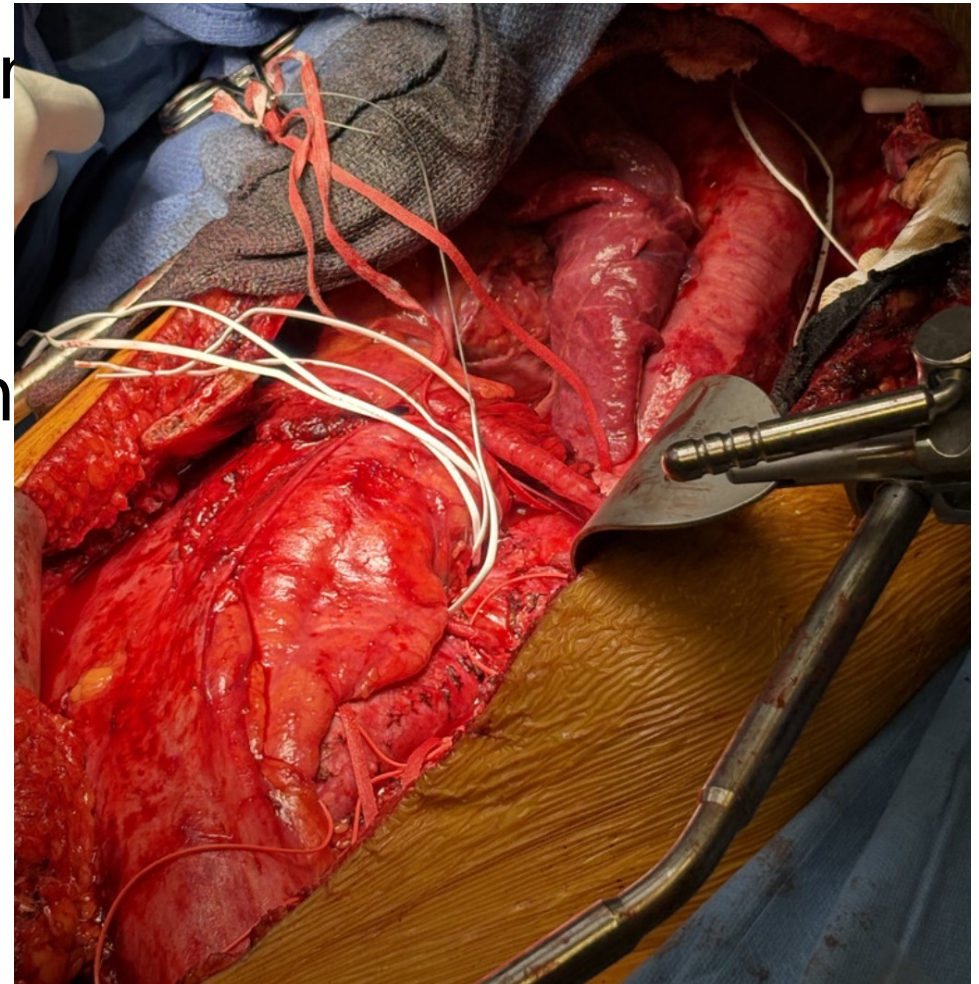
Operative Step # 1

- Setup
 - Bilateral radial A lines
 - Fem A line
 - Fem V line
 - Keep left neck exposed
- Supine
- LCC artery cutdown
- 8mm chimney graft



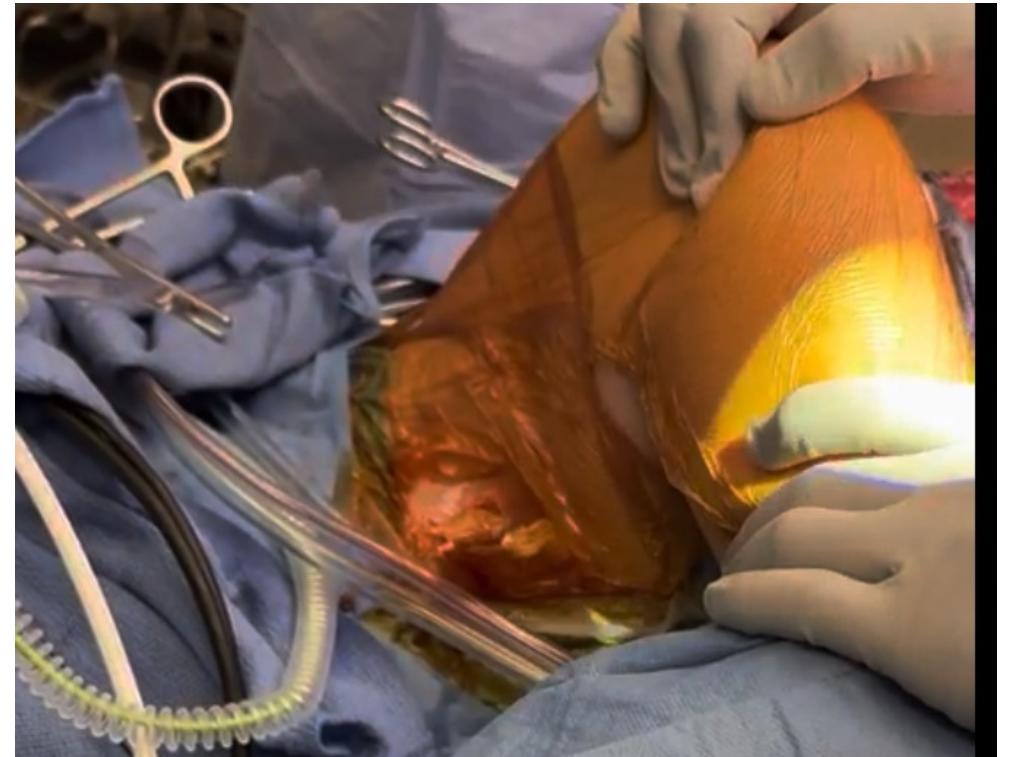
Operative Step # 2

- Modified R lat decubitus position
- Open chest (4-5ICS) and RP
- Cryoablation chest
- Do NOT transect the diaphragm
- Initial dissection
 - Aorta
 - LSA
 - Abdominal branches
 - SMA/Celiac/L renal



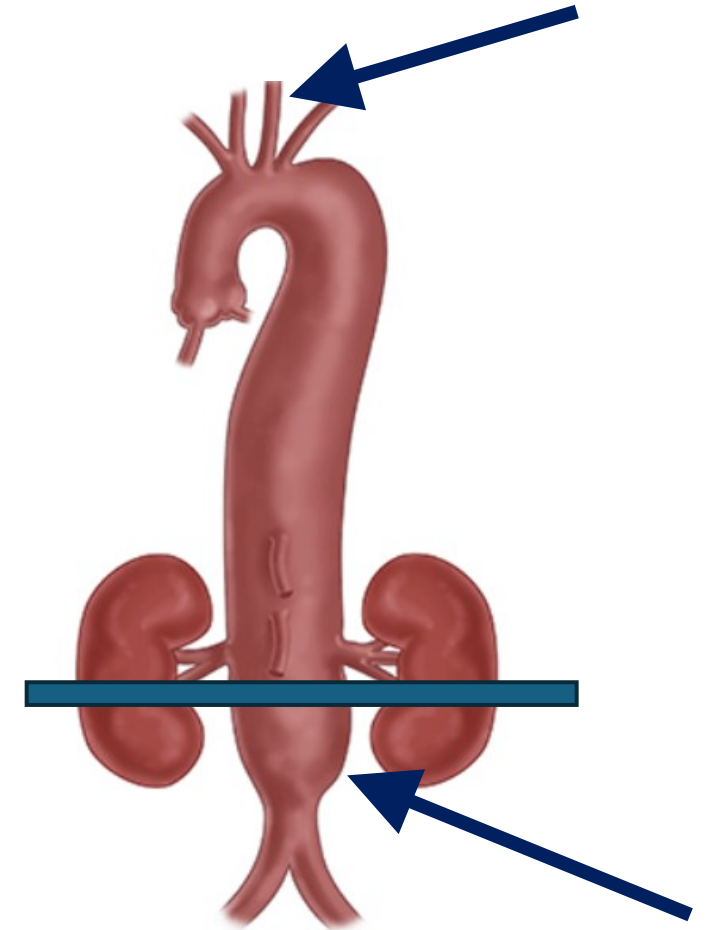
Operative Step # 3

- Heparin
- Percutaneous Fem vein cannulation
- Retrieve chimney graft from the neck
- CPB (Fem Vein + LCC chimney graft)
- CPB and cool to 28 C
- (if AI - LV vent)



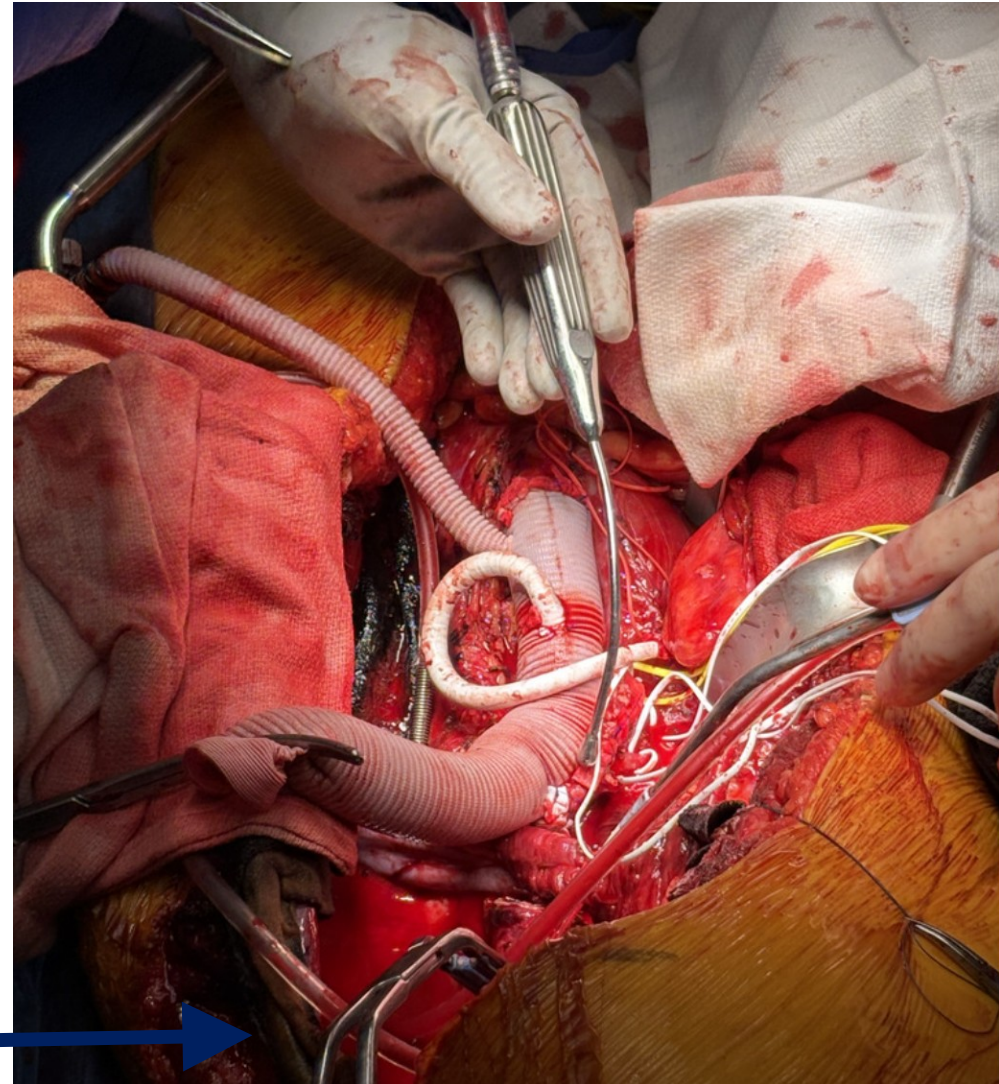
Operative Step # 4

- While cooling
 - A:
 - Clamp below renal arteries
 - Entire upper body perfused via LCC
 - B
 - Create distal anastomosis w Chimney graft
 - C
 - Reinitiate SPLIT body perfusion
 - LEGS from chimney graft
 - KIDNEYS and up from LCC



Operative Step # 5

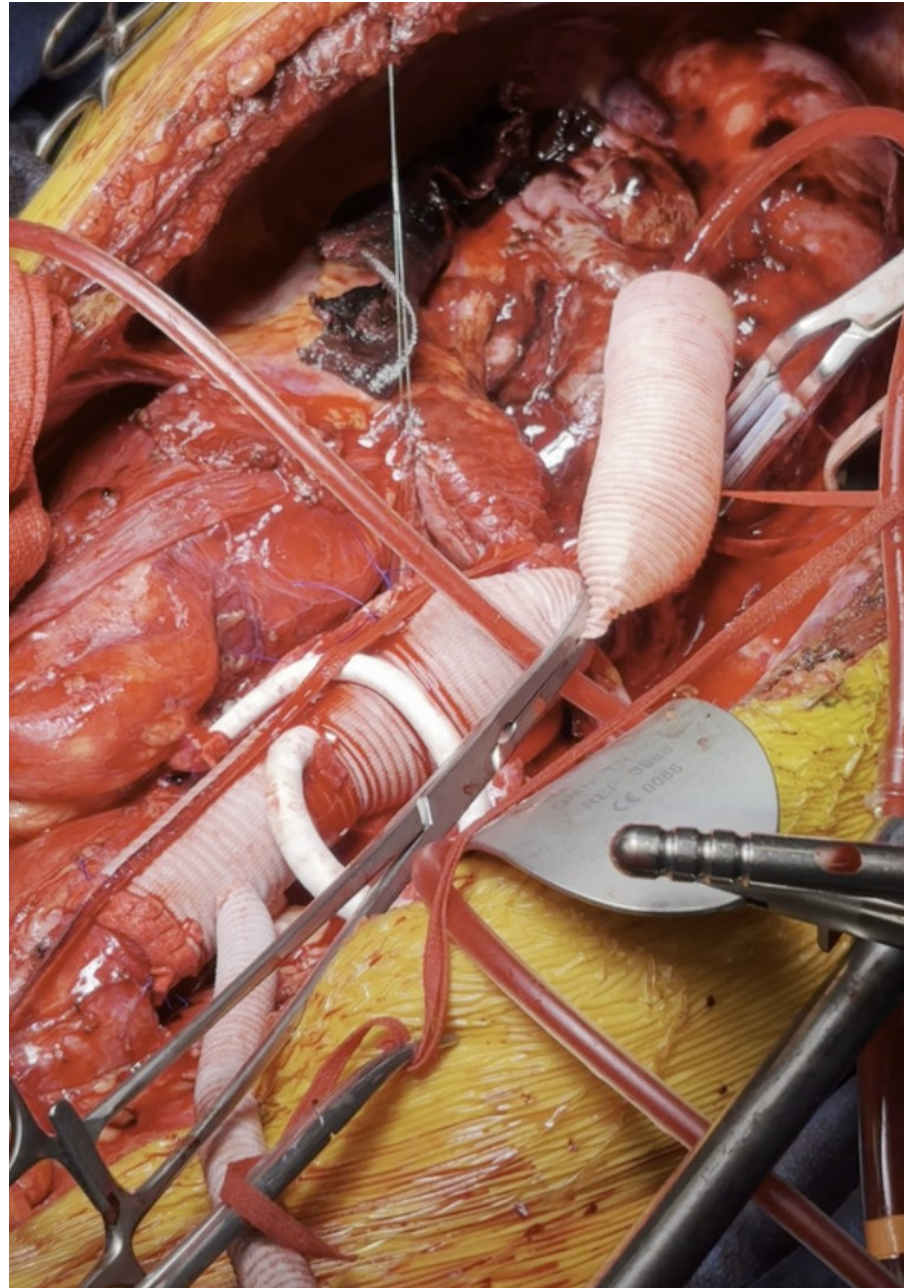
- Clamp at diaphragm
 - Sequentially attach each of visceral vessels and continue perfusion during anastomosis
- Balloon catheters



**LEG
S**

**HEA
D**

**LEG
S**

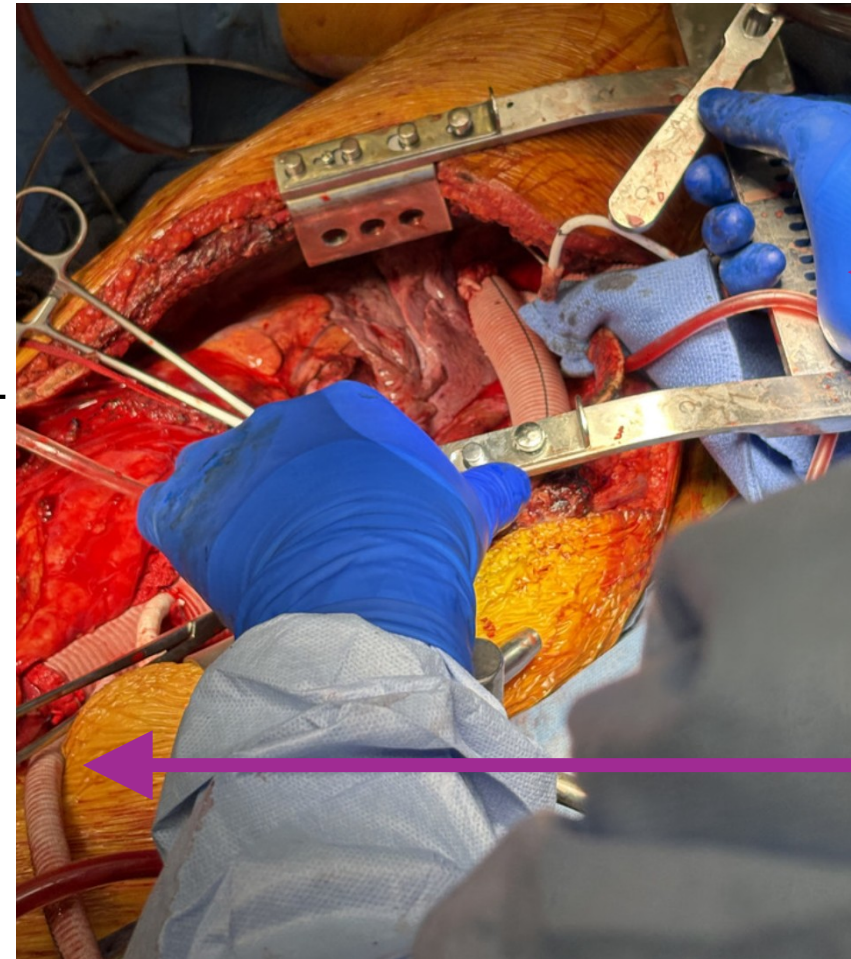


**HEA
D**

Operative Step # 6

- Proximal anastomosis
 - Open
 - **Modified Circulatory arrest**
 - Visceral organs + legs perfused due to
 - Split body circulation
 - Spinal cord perfused from lower body + Pressurized LSA (seen on L radial A line)
 - Unilateral cerebral perfusion
 - Chimney graft for the proximal anastomosis
 - Intercoastal island reimplantation
 - Graft to graft anastomosis

**LEG
S**



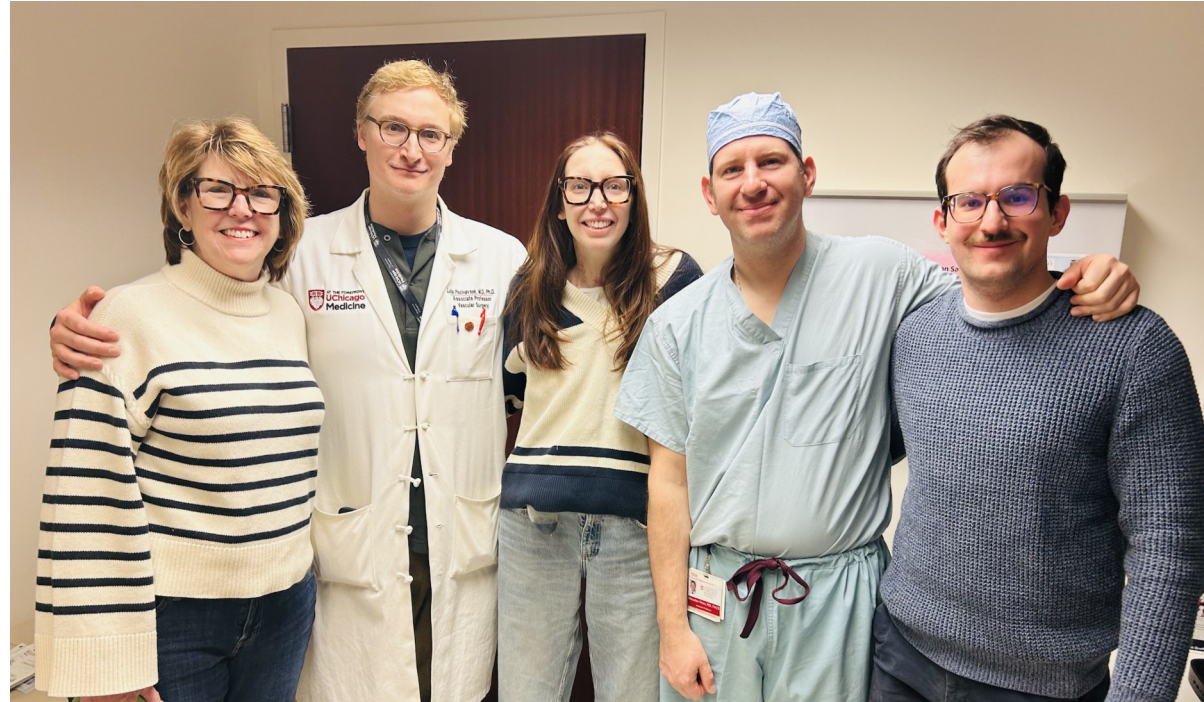HAD

Pilot Outcomes

- N = 3 (Marfan)
- 30-day Mortality none
- Spinal drain use 1 (preop)
- Mean postop Crea 0.91mg/dl
- Mean postop lactate 2.9mmol/l
- Mean postop AST/ALT 19.7 U/l
AST 50.6 U/l, ALT
- Stroke none
- Spinal cord ischemia none
- Paraplegia none

Conclusion

Our technique allows for constant cerebral, spinal cord and perivisceral perfusion optimizing the physiologic conditions at time of highly complex and demanding operation



Thank You

Miroslav.Peev@bsd.Uchicago.edu

Back up slides

Background

- Thoracoabdominal aneurysm repair is a highly complex operation



	Overall	Extent II aneurysm
Mortality	5-10%	10-15%
Spinal Cord Ischemia	3-8%	8-15%
Renal Failure (all)	10-20%	10-20%
Renal Failure - Dialysis	5-10%	5-10%
Respiratory complications	20-40%	20-40%
Visceral Ischemia (liver, bowel, pancreas)	2-8%	2-8%
Stroke (open proximal anastomosis)	4-11%	4-11%

Contemporary outcomes of open thoracoabdominal aortic aneurysm repair in the endovascular era

[Alexander D. DiBartolomeo, MD, MS^a](#) · [Sebouh Bazikian, MD^a](#) · [Jesse Han, MD^a](#) · ... · [Fred A. Weaver, MD, MMS^a](#) ·

Review article

A systematic review and meta-analysis of early outcomes after endovascular versus open repair of thoracoabdominal aortic aneurysms

[Rodolfo V. Rocha MD^a](#), [Jan O. Friedrich MD, DPhil^b](#), [Malak Elbatarny BSc^a](#), [Bobby Yanagawa MD, PhD^c](#), [Mohammed Al-Omran MD, MSc^d](#), [Thomas L. Forbes MD^e](#), [Thomas F. Lindsay MD^e](#), [Maral Ouzounian MD, PhD^a](#)  

Systematic Review and Meta-analysis of the Outcomes After Repair of Thoracoabdominal Aneurysms with the t-Branch Off-the-shelf Multibranch Stentgraft

[Nikolaos Konstantinou¹](#) · [Constantine N. Antonopoulos^{1,2}](#) · [Thomas Jerkku¹](#) · ... · [Tilo Kölbel³](#) · [Beatrice Fiorucci¹](#) ·