

Hybrid Reconstruction of Cervical Aortic Arch Aneurysm

**Ioana Florea, MD, MPHS; Mark Zemela, MD; Alec Schubert, MD; Philip Batista,
MD; Jason Han, MD**

Cooper University Hospital

Camden, NJ

Houston Aortic Symposium

The Eighteenth in the Series

March 05-07, 2026

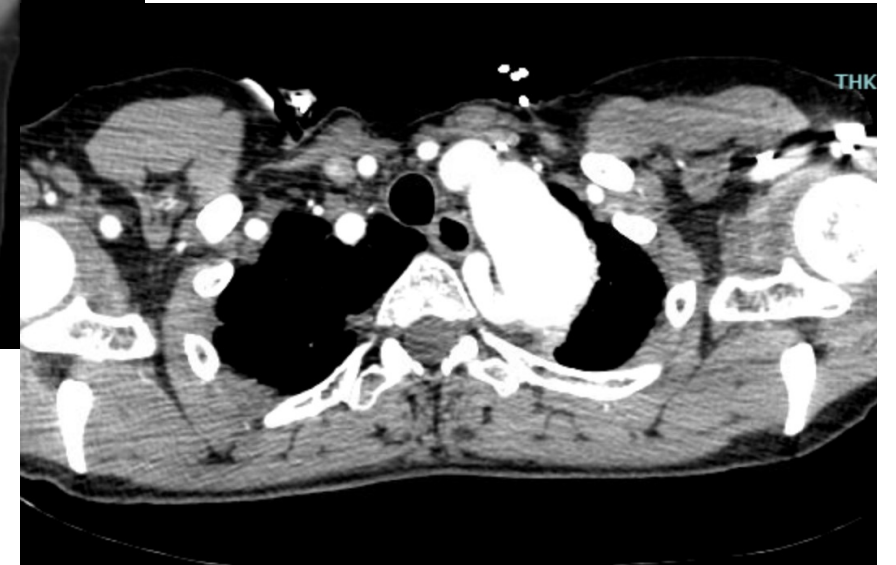
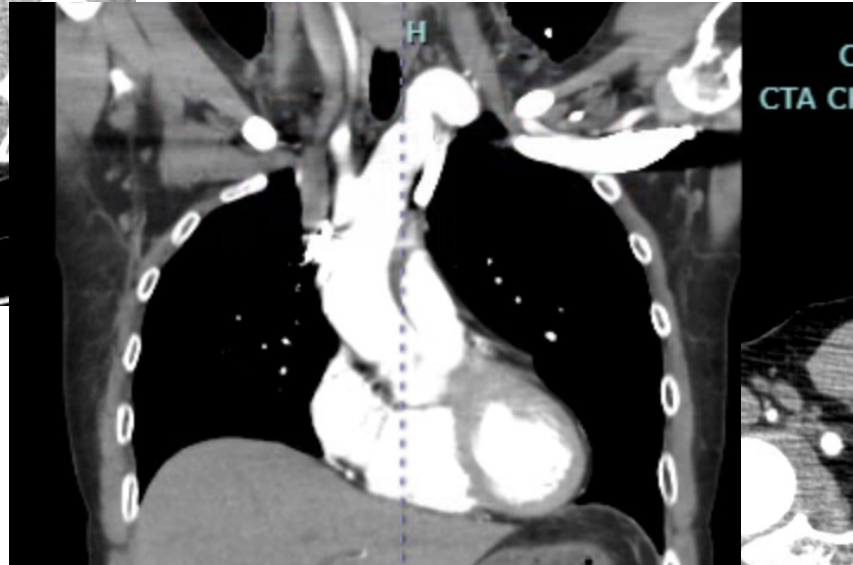
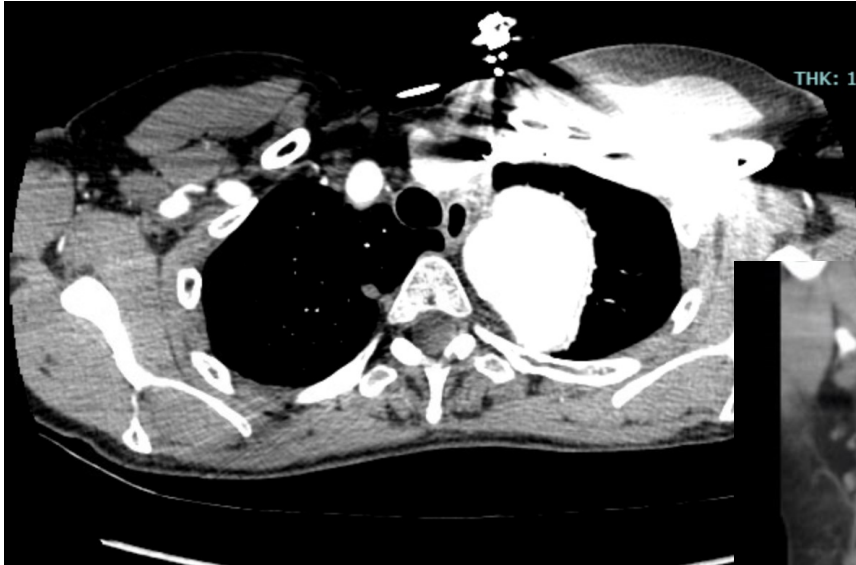
Disclosures

I have no conflicts to disclose

Case Presentation

- **63yo F, cervical aortic arch w Zone II aneurysm**
- **Progressive Expansion in Size: 3.8cm (2023) → 5.2cm (2025)**

Case Presentation



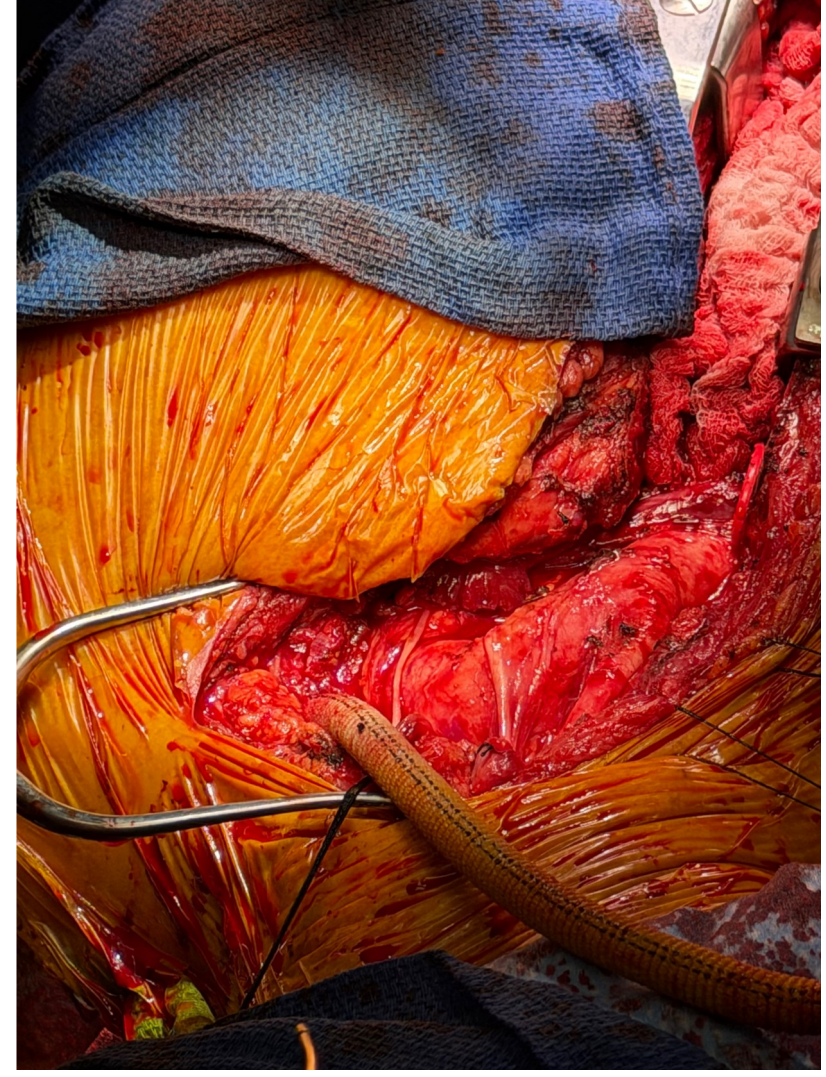
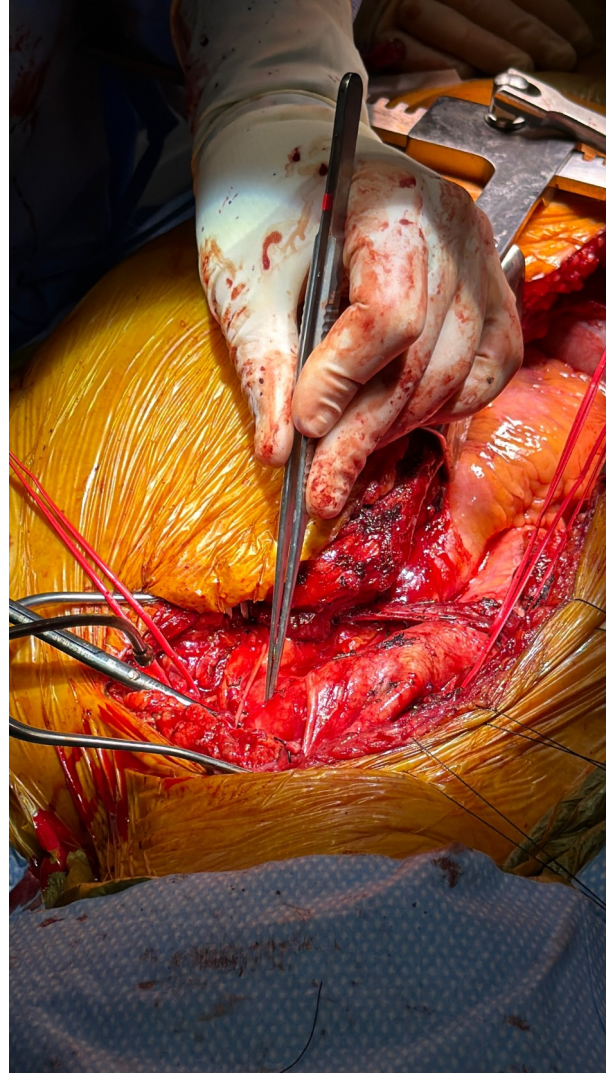
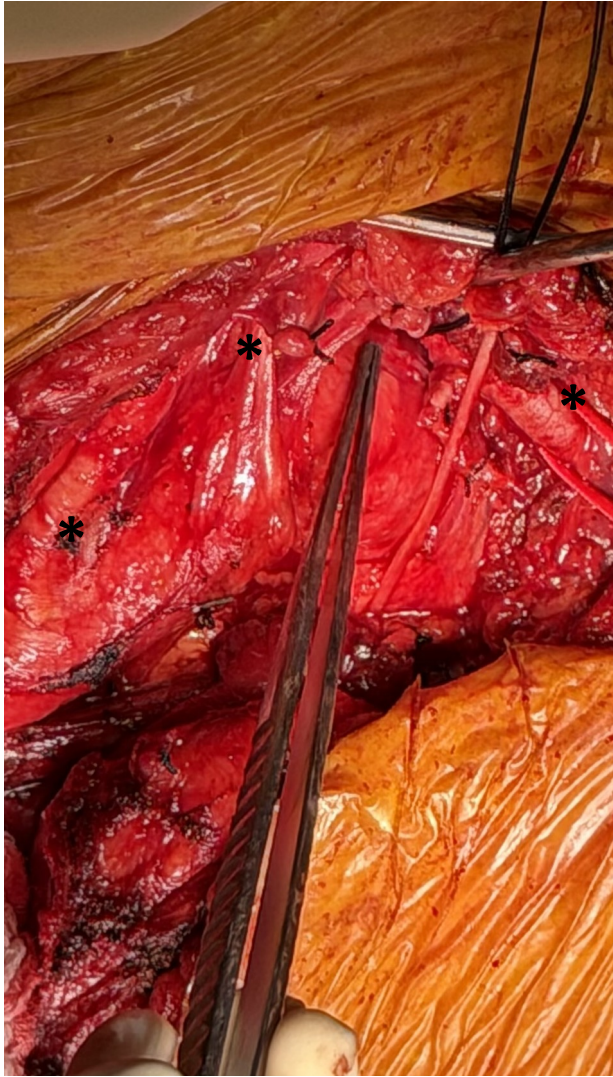
Case Presentation

- **63yo F, cervical aortic arch w Zone II aneurysm**
- **Progressive Expansion in Size: 3.8cm (2023) → 5.2cm (2025)**
- **CTA: Sharp coarctation above the clavicle in Zone, aberrant posterior origin of L subclavian artery**
- **TTE: Normal biventricular function (EF 55-60%), tri-leaflet AV w mild AI**

Operative Approach

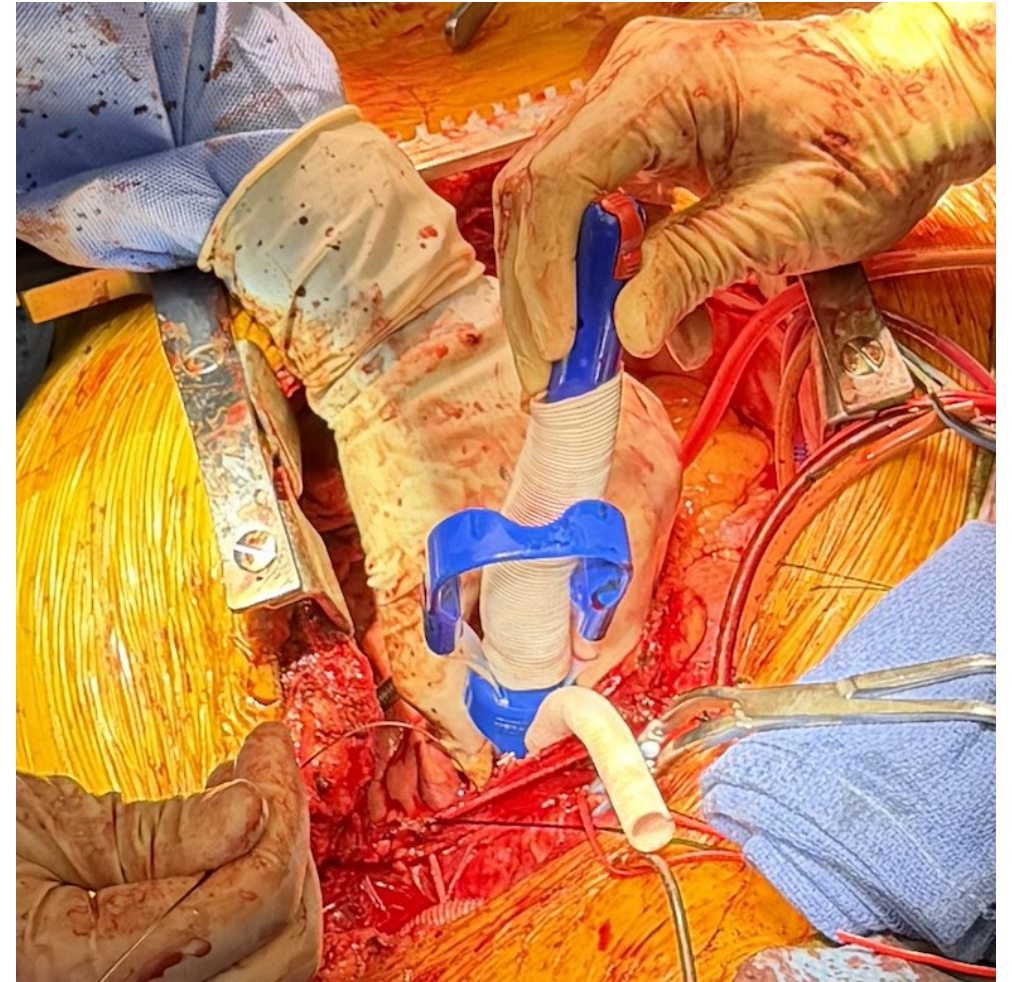
- **A median sternotomy was performed with a L supraclavicular extension**
- **Left common femoral artery and vein cutdown, Right percutaneous groin access**
- **L subclavian to carotid bypass performed w 8mm Dacron graft**

Operative Approach



Operative Approach

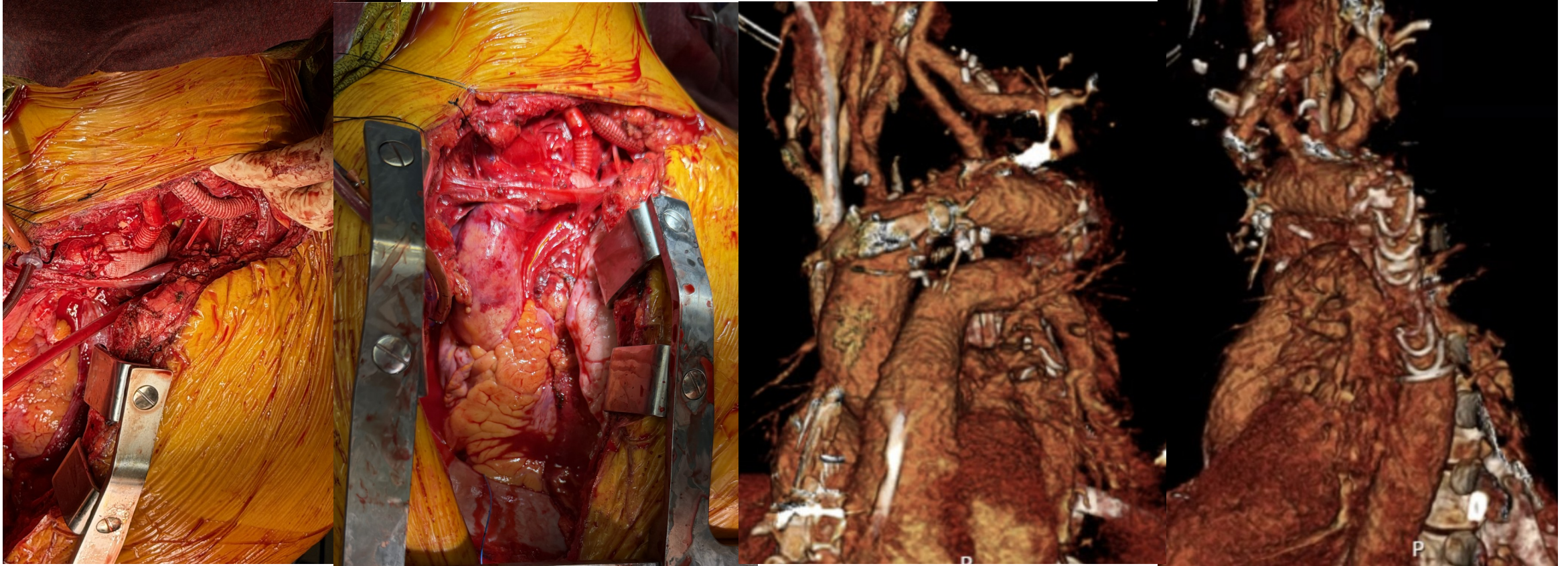
- **CBP established at the L groin; patient cooled to 24 deg Celsius**
- **Additional arterial canula placed in the innominate artery**
- **Cross Clamp in Zone II**
- **Thoraflex 24 x 100mm endovascular graft deployed**



Operative Approach

- **Aortic cross clamped moved to Zone I**
- **The L common carotid cannulated and ACP established**
- **Proximal anastomosis of the Thoraflex to Zone I was completed**
- **L common carotid anastomosed to the Thoraflex with an 8mm interposition Dacron graft**

Operative Approach



Post-Operative Course

- **Intra-Op SSEP Monitoring: Mild right upper and lower extremity attenuation**
- **Seizure activity POD 1 with persistent right sided weakness**
- **CT: No evidence of ischemia or hemorrhage**
- **Cerebral Angiogram: Diffuse narrowing of intracranial vasculature**
- **Discharged home POD 14. Recovering appropriately on follow-up w excellent functional status**

Thank You!