

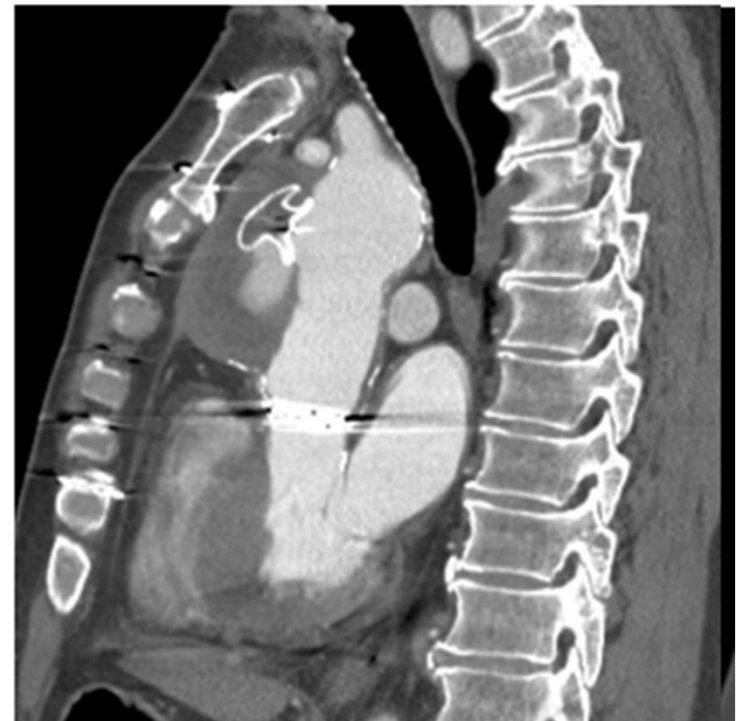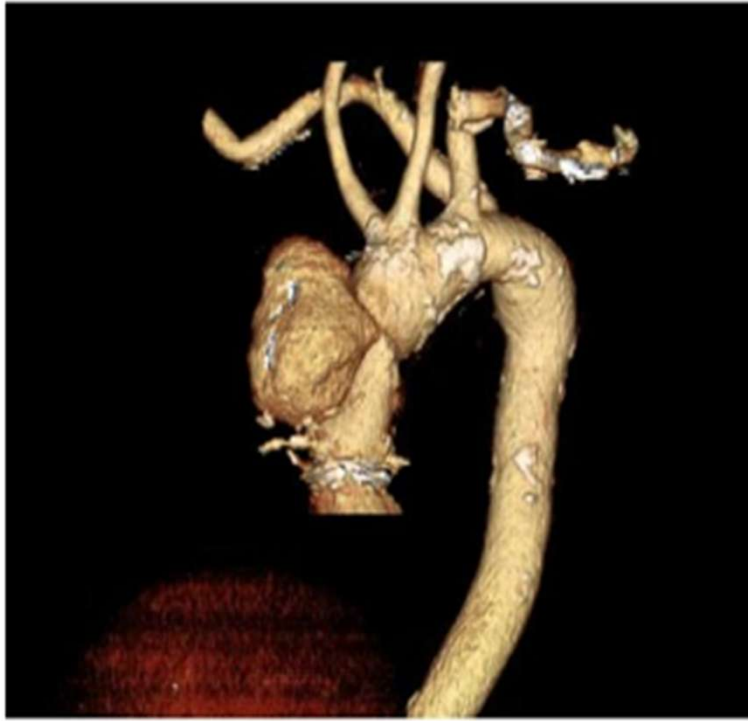Endovascular Repair of the Ascending Aorta and Root

Aamir Shah, MD

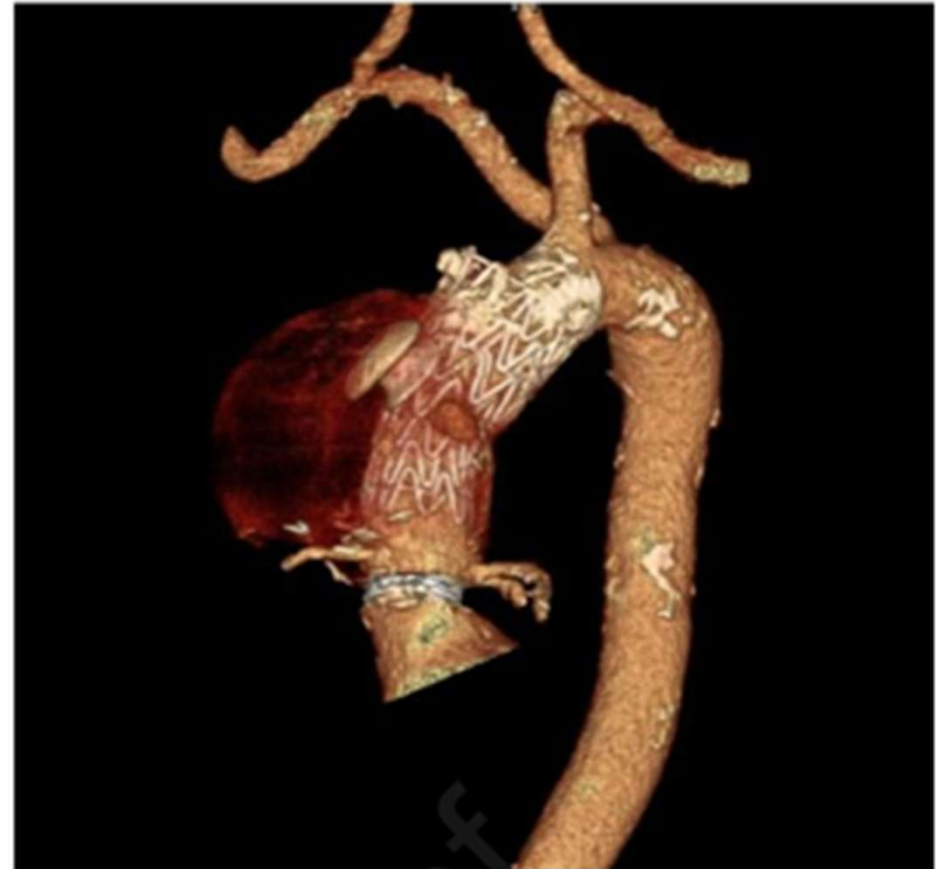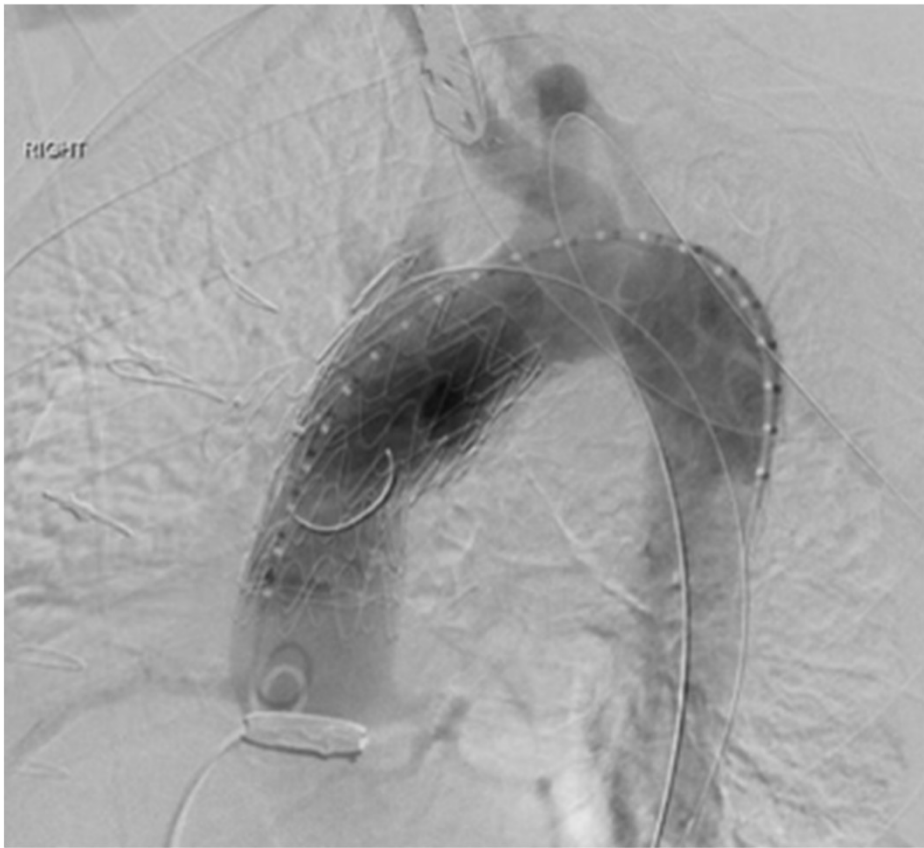
Associate Professor
Cardiothoracic and Vascular Surgery
Univ of Texas Medical Center at Houston

March 2026

Case Report

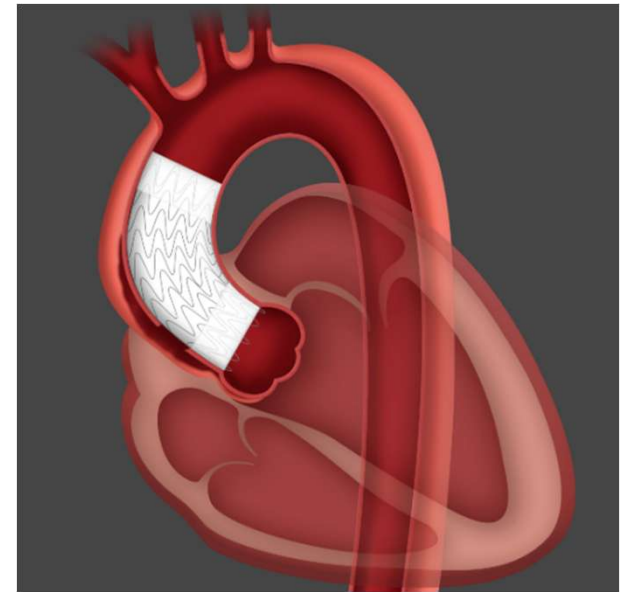
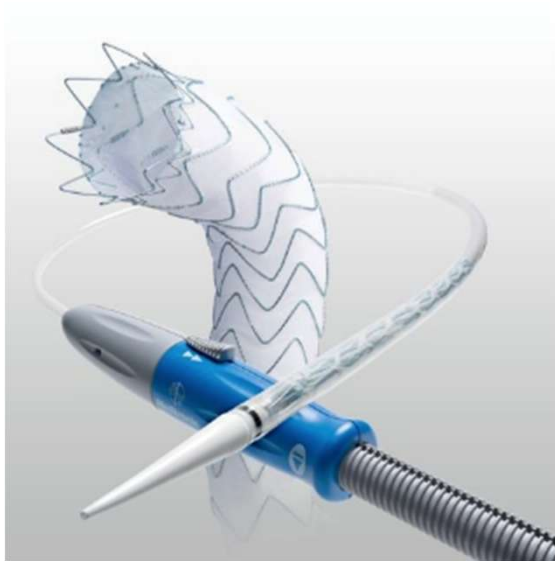

- 68 yo male s/p repair asc aorta/root aneurysm 1984 with mech valve conduit with recurrent pseudoaneurysm at distal anastomosis 6.5 cm diameter, attempted surgical repair 2/2023
- Percutaneous pseudoaneurysm repair with septal occluder 6/23



- **Challenge: Common origin bilat CCA, aberrant RSA, proximity of coronary ostia**
- **Staged repair:**
 - **Arch debranch bilateral CCA to subclavian artery transposition**
 - **Zones 0-1 TEVAR with prox LZ 1 cm above RCA, rapid V pacing**

TEVAR Ascending Aorta

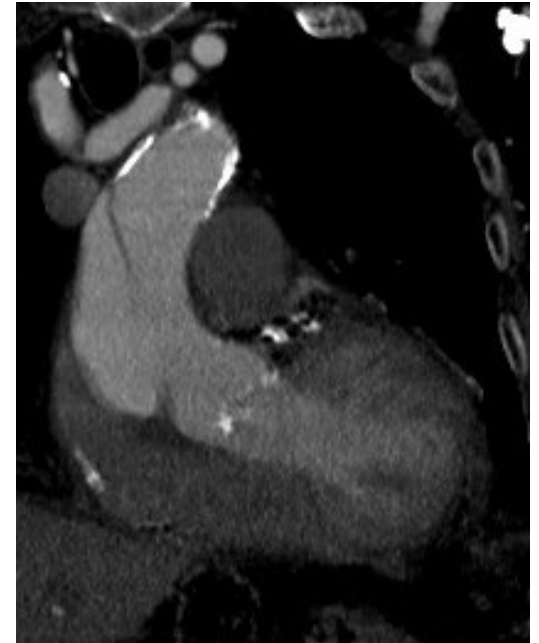


- TEVAR approved by US FDA in 2005 for commercial use
- Rapid expansion indications include thoracic aortic aneurysms, acute and chronic dissections, traumatic aortic injury, IMH, PAU
- Ascending aorta treated with devices designed for desc aorta – 2000
[Doros J Endovasc Ther 2000;7:506](#)
- First successful TEVAR for ATAAD with endograft designed for asc aorta - 2010
[Metcalf, J Vasc Surg 2012;55:220](#)
- Dedicated stent grafts developed, no current commercially available devices for ascending aorta
- ARISE II trial: ongoing clinical trial Gore ASG

[Roselli J Endovasc Ther 2023;30:550](#)

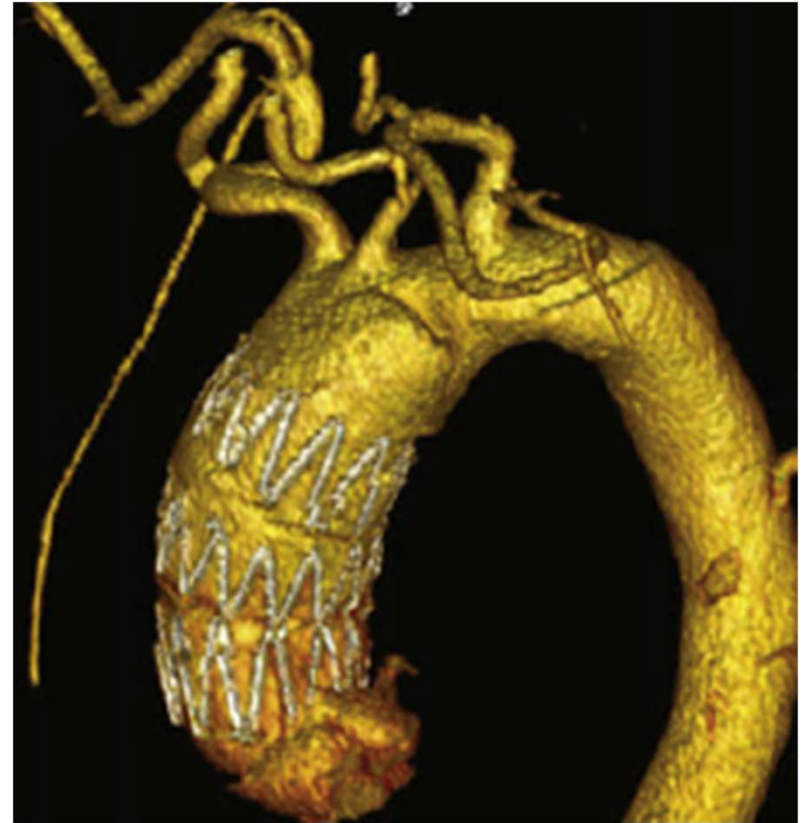Ascending Aorta: Hostile Environment

- Volatile hemodynamics
 - 17% change diameter 5 mm distal to coronary arteries during cardiac cycle
 - 14% change diameter 5 mm proximal to innominate artery
- Variable anatomy within concentrated space, increased compliance
- Short landing zone, proximity of coronary arteries, aortic valve, LV, brachiocephalic arteries
- Non-cylindrical lumen
 - Greater curvature length 30% > lesser curve
 - Short radius of curvature



Ascending Aorta: Hostile Environment

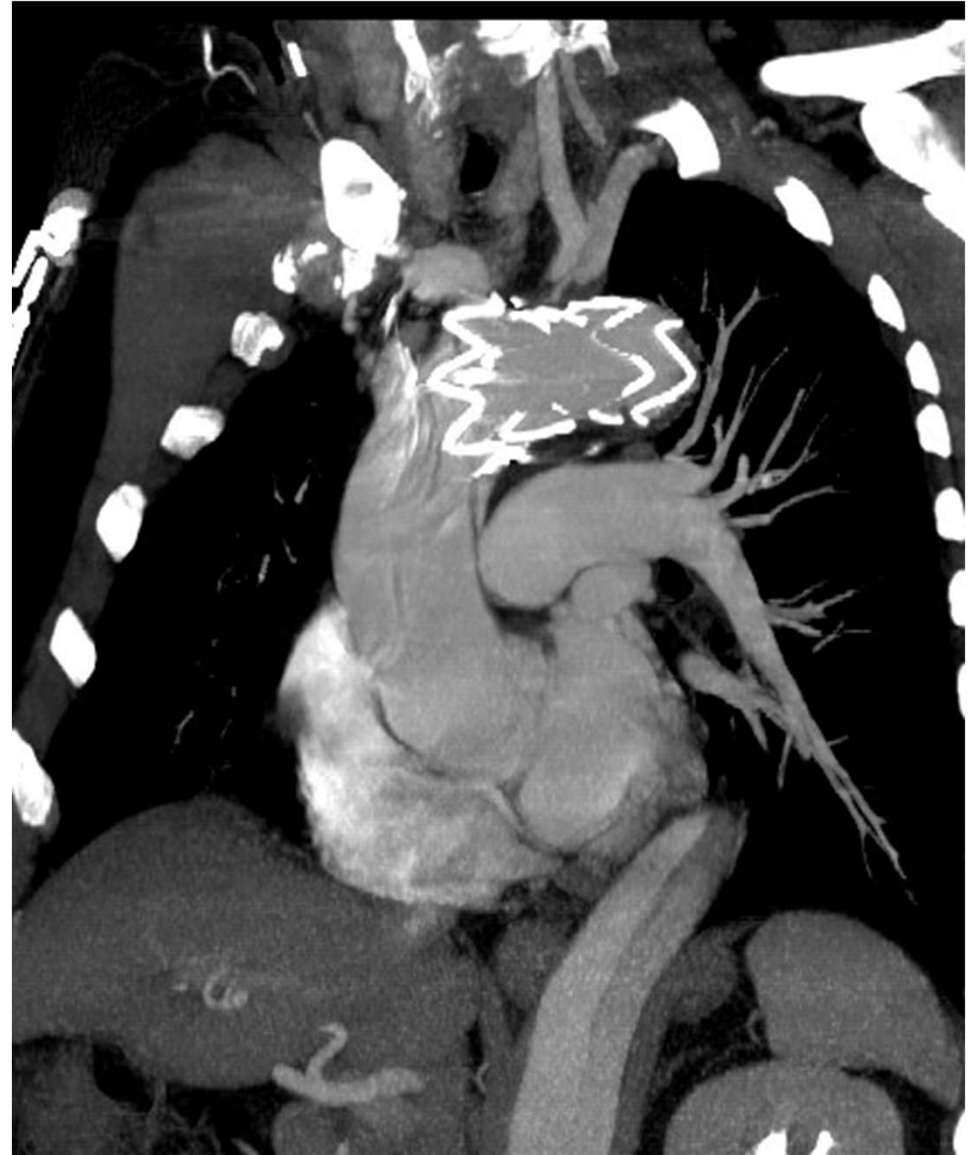- Complications
 - Stroke up to 10%
 - Coronary malperfusion/MI
 - Aortic valve incompetence
 - Left ventricular injury
 - Retrograde Type A Dissection (RTAAD)



Ascending Aorta: Hostile Environment

- RTAAD 1.3-8%
 - Trauma from TEVAR
 - Device properties
 - Semi-rigid
 - Proximal bare spring
 - Oversizing > 10–20 %
 - Aortic diam > 38 mm
 - Relative risk 5.3 for dissection vs aneurysm *
 - Mortality 30-40% *

Chen. JAHA2017.22;6(9)



Anatomic Requirements Ascending TEVAR

Proximal and distal landing zones

Length >10 mm

Diameter >16 and <42 mm

No significant difference between proximal and distal landing zone (<10%)

Absence of calcification or thrombotic material

Aortic dissection

Intimal tear >10 mm above the sinotubular junction

Intimal tear >5 mm proximal to the innominate artery

No aortic regurgitation

Access vessels

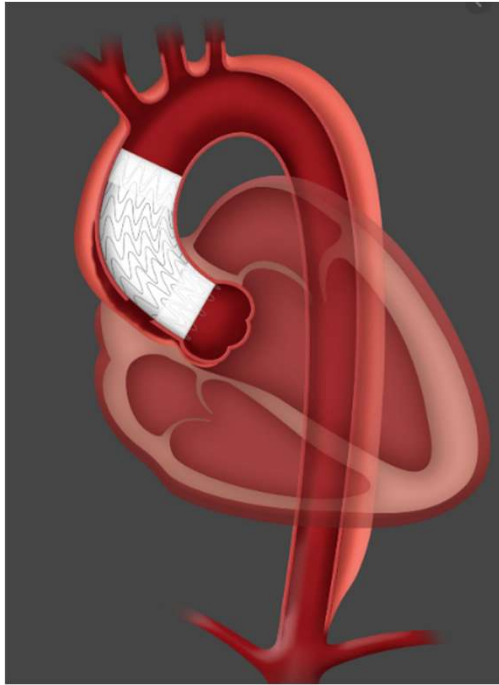
Diameter of the common and external iliac artery >7 mm

- 30-50% of patients anatomically suitable treatable TEVAR segment
- Absence of severe AI, cardiac tamponade, patent coronary artery bypass grafts, involvement of aortic root, or CTD
- Maximum oversize 5-10%


Moon, J Vasc Surg 2011;53:942

Sobocinski, Eur J Vasc Endovasc Surg 2011;42:442

New Ascending Stent graft (ASG)



- GORE ASG FDA IDE
- ARISE EFS study
- Site specific design (ascending aorta)
- Staged deployment to 50% diameter
- Approved for 9 sites
- 19 pts, MACCE 16%, CVA 5%, MI 5%
[J Endovasc Ther 2023;4:550](#)



Proximal angulation control
Available diameter 31-45 mm, length 7 - 10
cm

Arise II enrolling 370 high risk pts 27 sites, nonacute type A pathologies

Endovascular repair of the ascending aorta in the Vascular Quality Initiative

Jasper F. de Kort, MD,^{a,b,c} Tim J. Mandigers, MD, PhD,^{a,b,d} Gabriel Jabbour, MS,^d Sara Allievi, MD,^{a,d} Sai Divya Yadavalli, MD,^d Vinamr Rastogi, MD,^e Sara L. Zettervall, MD, MPH,^f Thomas F. X. O'Donnell, MD,^g Joost A. van Herwaarden, MD, PhD,^b Santi Trimarchi, MD, PhD,^{a,h} and Marc L. Schermerhorn, MD,^d *Milan, Italy; Utrecht and Rotterdam, The Netherlands; Boston, MA; Seattle, WA; and New York, NY*

- VQI analysis 2013-2022 Endovascular repair isolated to ascending aorta both proximal and distal LZs
- 44 patients, 19 centers, median age 76
- Pathologies: Symptomatic 59%, rupture 4.5%, 43%
- Aortic dissection 36% acute, 11% chronic; **48% mortality peri-op**
 - PAU with IMH 16%; **14% mortality**
 - PSA 11%; **0% mortality**
 - Post-dissection aneurysm 9%; **mortality 25%**
 - Degenerative Aneurysm fusiform 6.8%, saccular 6.8%; **mortality 0%**

VQI Findings

- 18% with > 1 device implanted
- Treatment within 4 hrs 23%, 24 hrs 20%
- Access: femoral alone 55%, supra-aortic trunk 30%
- Complications:
 - Conversion to sternotomy: one (2.3%)
 - Type 1B endoleak one (2.3%)
 - Reintervention 6.8%
 - CVA 2.3%
 - AKI 14%
- **3 year mortality:** Dissection-related 52%, PAU 37%, Aneurysm 17%

Editor's Choice – Outcomes of Endovascular Repair Confined to the Ascending Thoracic Aorta: A Systematic Review and Meta-Analysis

Jasper F. de Kort ^{a,b,*}, Tim J. Mandigers ^{a,b}, Daniele Bissacco ^c, Maurizio Domanin ^{a,c}, Gabriele Piffaretti ^d, Christopher P. Twine ^e, Anders Wanhainen ^{f,g}, Joost A. van Herwaarden ^b, Santi Trimarchi ^{a,c}, Carlo de Vincentiis ^h

- 19 cohort studies, 75 case report/series
 - 259 pts, mean age 69
 - Indications: 52% urgent, 44% TAAD, PSA 39%
 - Overall 30 day mortality 7.7%, 17% during follow up
 - Reoperation 13%
 - 30 day mortality TAAD: 13%, PSA 4%
- Eur J Vasc Endovasc Surg 2025;69:531

The Endo-Bentall Procedure in the Treatment of Ascending Aorta Pathologies: A Scoping Review

Maysam Shehab ^{a,*}, Carlota F. Prendes ^a, Anders Wanhainen ^{a,b}, Rickard Lindblom ^c, Stefan James ^d, Kevin Mani ^a

^aDepartment of Surgical Sciences, Vascular Surgery, Uppsala University, Uppsala, Sweden

^bDepartment of Surgical and Peri-operative Sciences, Surgery, Umeå University, Umeå, Sweden

^cDepartment of Surgical Sciences, Cardiothoracic Surgery, Uppsala University, Uppsala, Sweden

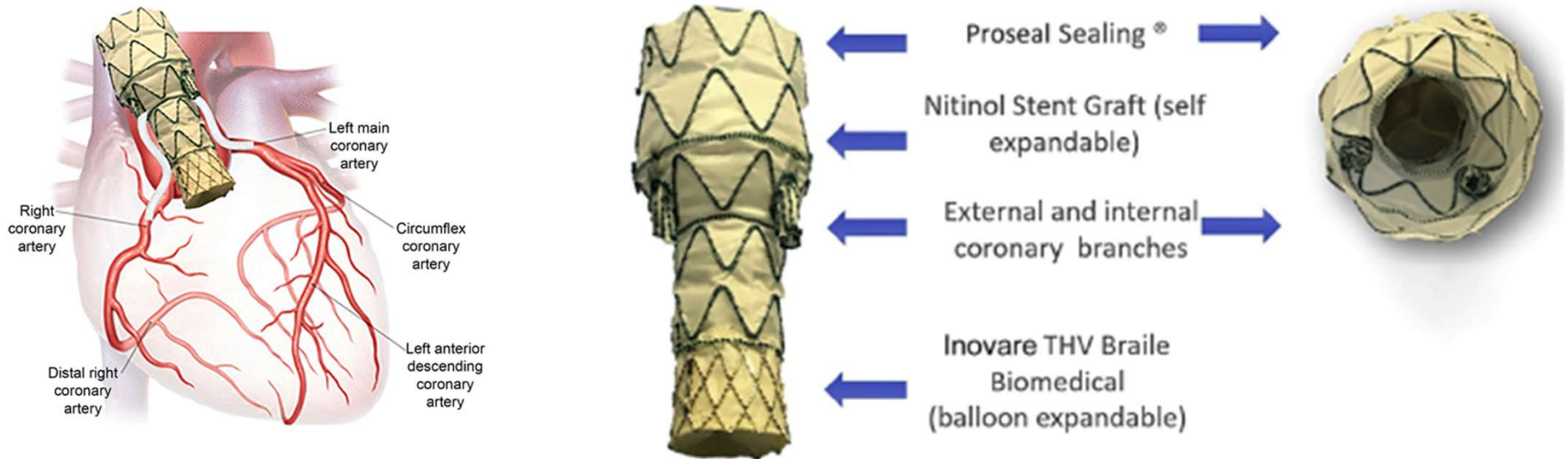
^dDepartment of Medical Sciences, Cardiology, Uppsala University, Uppsala, Sweden

- Anatomic suitability commercially available stent grafts TAAD 4-21%, 40% primary entry tear TAAD at aortic root or within 1 cm STJ
- Anatomic related requirements: annulus 18-29mm, height coronary ostia > 10mm, distal ao LZ < 40mm
- Balloon exp: shorter frame, precise, radial force, lower PVL
- Self exp: repositioning, hemodynamics, lower annular injury
- 5 reported cases
- Indications:
 - Aortic dissection: 2
 - Post surgical complications: 2
 - Aneurysm: 1

Endo-Bentall Review

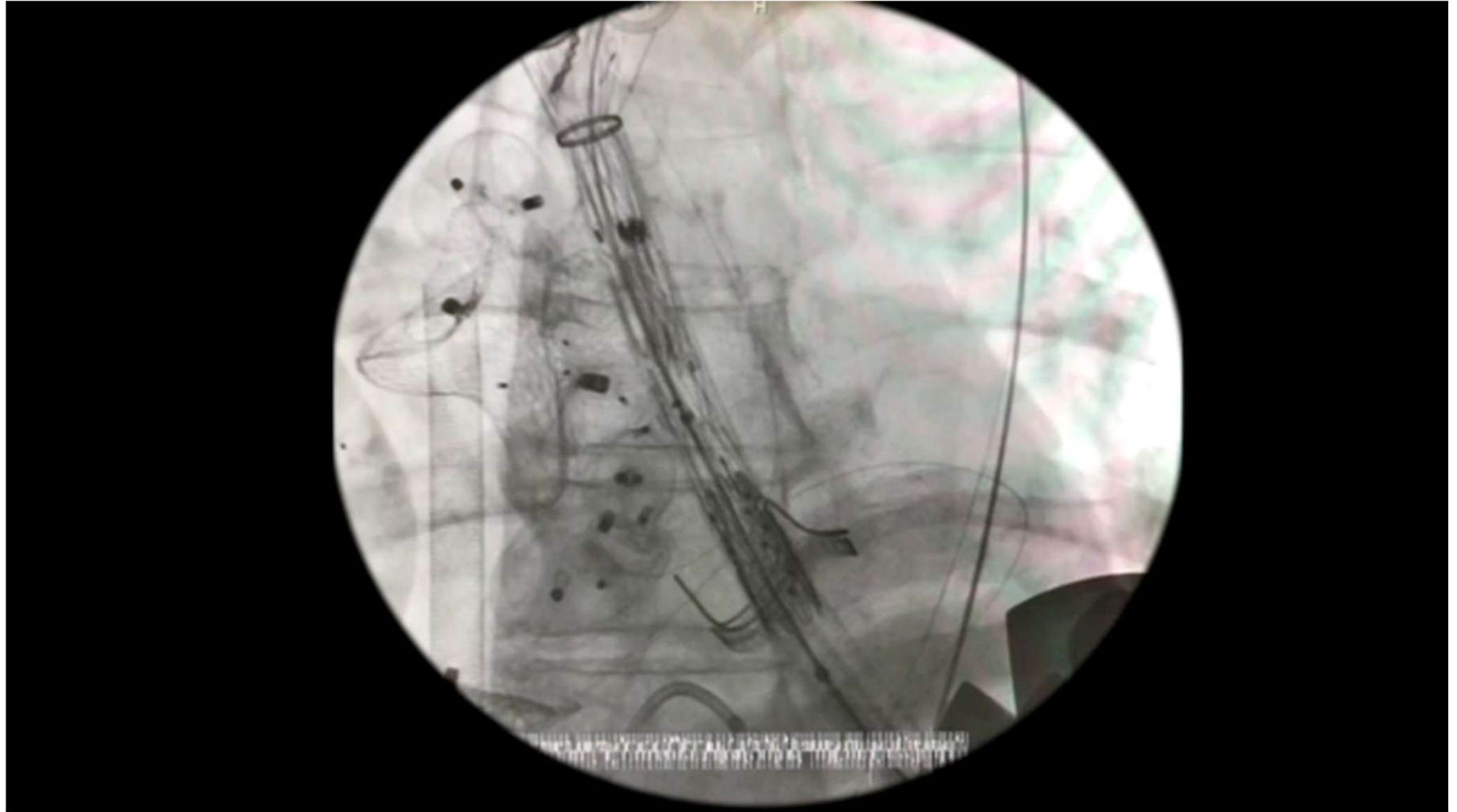
- Balloon expandable TAVR platforms 3 (1 single stage, 2 two stage), self expanding 2 (single stage)
- ECMO/CPB 3 cases
- Access TF 2, trans-apical 2, 1 LCCA/Rt axillary approach
- Coronary stent 3/5 cases
- Technical success 100%, 1 non-aortic death 5 months

Endo-Bentall Prosthesis

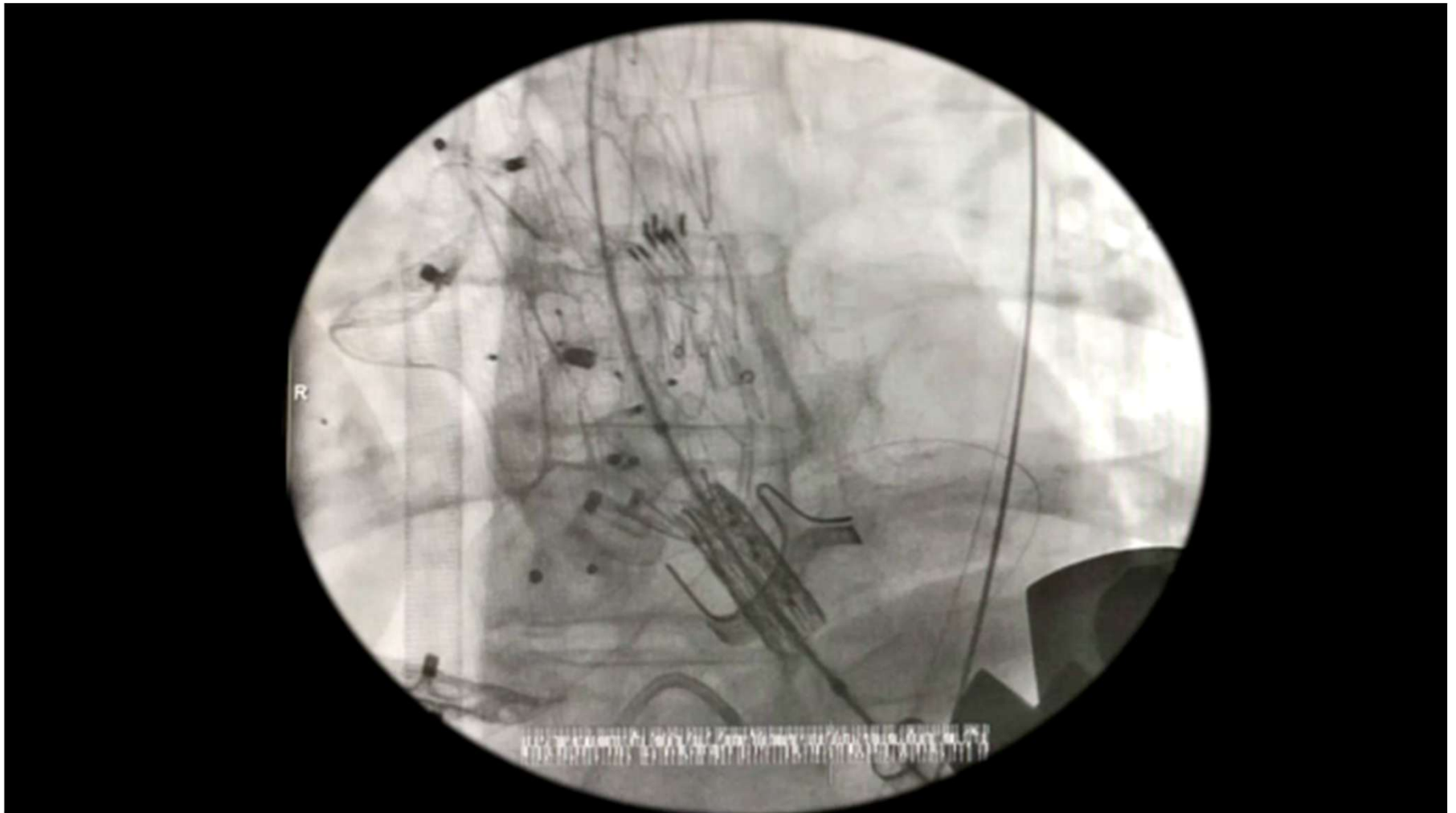


- Pt with PSA defect 6 mm below STJ near non-coronary sinus
- Custom made device, Balloon expandable TAVR valve (22 mm Braile Inovare) attached to self-expandable 40 mm diameter aortic stent with coronary artery branches 2 cm from ostia after aortic stent deployment
- Following deployment of endoprosthesis via trans-apical approach, coronary arteries were treated with bridging covered stents with ECMO support

Endo-prosthesis Deployment

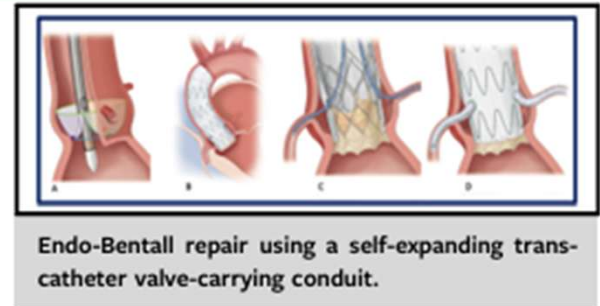


TAVR Valve-in-Valve



Endo-Bentall repair: Early results and feasibility of a physician-constructed Endo-Bentall device

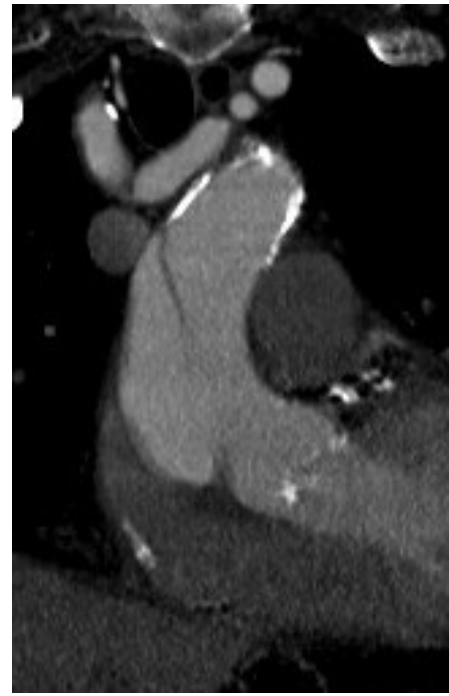
Mehrdad Ghoreishi, MD,^a Aakash Shah, MD,^b Diljon Chahal, MD,^c Jeanwan Kang, MD,^d Anuj Gupta, MD,^c Bradly S. Taylor, MD,^b and Shahab Toursavadkahi, MD^d



- Self expanding TAVR valve sutured into physician modified TEVAR with coronary fenestrations made on back table, device resheathed and delivered via TF access, rapid V pacing
- Device deployed with coronary alignment; if persistent endoleak post deployment coronary ostia stented with covered stents
- 5 cases 2022-2023 prohibitive risk, mean age 79, 4 ATAAD, 1 root aneurysm,
- 100% technical success, no CPB support, 0% hospital mortality or CVA, 3/5 required coronary stenting, 2 required concomitant endo-arch repair
- Median follow up CT at 172 days, no type 1a endoleak

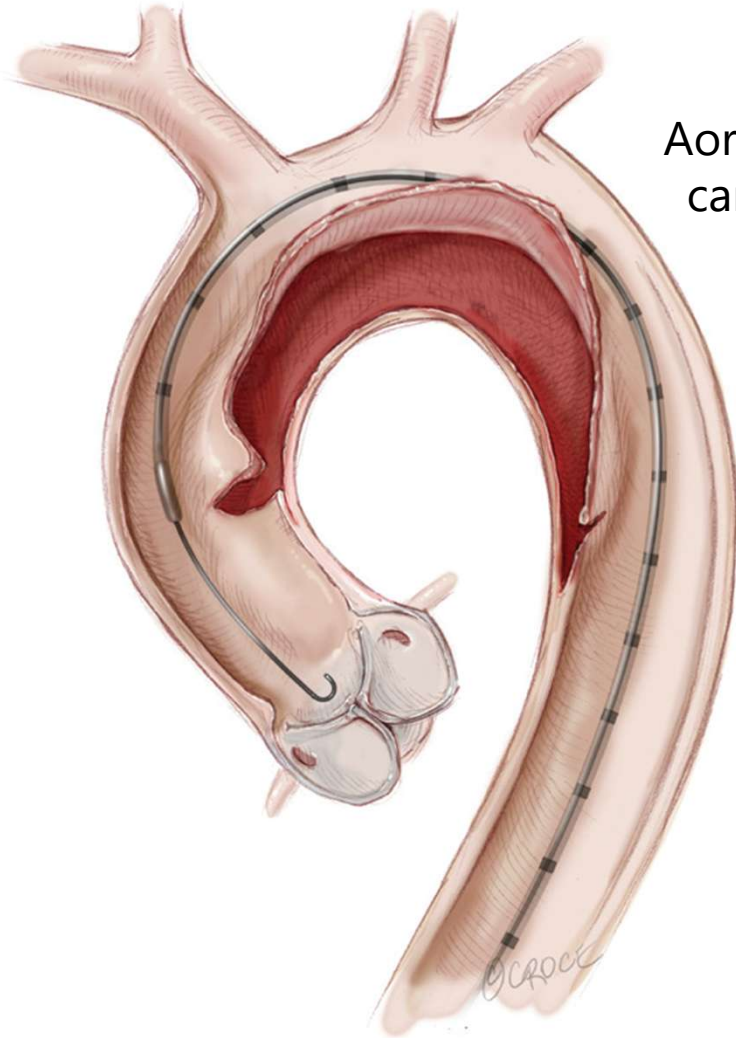
Endovascular Ascending Repair

- Technically feasible
- Rapidly evolving technology
- Tailor the therapy to the patient risk profile, anatomy, expertise, and available technology
- Pt selection critical
- Significant opportunities for innovation
 - Conformable, tapered elastic devices
 - Steerable, repositionable system
 - TAVR-TEVAR valve-conduit devices with coronary branches for aortic root pathology



Endovascular Technique

- Trans-femoral approach

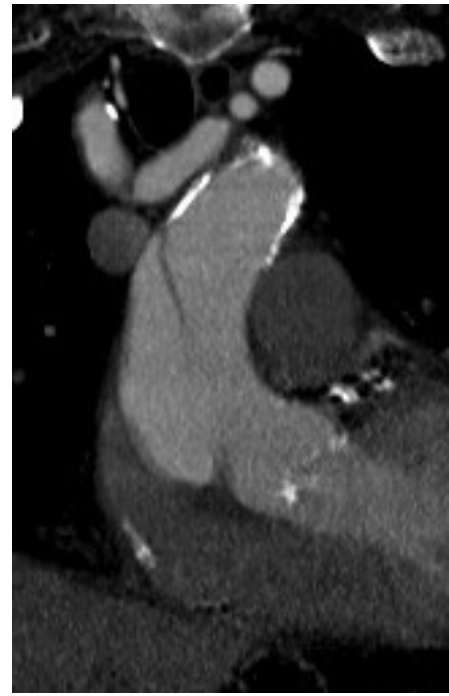


Aortic arch manipulation with guidewires and stent grafts can cause extension of dissection or neuro-embolization

Multi-disciplinary approach:
Cardiac Surgery
Vascular Surgery
Interventional Cardiology
Cardiac Anesthesia
Cardiac Perfusion
Neurology




Endovascular Ascending Repair

- Technically feasible
- Rapidly evolving technology
- Tailor the therapy to the patient risk profile, anatomy, expertise, and available technology
- Highly skilled multi-disciplinary team
- Significant opportunities for innovation
 - Conformable, tapered elastic devices
 - Steerable, repositionable system
 - TAVR-TEVAR valve-conduit devices with coronary branches for aortic root pathology



GORE® Ascending Stent Graft

Deployment to Intermediate Diameter

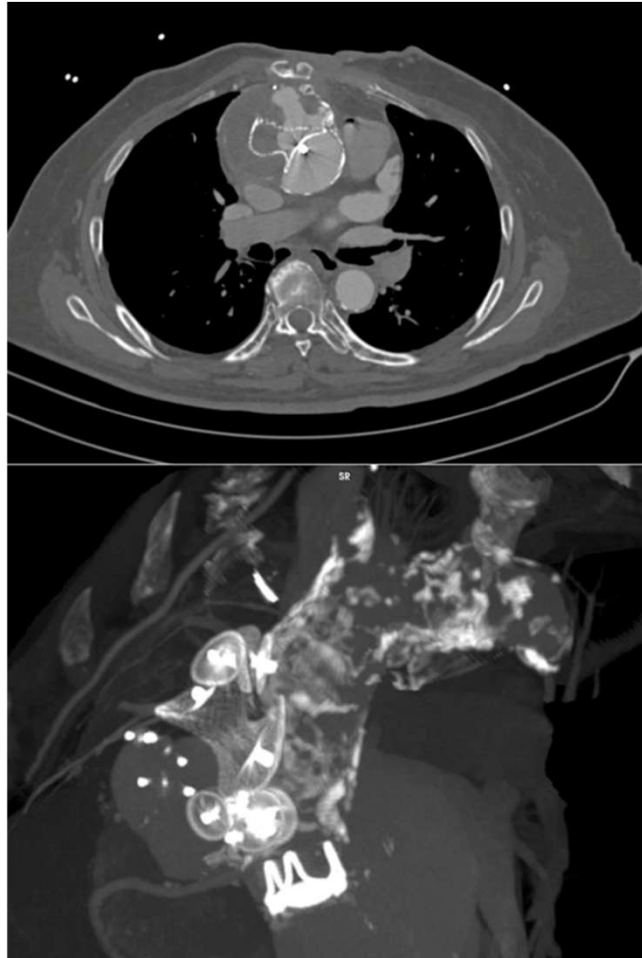


The GORE® ASG is initially deployed to 50% diameter, at which point blood is flowing through and around the device. Positioning adjustments can be made at this stage

GORE Investigational Device


Proximal angulation control
Available diameter 31-45 mm, length 7 - 10 cm

First In-Human Endo-Bentall

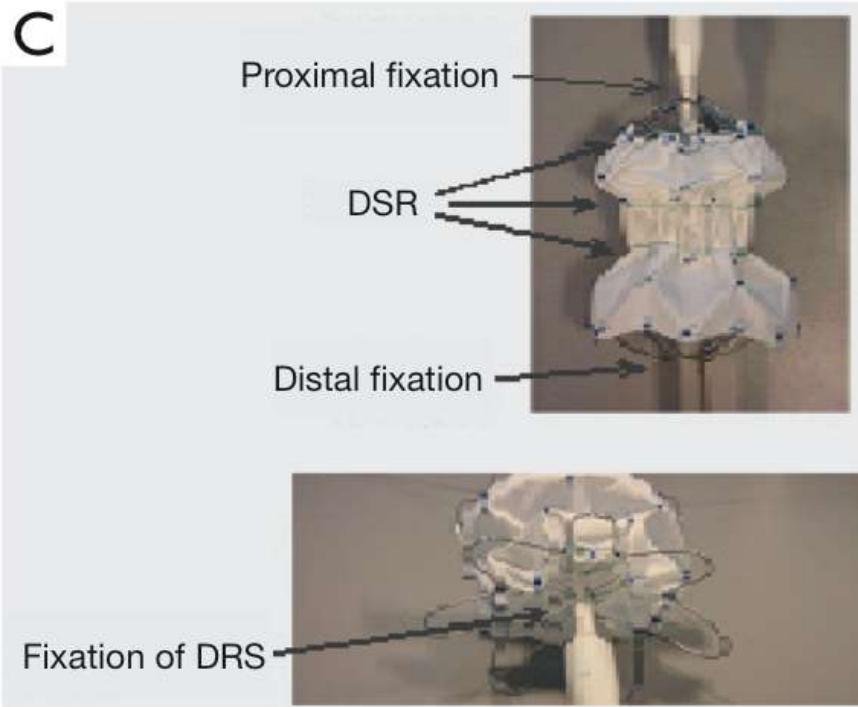



64 yo female post AVR in 2014 with 23 mm Pericardial valve with PSA at aortic suture line and fistula to skin, unsuccessful percutaneous closure w 7 vascular occluders, with porcelain aorta, AVR degeneration MG 28.5; EuroSCORE 28.5%

Cook Ascend

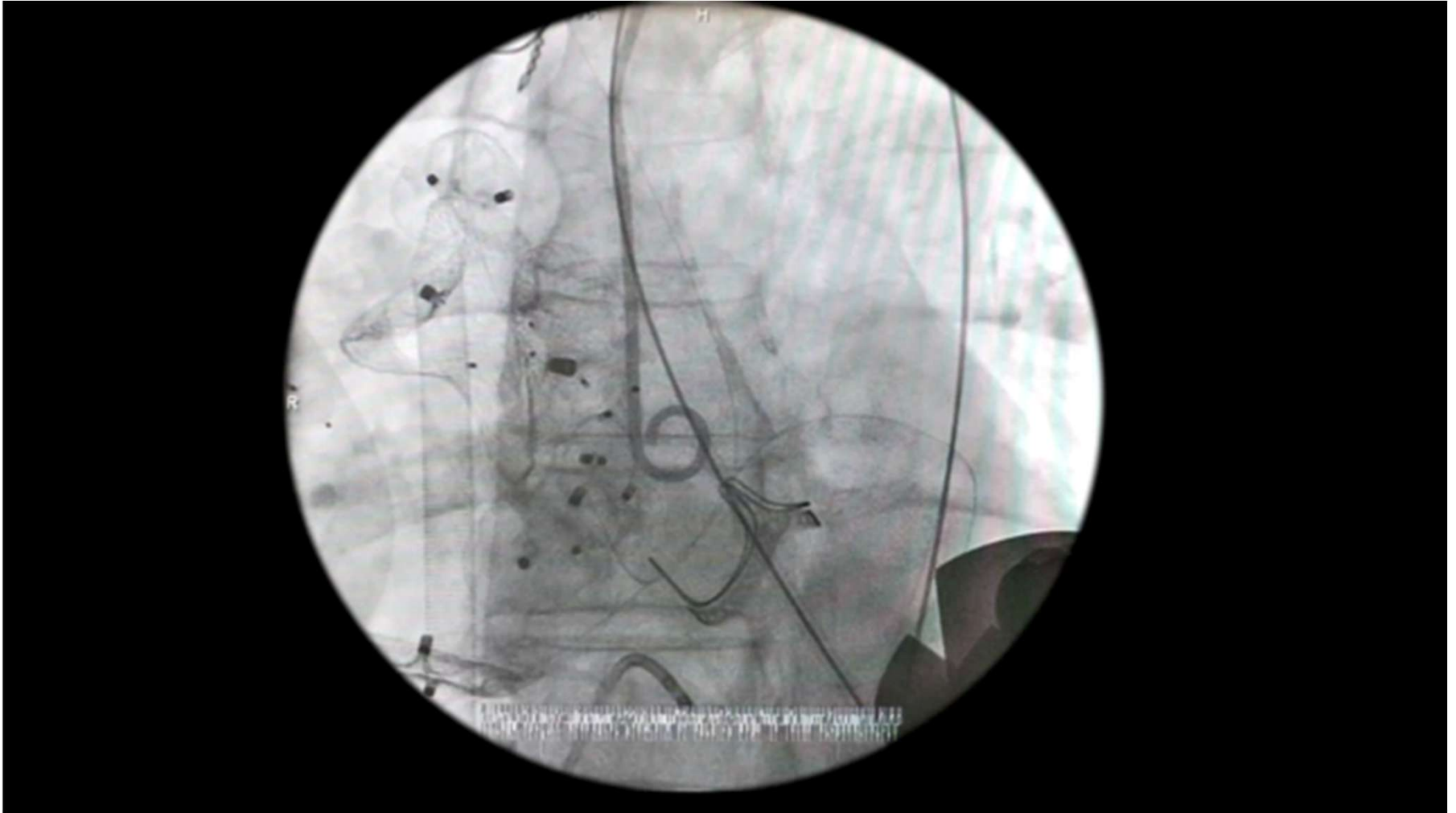


B Deployment sequence

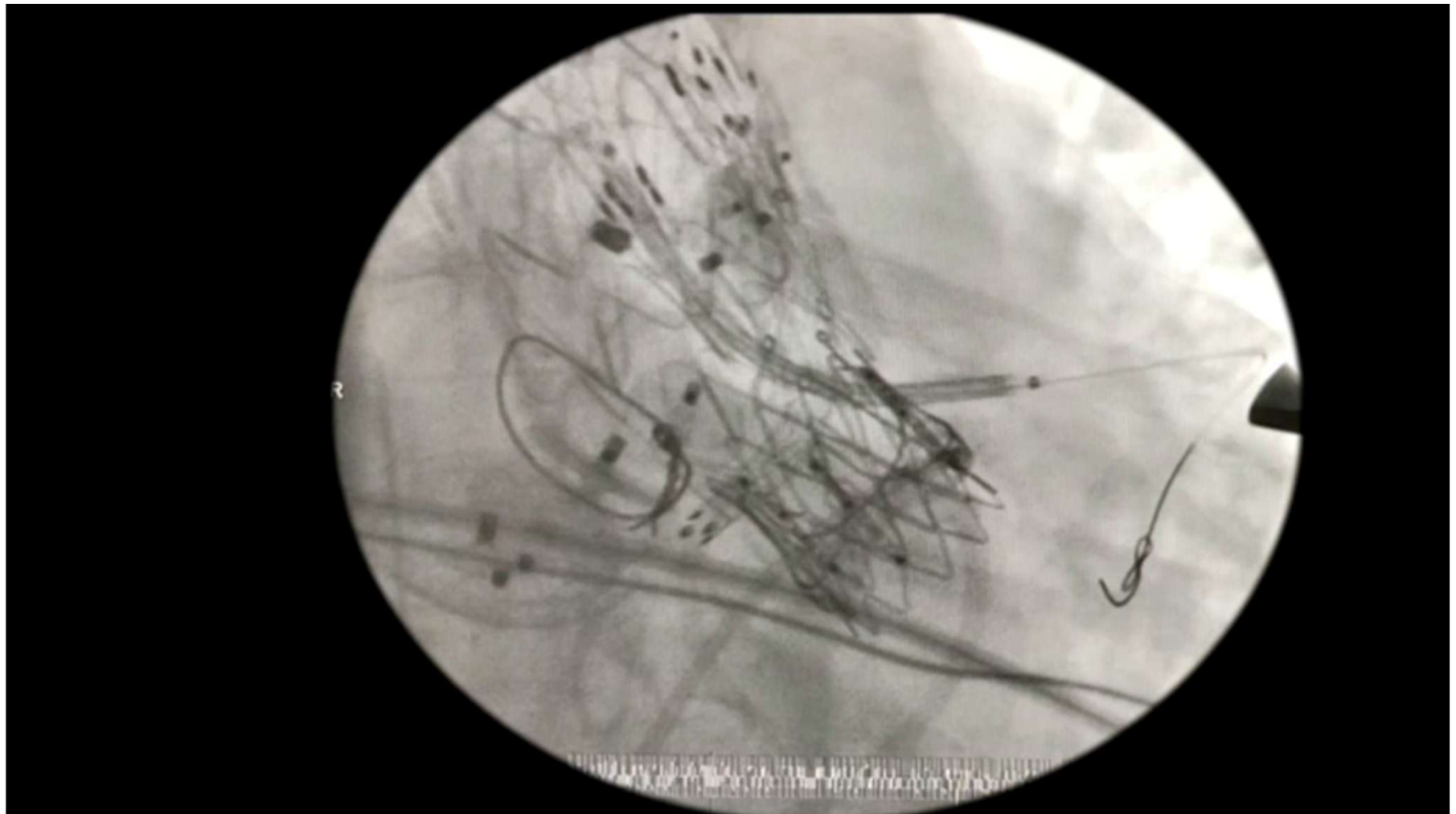


Proximal and distal bare stents to aid
Fixation and conformability

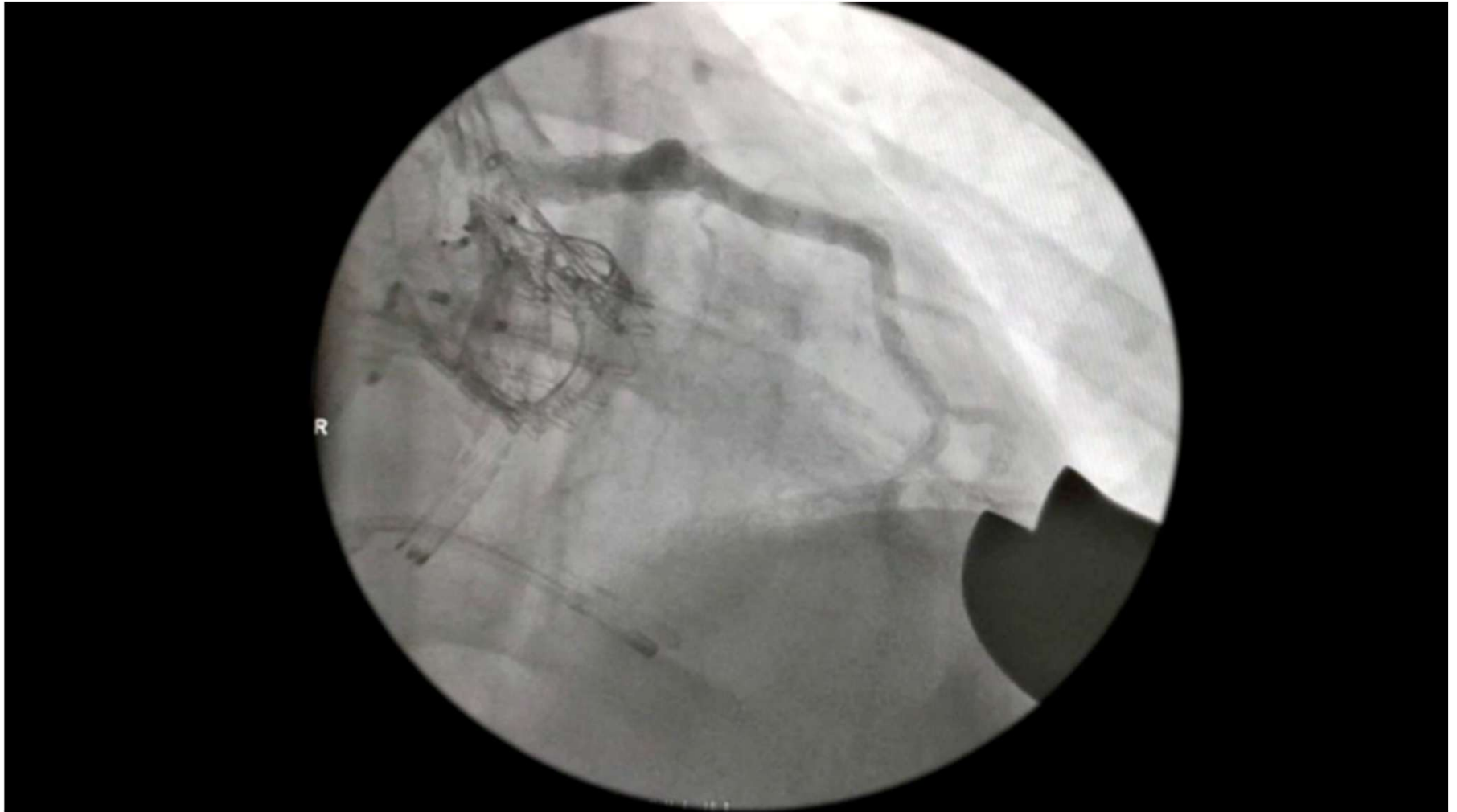
Pre-Intervention



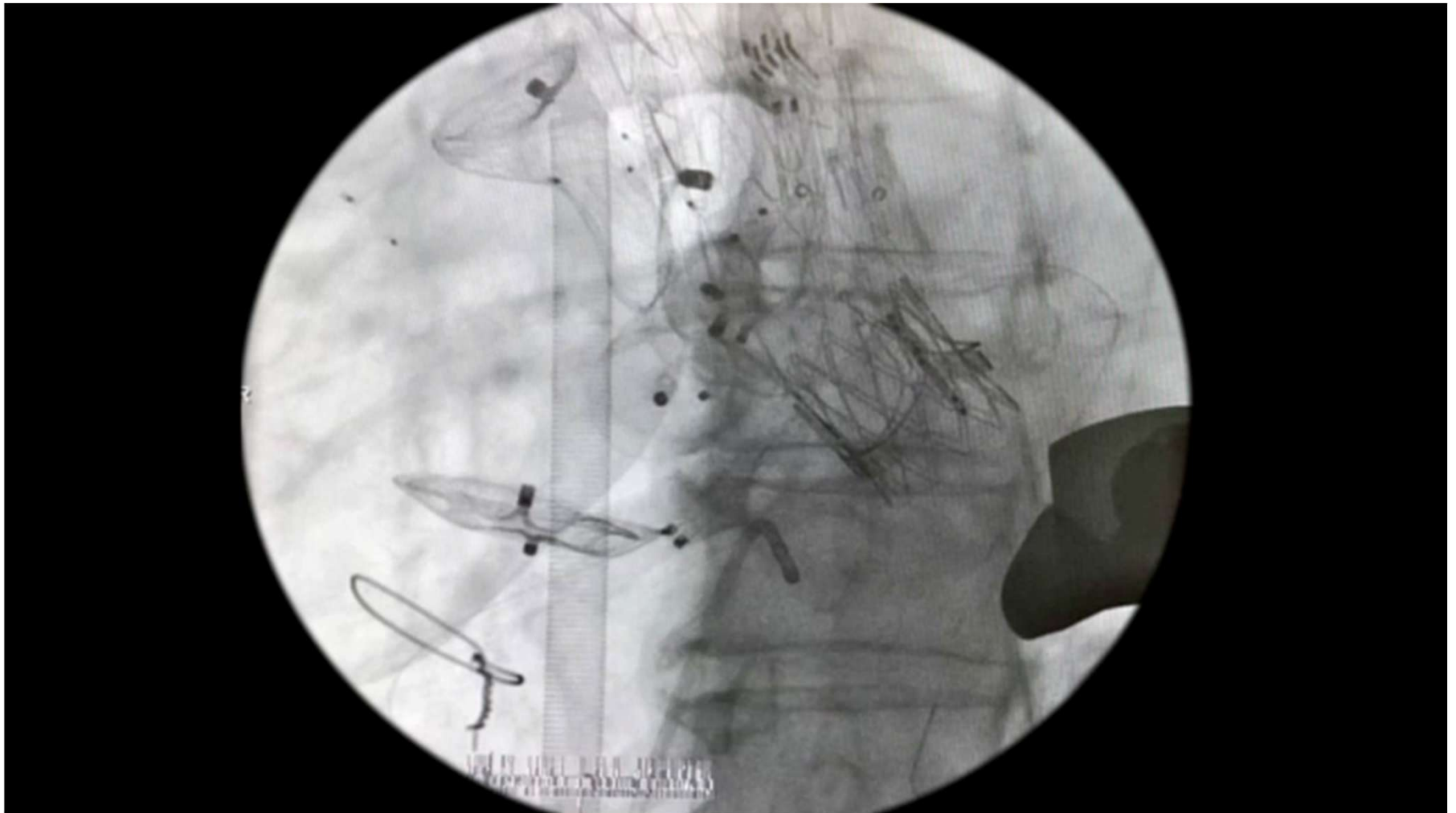
L Main stent



LCA angiogram



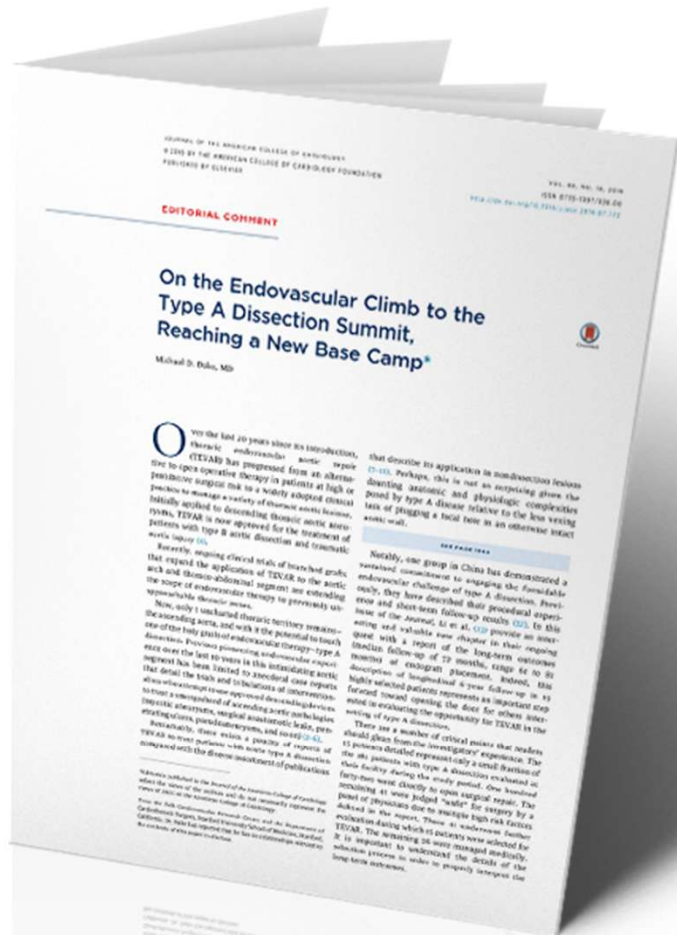
RCA stent angiogram



Total procedure time 390 minutes, discharge POD 7 without complications

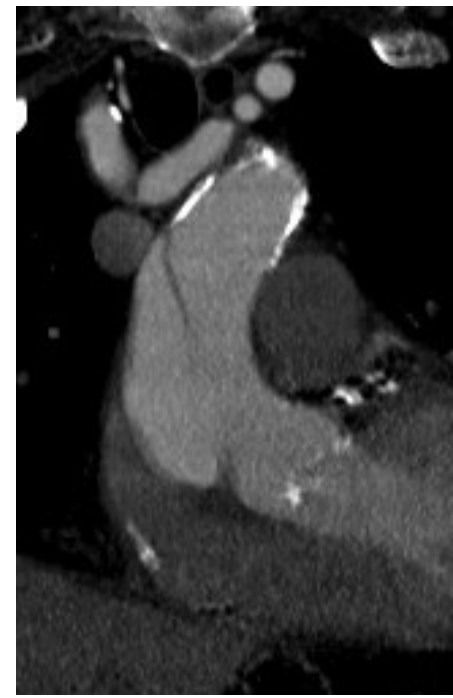
On the Endovascular Climb to the Type A Dissection Summit, Reaching a New Base Camp

- ...beyond the novelty level of “look, it can be done” to the next developmental stage, poised on the threshold of a prospective clinical trial.



Endovascular Ascending Repair

- Technically feasible
- Rapidly evolving technology
- Tailor the therapy to the patient risk profile, anatomy, expertise, and available technology
- Highly skilled multi-disciplinary team
- Significant opportunities for innovation
 - Conformable, tapered elastic devices
 - Steerable, repositionable system
 - TAVR-TEVAR valve-conduit devices with coronary branches for aortic root pathology

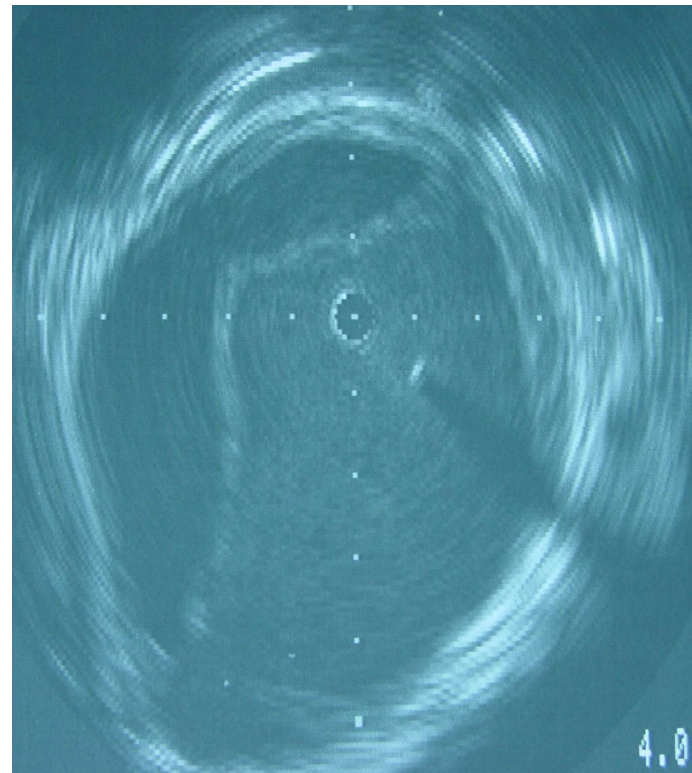
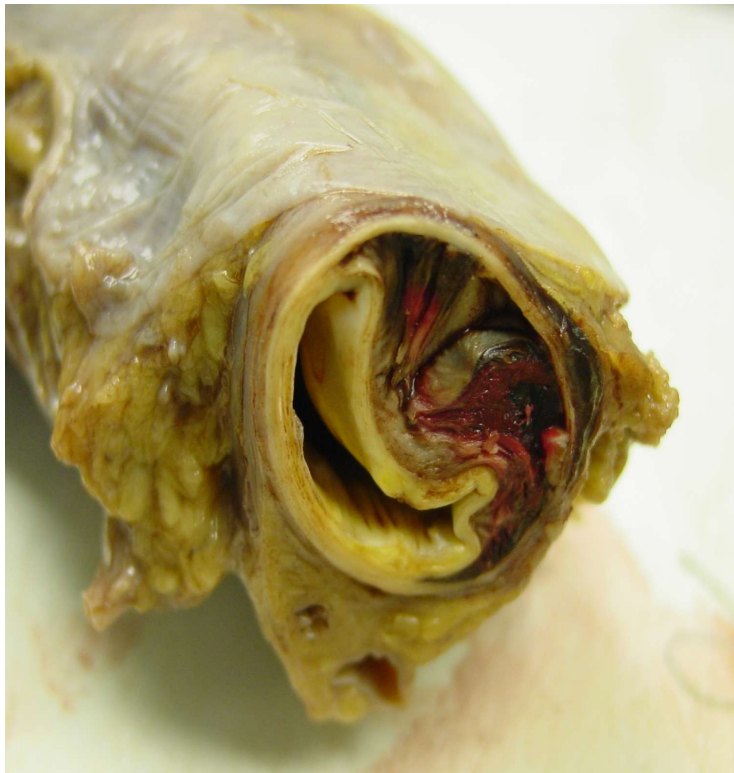

Thank You



Background

- 50000 pts die annually from diseases of aorta and its branches in the US.
- AA are 13th leading cause of mortality
- Acute aortic syndrome



Ascending Aortic Pathologies

Aneurysm

- Fusiform
- Saccular

Dissection

- Acute vs. Chronic
- Uncomp vs. Comp

Acute Aortic Syndromes

- IMH
- PAU

Pseudoaneurysm

Genetic/Connective

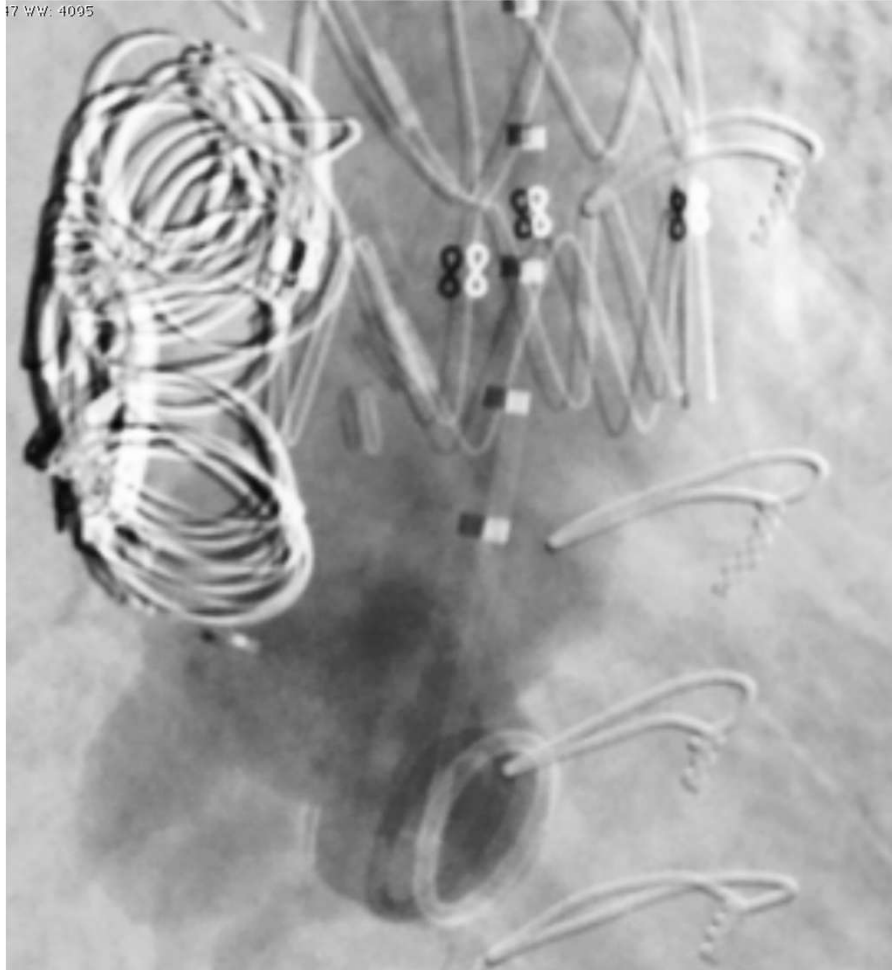- Marfans
- Ehlers/Danlos
- Loeyes-Dietz
- Familial

Infectious/Mycotic

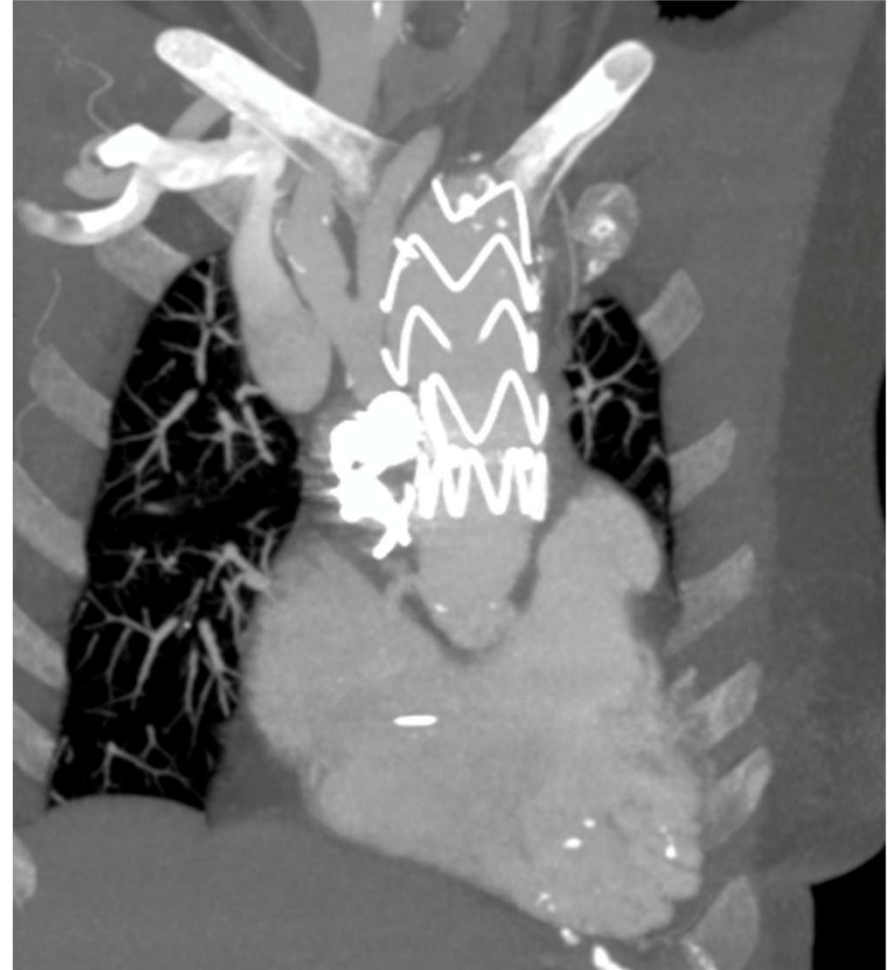Traumatic

- Acute
- Chronic

Pseudoaneurysm Embolization

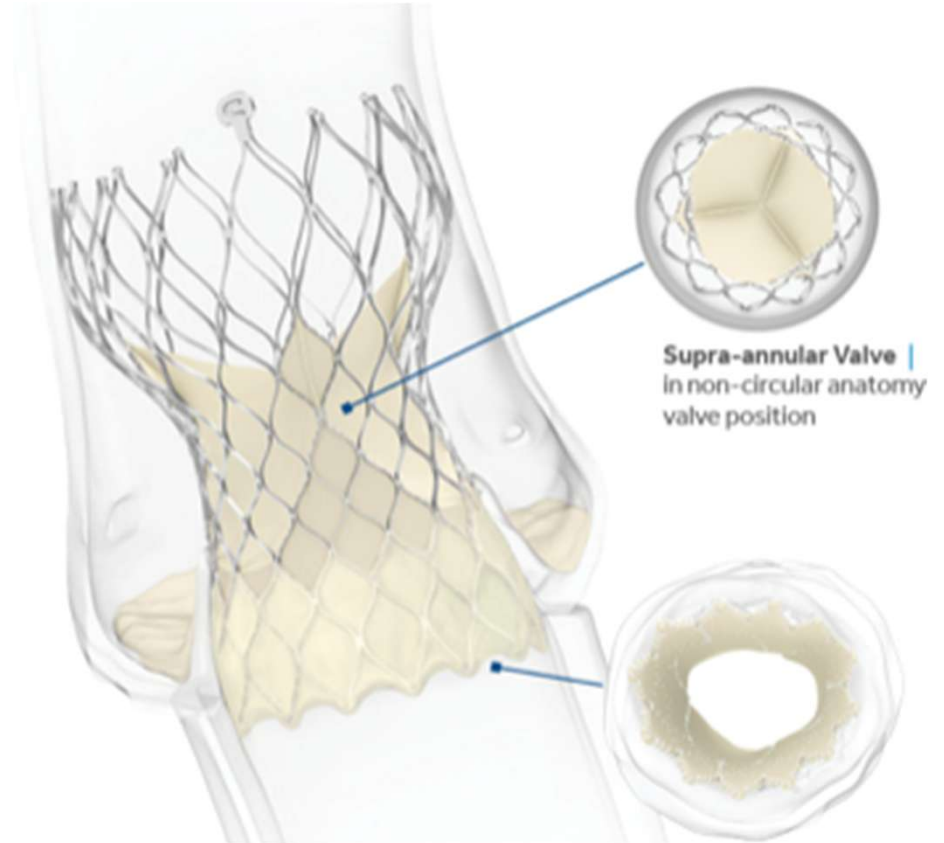
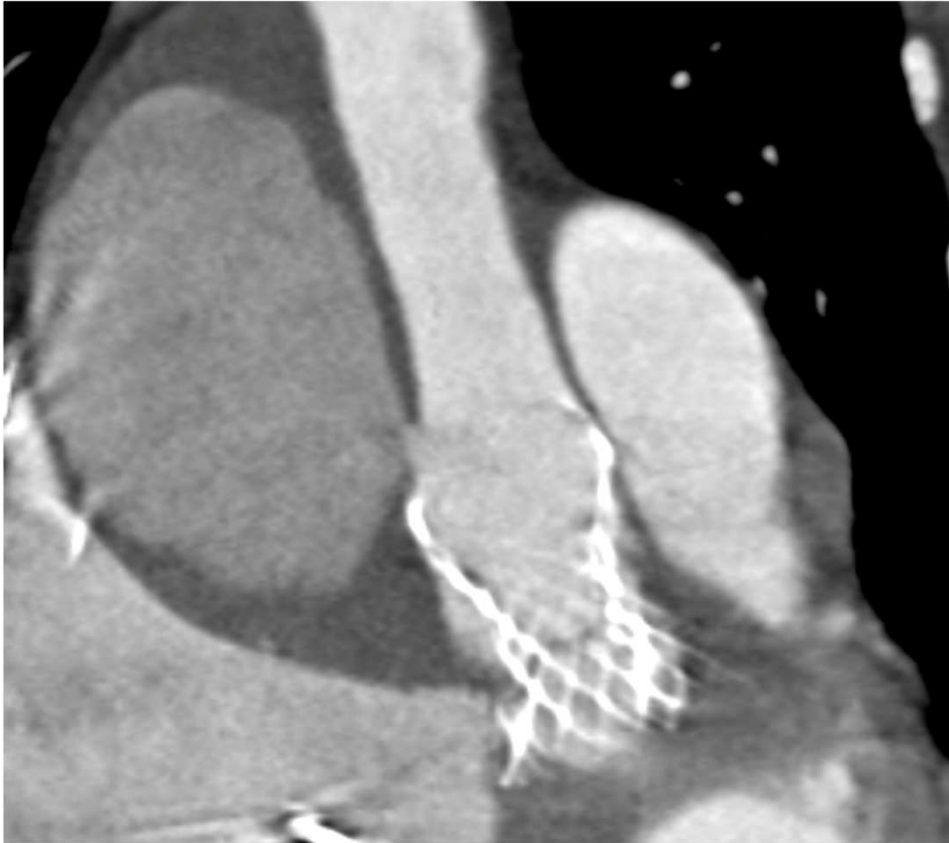

Successful coil embolization and vascular plug



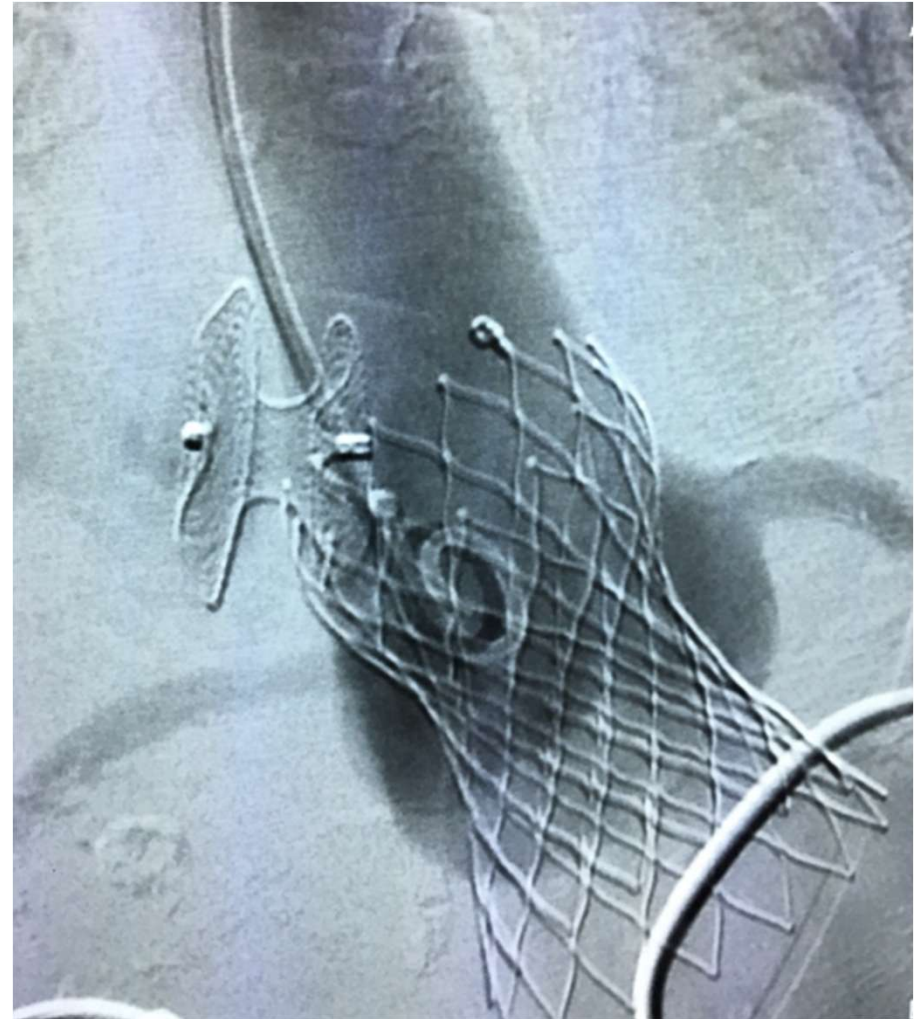
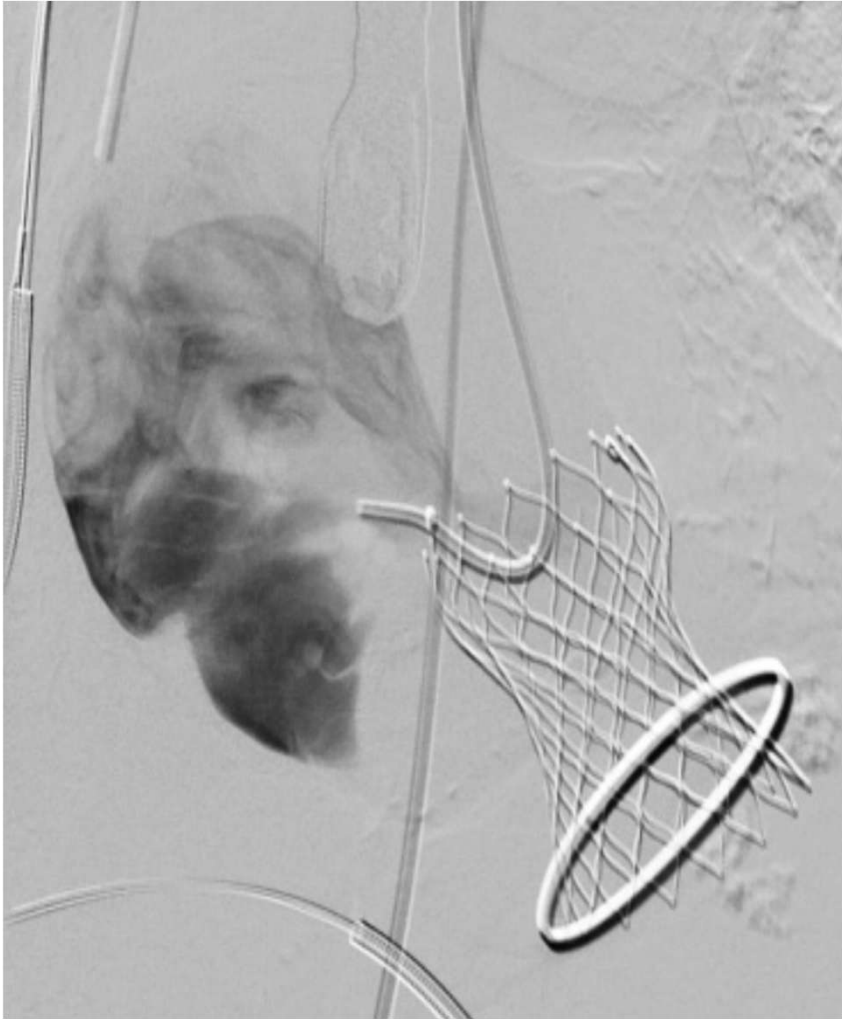CTA 2 months post

Ascending PSA post TAVR



75 yo female post MV repair 2006, TAVR 6/17, EF 25% presented with PSA 5 mo post

Ascending PSA Plug

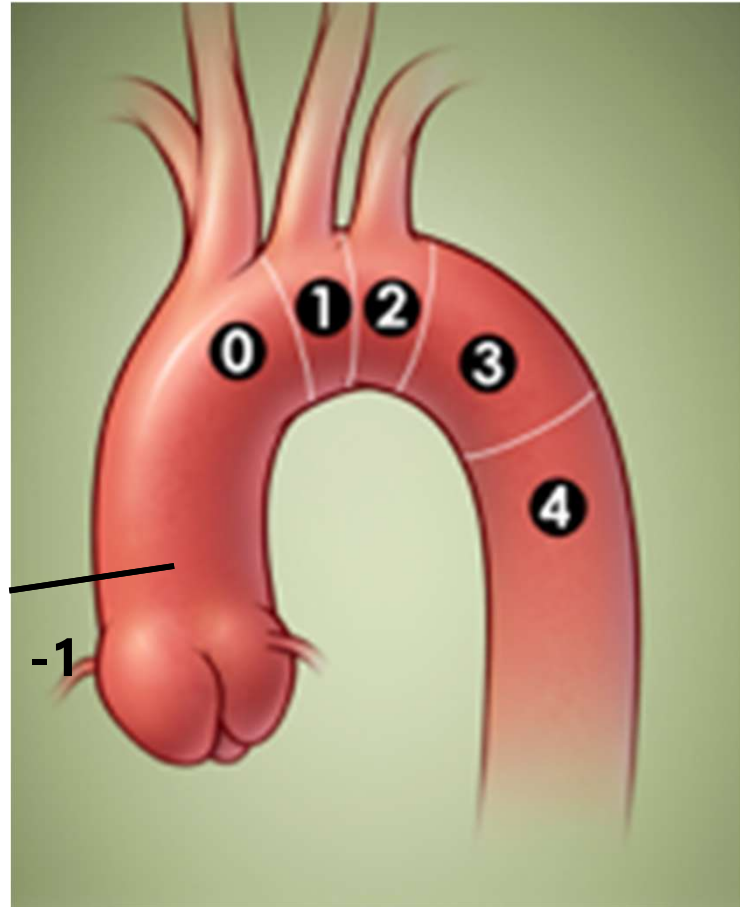


11/17: PSA closure with 13 mm Amplatzer Septal Occluder device

11/19 : TTE no flow in PSA, aortic root stable 38mm, EF 30-35%, no AI or AS



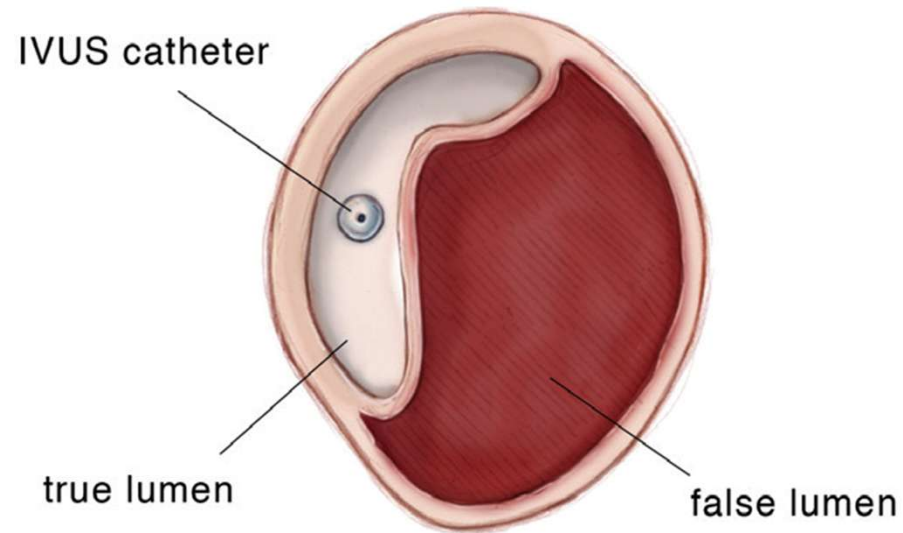
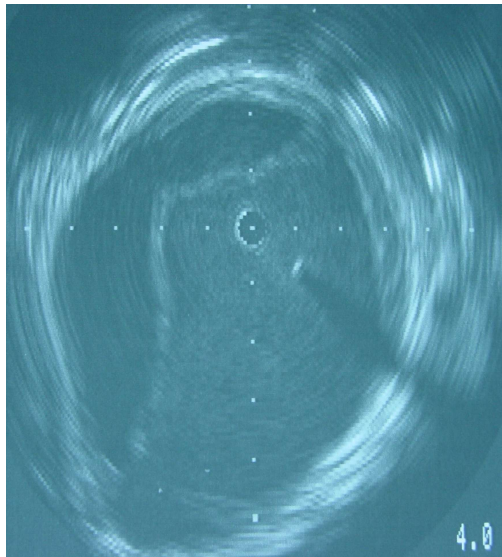
Endovascular Zones of Aorta



Zone 0: Ascending aorta from STJ to Innominate artery
“Zone -1”: Aortic root below STJ

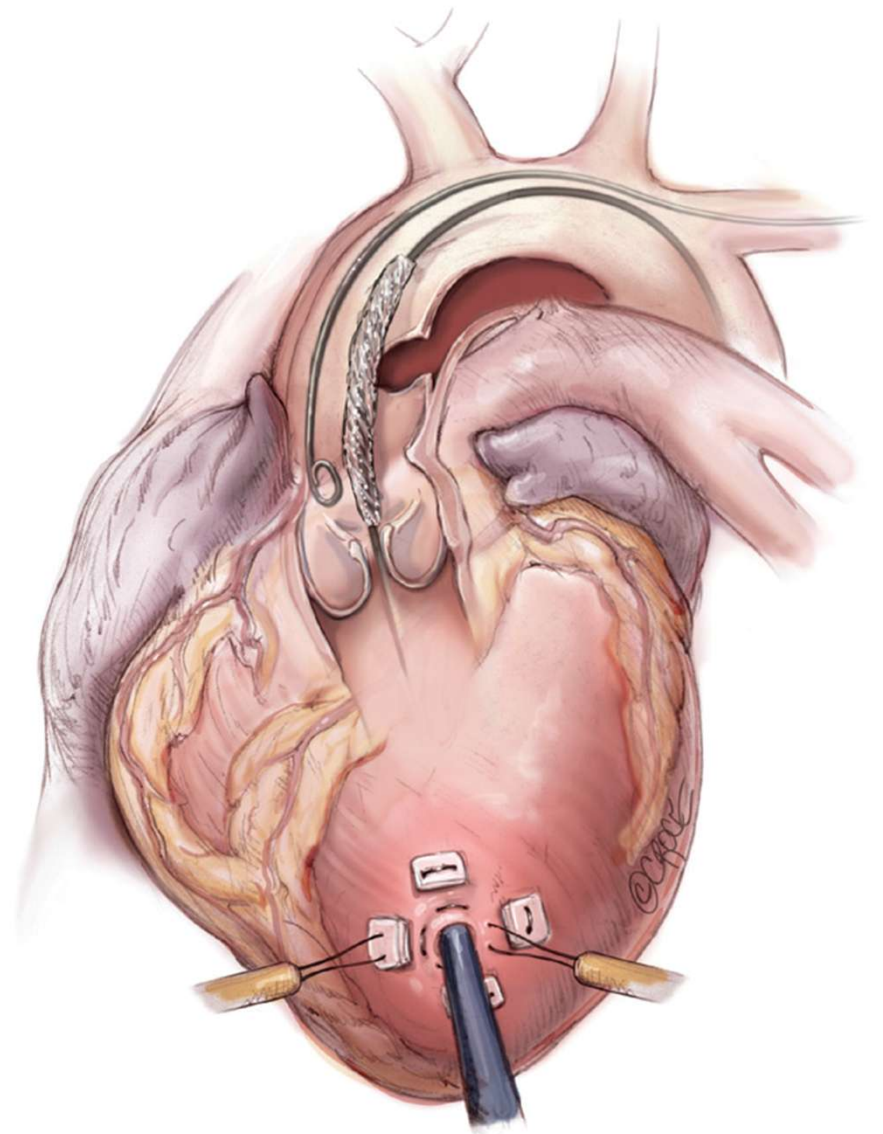
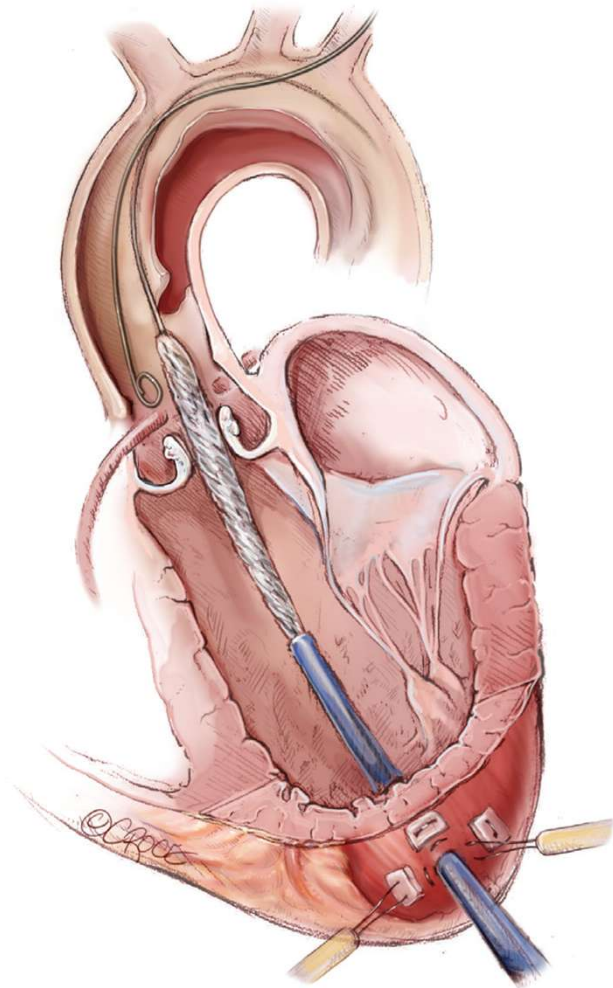
Ascending TEVAR: Equipment

- IVUS, TCD, MEP/SSEP
- Cerebral oximetry



Endovascular Technique

Trans-apical approach



From the Society for Vascular Surgery

A systematic review of primary endovascular repair of the ascending aorta



Corbin E. Muetterties, MD,^a Rohan Menon, BS,^b and Grayson H. Wheatley III, MD,^c Philadelphia, Pa; Washington, D.C.; and Nashville, Tenn

- 118 patients treated from Jan 1995 to Jan 2017
- Indications:
 - Type A dissection 50%
 - Aortic Pseudoaneurysm 29.7%
 - Aortic aneurysm 5.1%
 - PAU 4.2%
 - Aortic rupture 2.5%
- Access:
 - Femoral 62.7%
 - Trans-apical 14.4%
 - Carotid 12.7%
 - Axillary 6.8%

Aortic Disease treated by Device type

Device category	No. of patients (%)	Aortic dissection	Pseudoaneurysm	PAU	IMH	Aortic aneurysm	Aortic rupture	Other
Thoracic stent	84 (71.2)	42	20	5	3	6	2	6
Custom-made stent	12 (10.2)	8	3	0	0	0	1	0
Abdominal cuff	13 (11)	2	10	0	0	0	0	1
Unknown stent	8 (6.8)	7	1	0	0	0	0	0
Thoracic cuff	1 (0.9)	0	1	0	0	0	0	0
Total	N = 118	59 (50%)	35 (29.7%)	5 (4.2%)	3 (2.5%)	6 (5.1%)	3 (2.5%)	7 (5.9%)

IMH, Intramural hematoma; PAU, penetrating atherosclerotic ulcer.

Complications

	No. (%)
Endoleaks	22 (18.6)
Reintervention	11 (9.3)
Nonaortic deaths	12 (10.2)
Aortic deaths	6 (5)
Open conversion	4 (3.4)
Stent migration	2 (1.7)
Postoperative myocardial infarction	4 (3.4)
Stroke	4 (3.4)
Device deployment failure	3 (2.5)
Other	11 (9.3)
Free of complications	71 (60.2)
Free of aorta-related complications	79 (67)

Results:

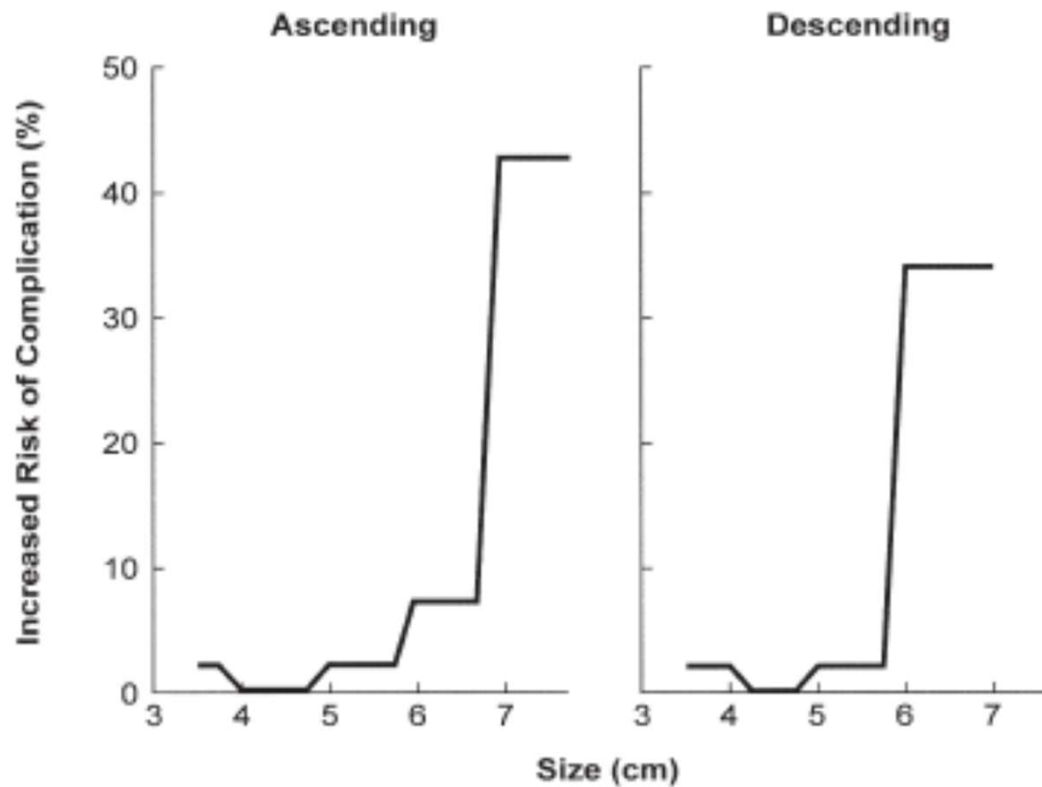
Aorta-related mortality 5%, all-cause mortality 15.2%,

Open conversion 3.4%, CVA 3.4%

Type 1 endoleak 18.6%, Reintervention 9.3%

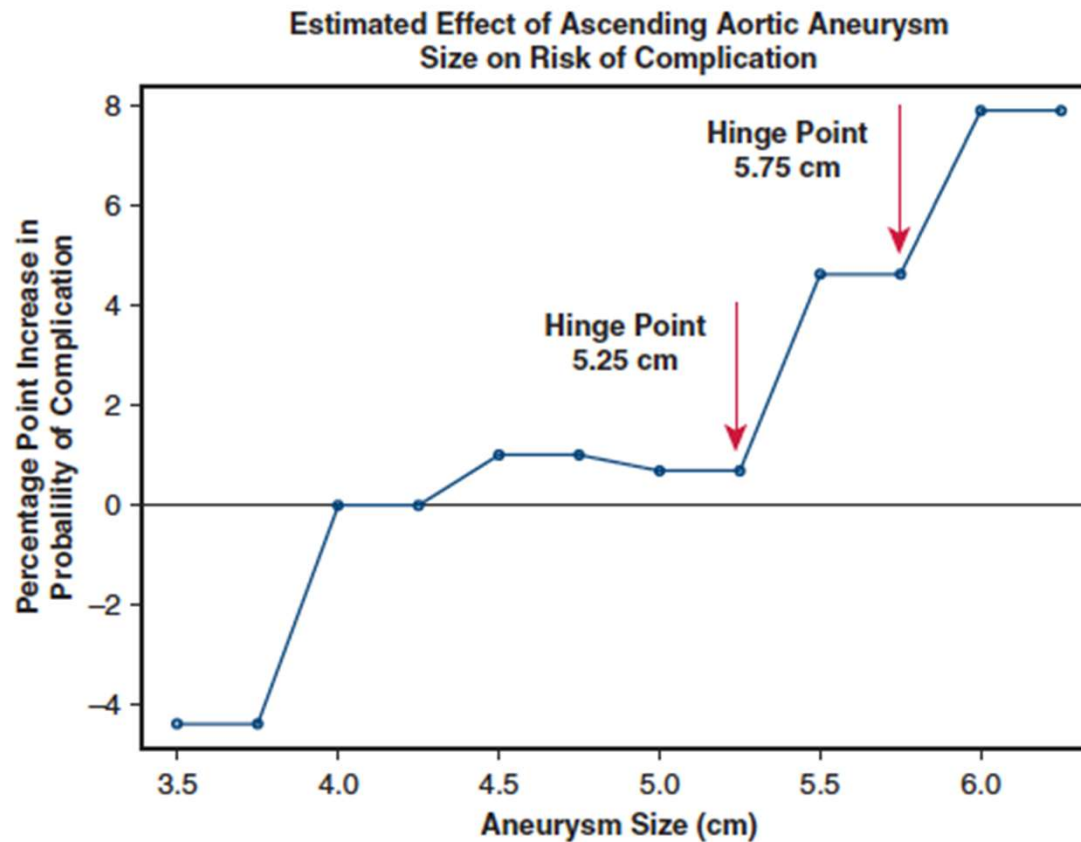
Mean follow up 17.2 months

Hinge Points Thoracic Aortic Aneurysms



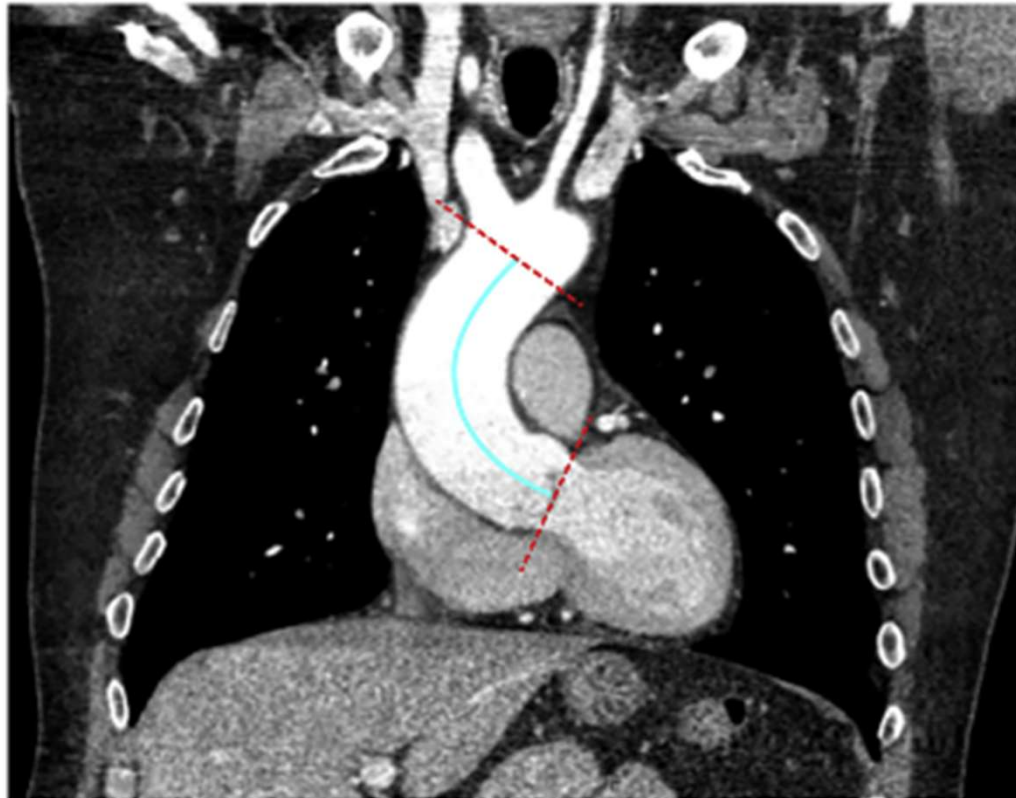Coady MA, et al. J Thorac Cardiovasc Surg 1997;113:476

Hinge Points Ascending Aortic Complications



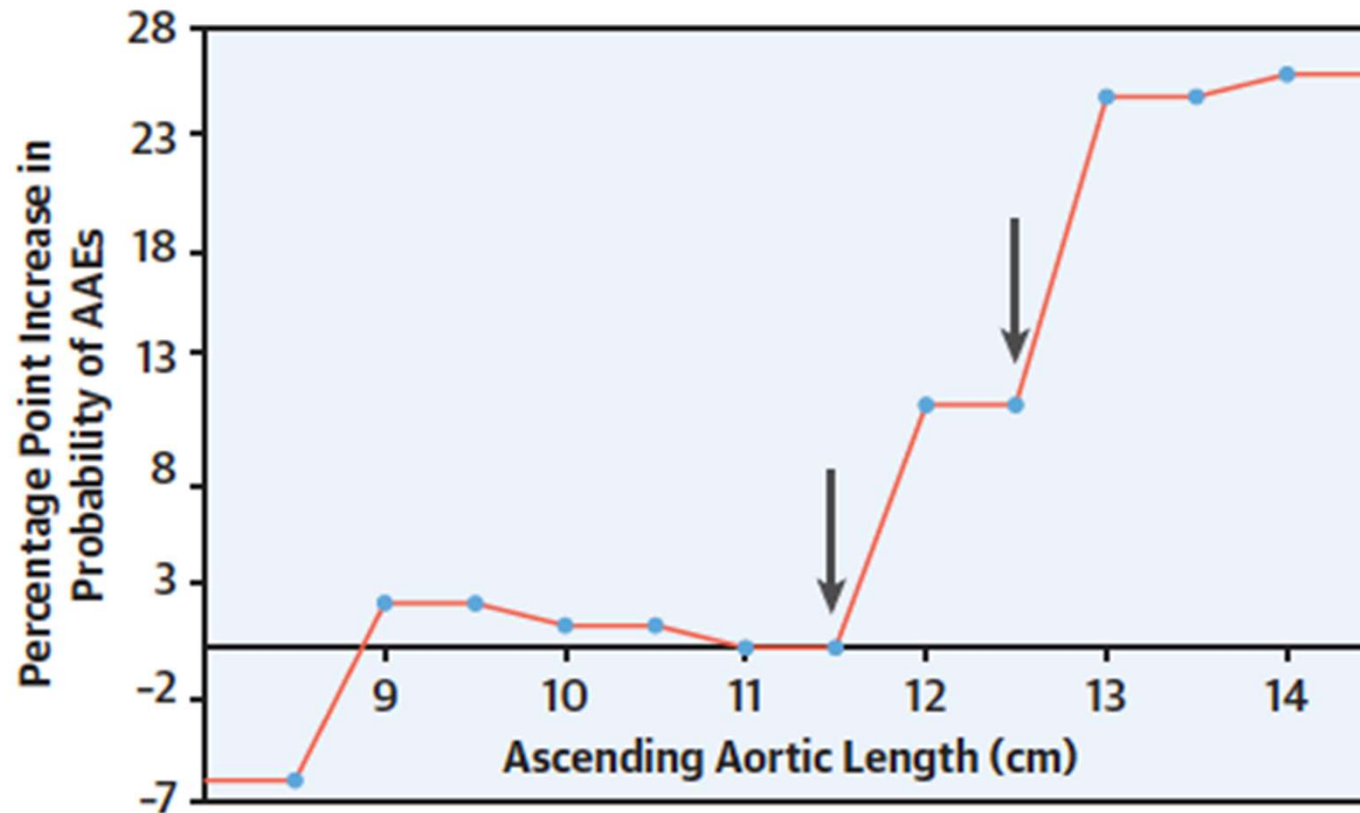
Elefteriades; J Thorac Cardiovasc Surg 2019;157:37

Ascending Aorta Length Dimensions and Adverse Events



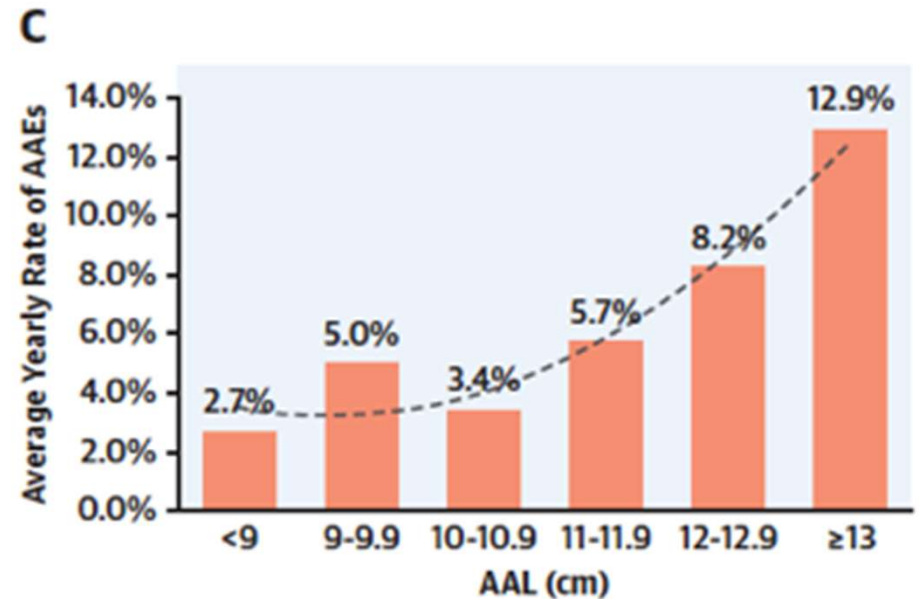
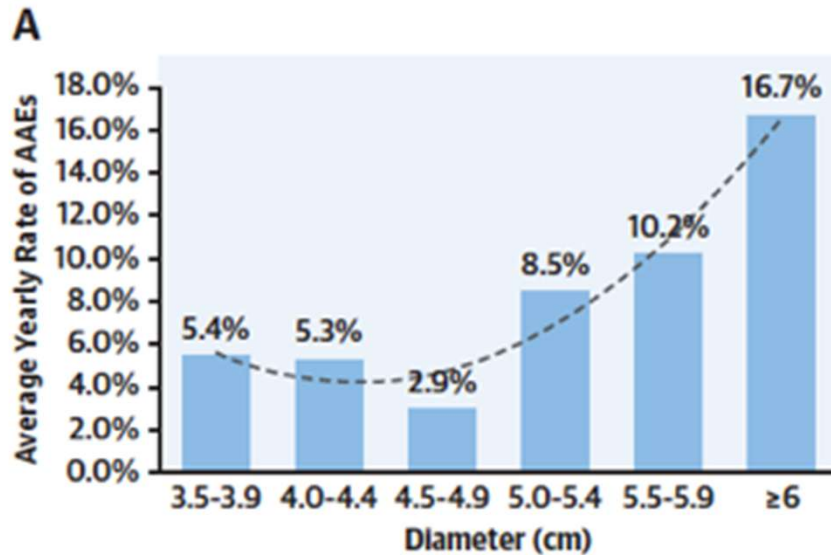
Ascending aortic length is measured as distance (**blue**) from the aortic annulus (**red**) to the origin of innominate artery (**red**).

Hinge points Aortic Adverse Events



Hinge points with large increase of AAE : 11.5 – 12.0 cm, and 12.5 – 13.0 cm
Intervention threshold for ascending aortal length at 11.0 cm

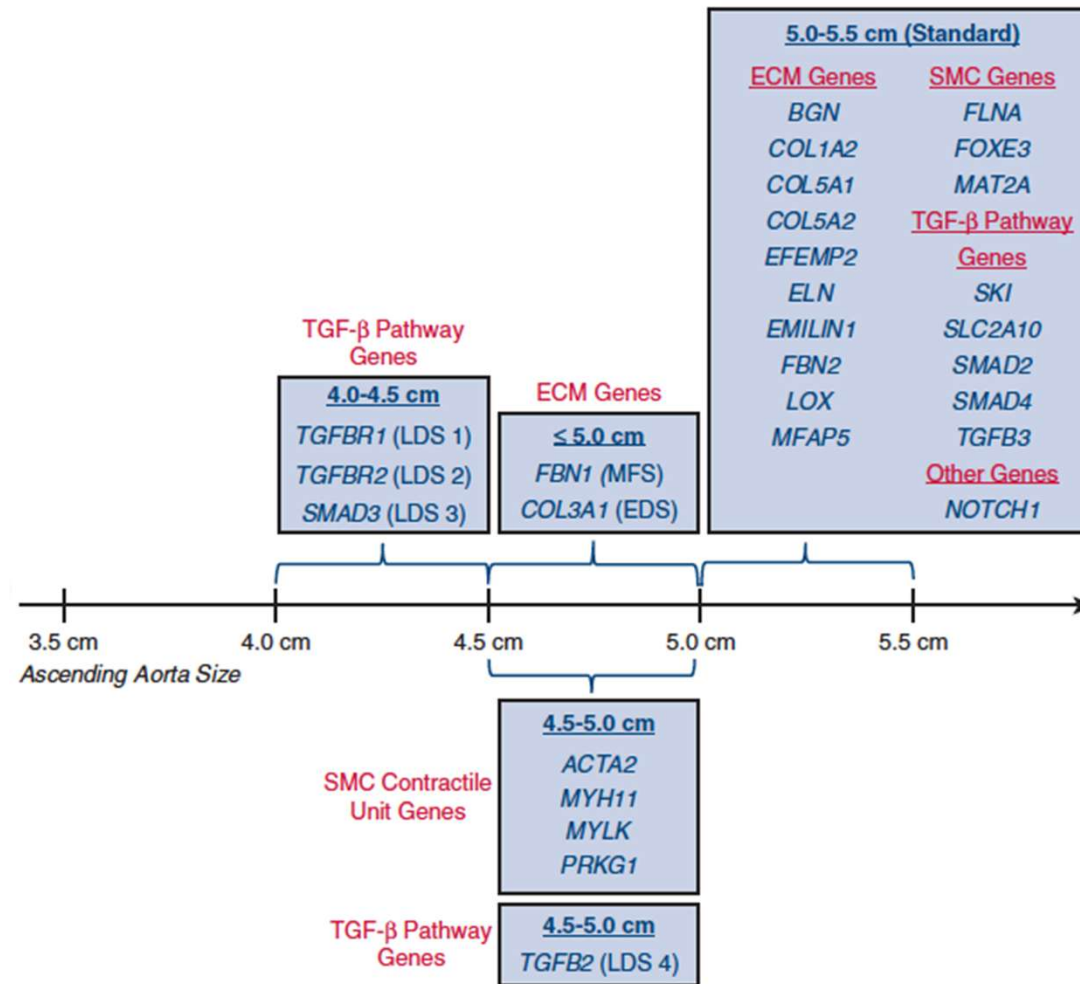
Yearly rates Aortic adverse events



Diameter > 5.5 cm had > 3-fold annual rate of adverse events

AAL > 13 cm was associated with nearly 5-fold higher annual rate of adverse events than length < 9 cm

Intervention by Gene Category



Thoracic Aortic Aneurysms and Dissections are familial in 20%

Recommendations for Surgery

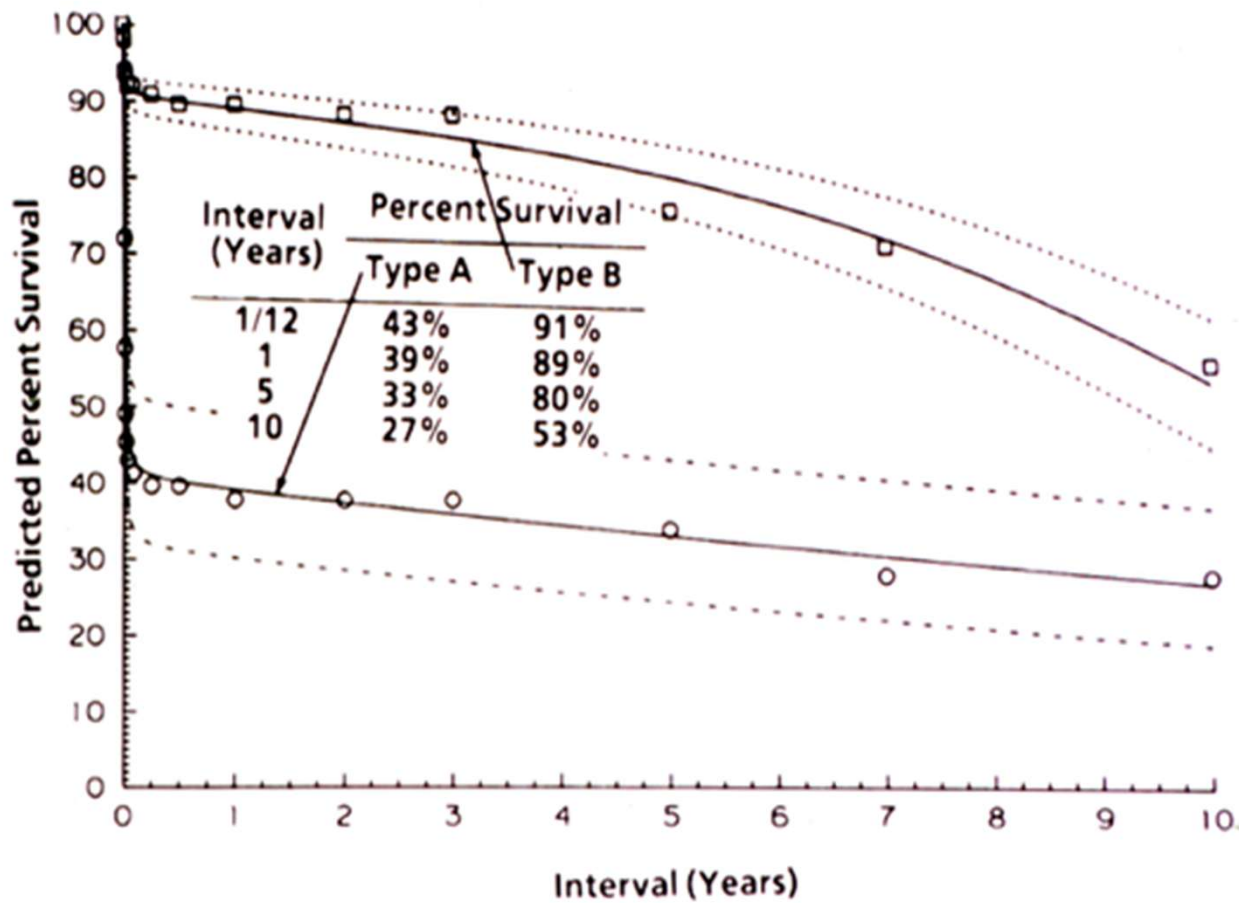
- Ascending aorta
 - Asymptomatic > diameter 5.5 cm or Ratio of Area $\text{cm}^2/\text{height (m)} > 10$
 - Bicuspid aortic valve 5.5 cm or 5 cm if high risk features (root phenotype, AI, family history aortic dissection, growth > 3 mm/yr)
 - Connective tissue disorder (CTD) 4.0-5.0 cm
 - Growth rate > 0.5 cm/yr
 - Concomitant Cardiac Surgery 4.5 cm
- Descending aorta
 - Chronic dissection, CTD, DTAA 5.5 cm
 - TAAA > 6.0 cm

Type A Dissection

- IRAD Registry: 67% of all dissections Type A
- Incidence 2-3.5 per 100,000 people/yr
- From 1996 to 2013, pts undergoing surgery increased from 79% to 90%
- Surgical Mortality decreased from 25% to 18%
- 60% hospital mortality for pts unfit for surgery

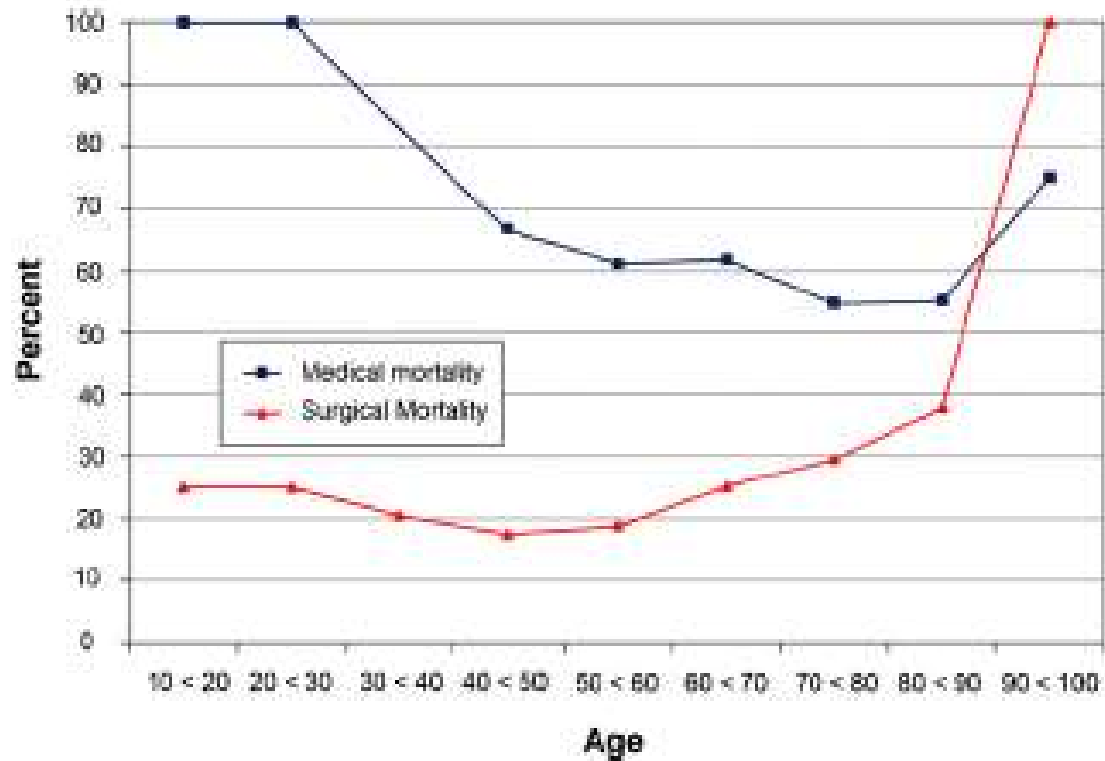
JACC 2015;66:350-8

Survival for non-operated ATAAD

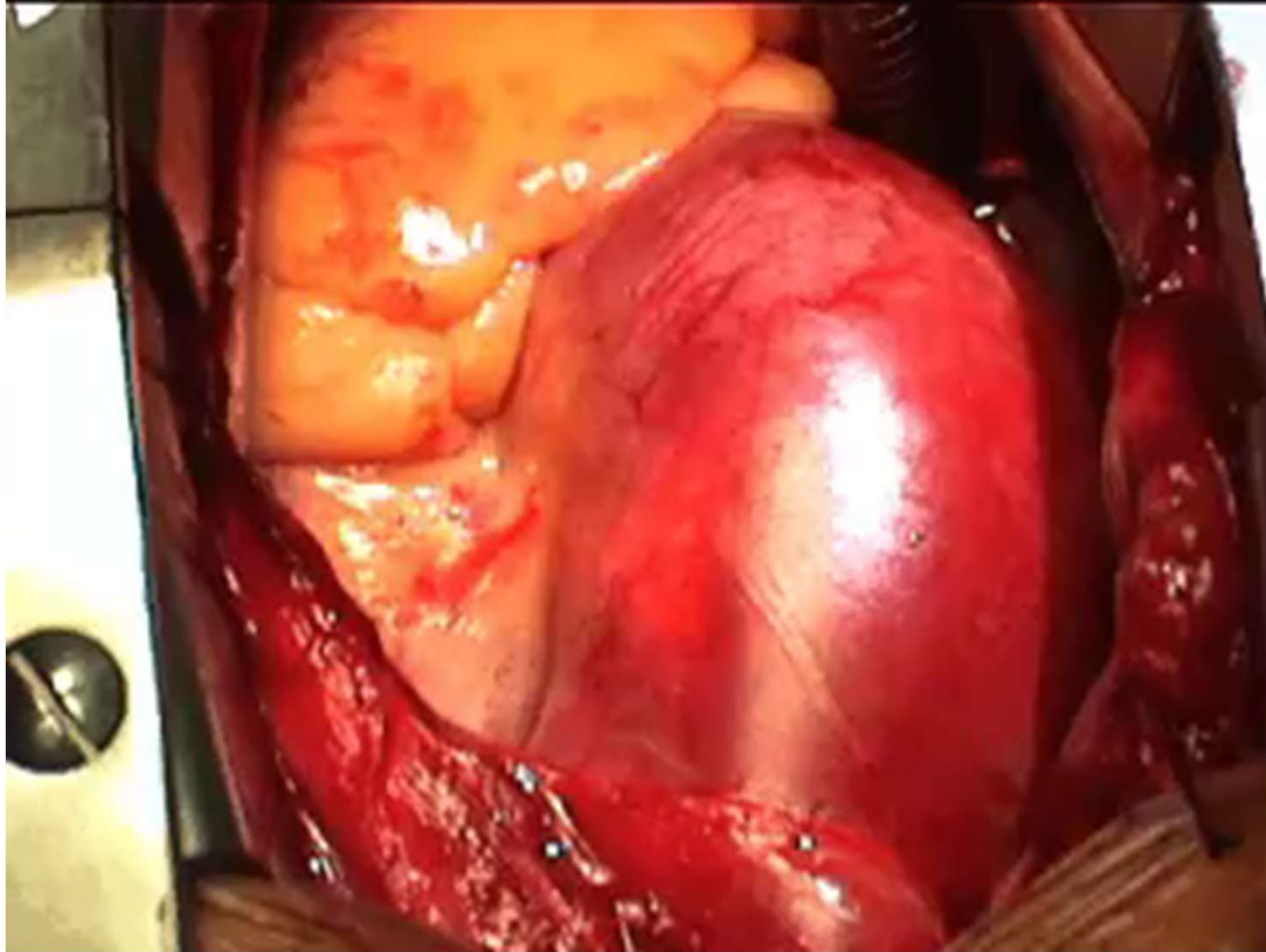


Masuda.Circ 1991:84(suppl11):111-7

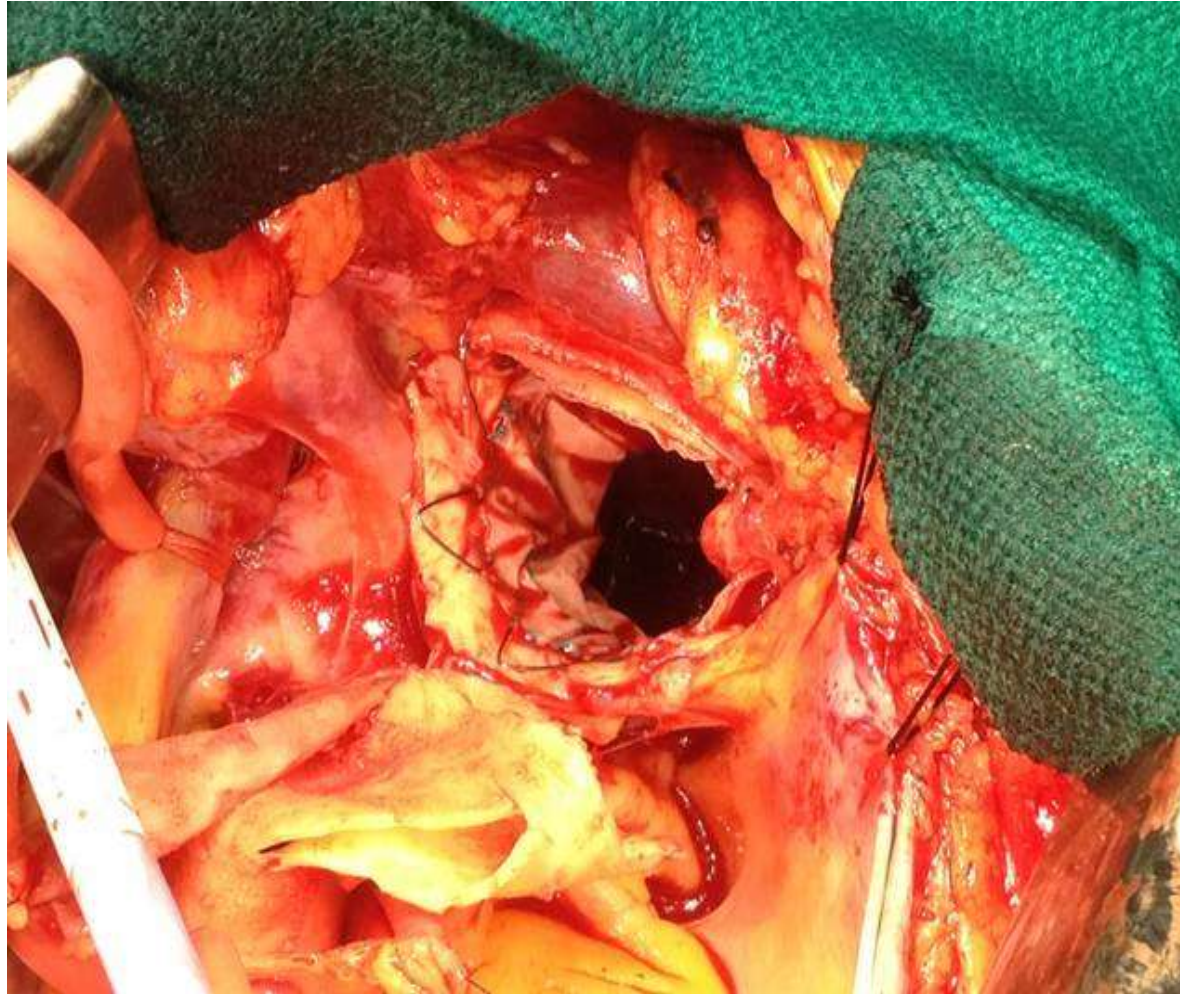
Mortality by Age and Management



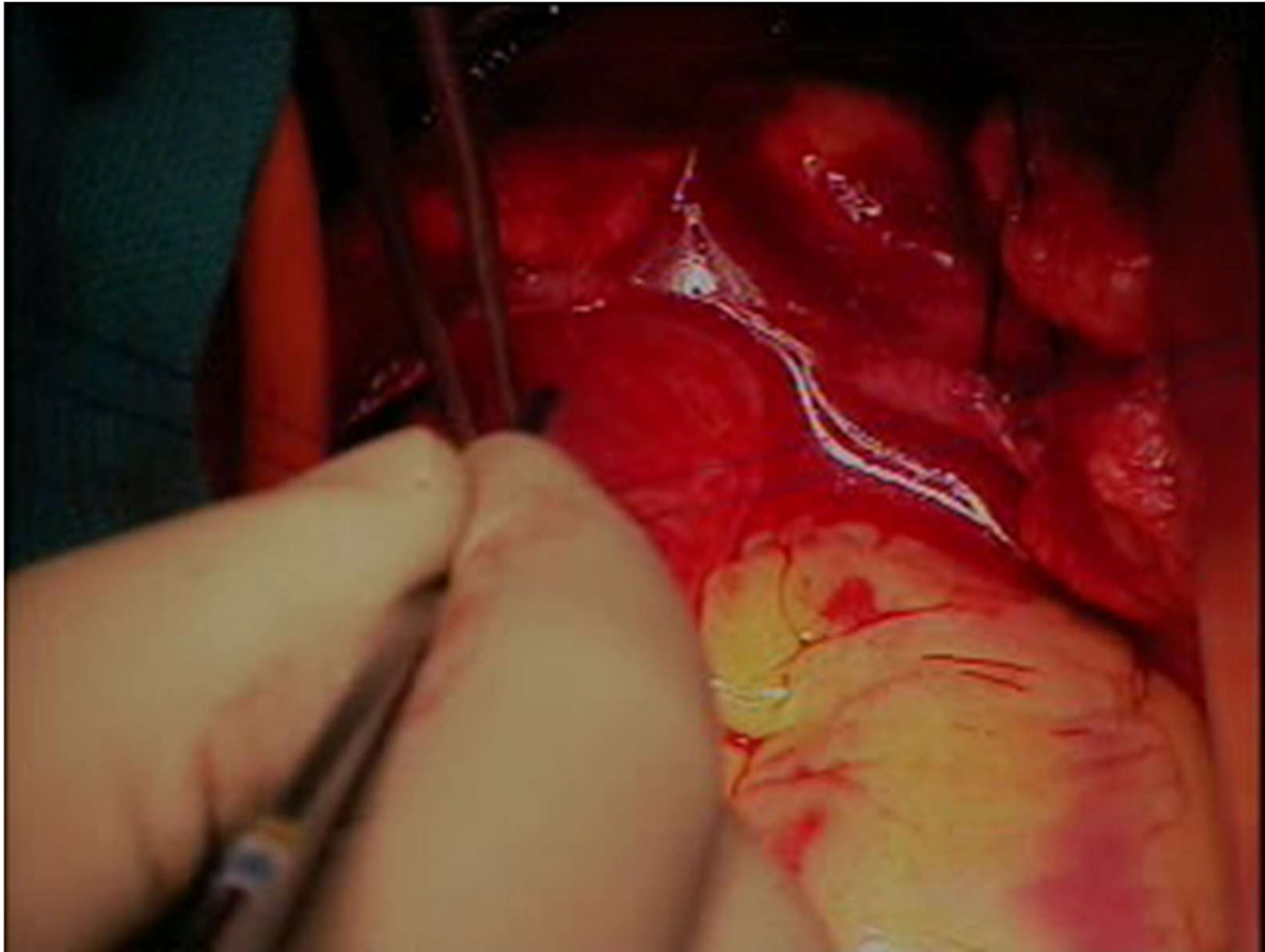
Acute Type A Dissection Role for TEVAR...



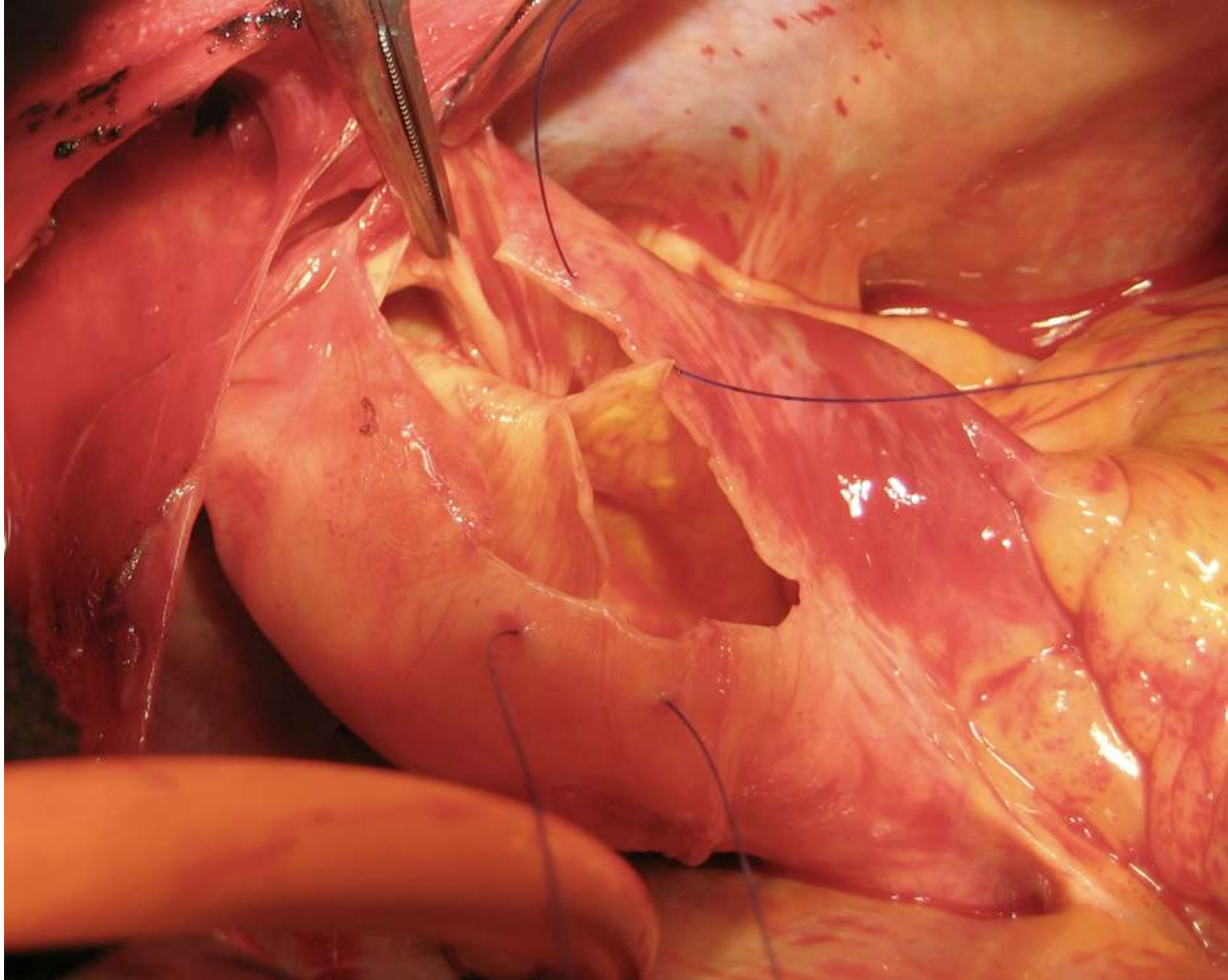
Ascending Aorta: Retrograde TAAD



Type A Dissection



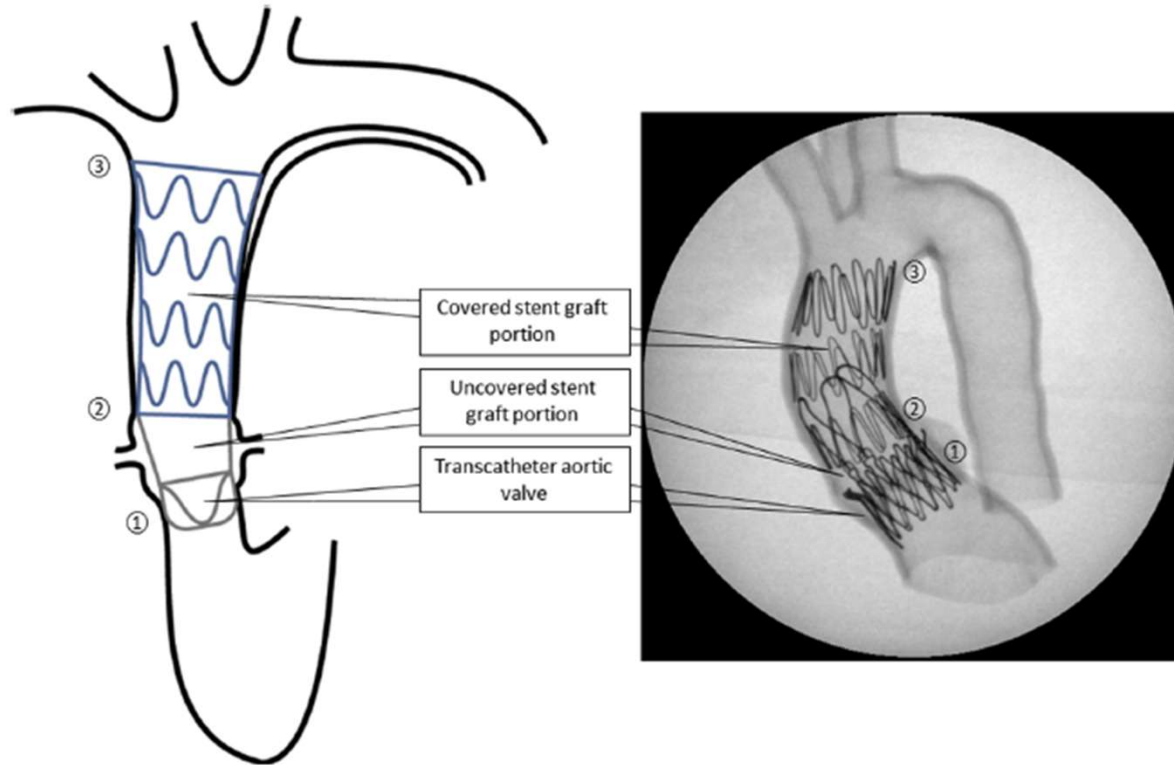
Type A Dissection



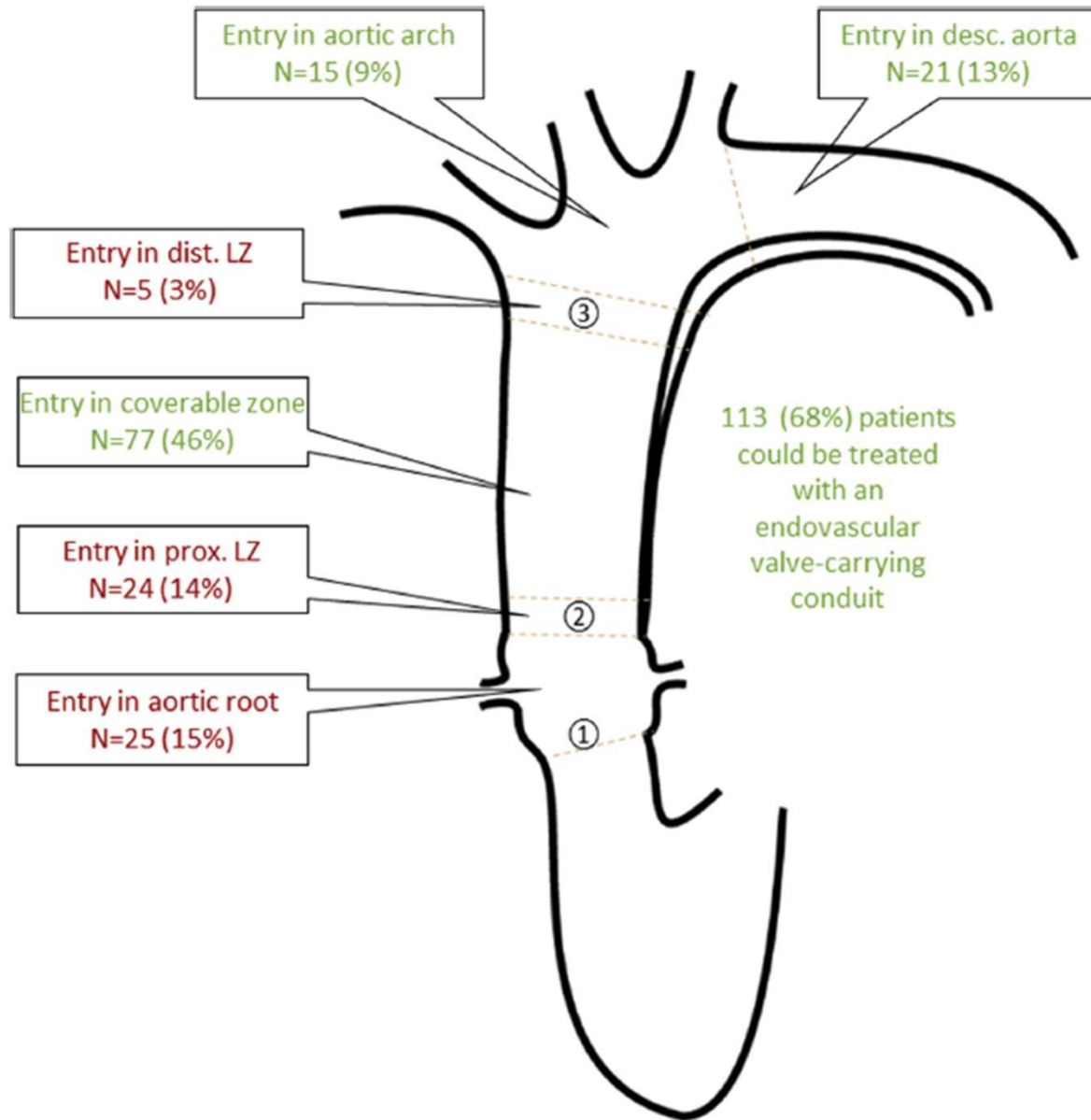
Goals of Surgical Repair

- Open Repair
 - Replace ascending aorta and origin of intimal tear to prevent rupture, malperfusion and promote distal aortic remodeling
- Endovascular Repair
 - Cover origin of intimal tear to depressurize false lumen, prevent rupture, malperfusion, and promote distal aortic remodeling
 - 10-20% pts with Type A dissection are medically unfit for open surgical repair

Endovascular Valve-conduit



From 2004 to 2017, evaluated 167 high quality CT scans of pts undergoing ATAAD repair
Assessed feasibility of simulated trans-apical ascending aortic valve carrying conduit
considered landing zones to be at annulus, and 10 mm starting at STJ and ending at Innominate artery
5% oversizing for diameter



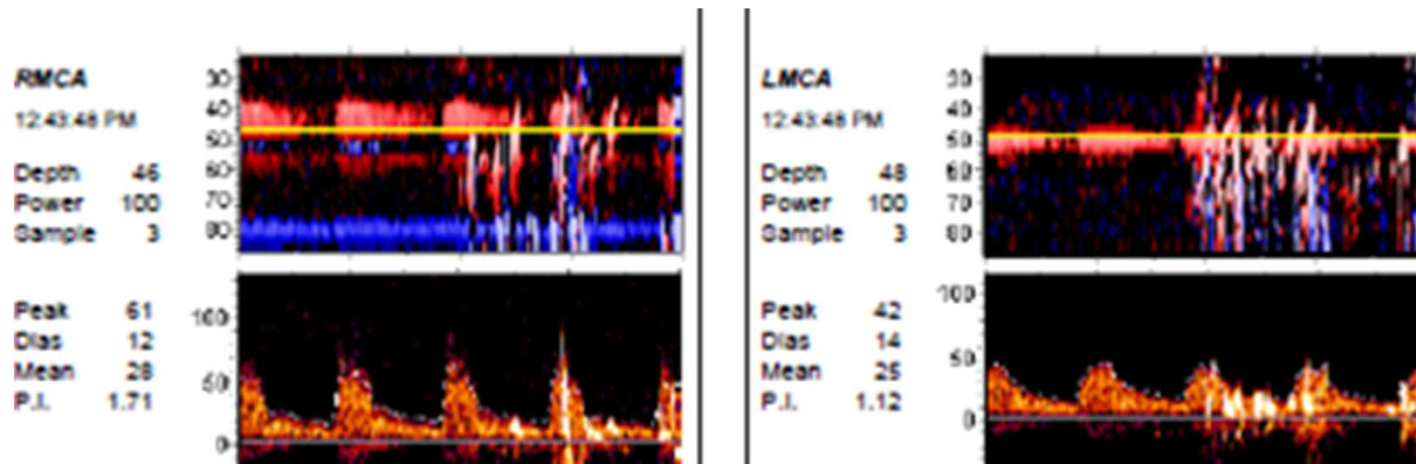
to 68% with ATAAD meet anatomic requirements (29% with tear at or below proximal landing zone)

Median distance from proximal to distal LZ 89 mm

Diameter difference from STJ to Innominate artery > 10 mm in 28%

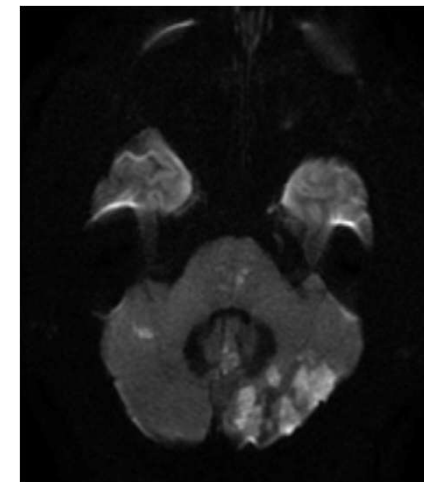
Broader TAVR sizes would be required in 7% (Annulus diam < 18mm or > 29mm)

Cerebral Micro-emboli Detection by Transcranial Doppler during TEVAR

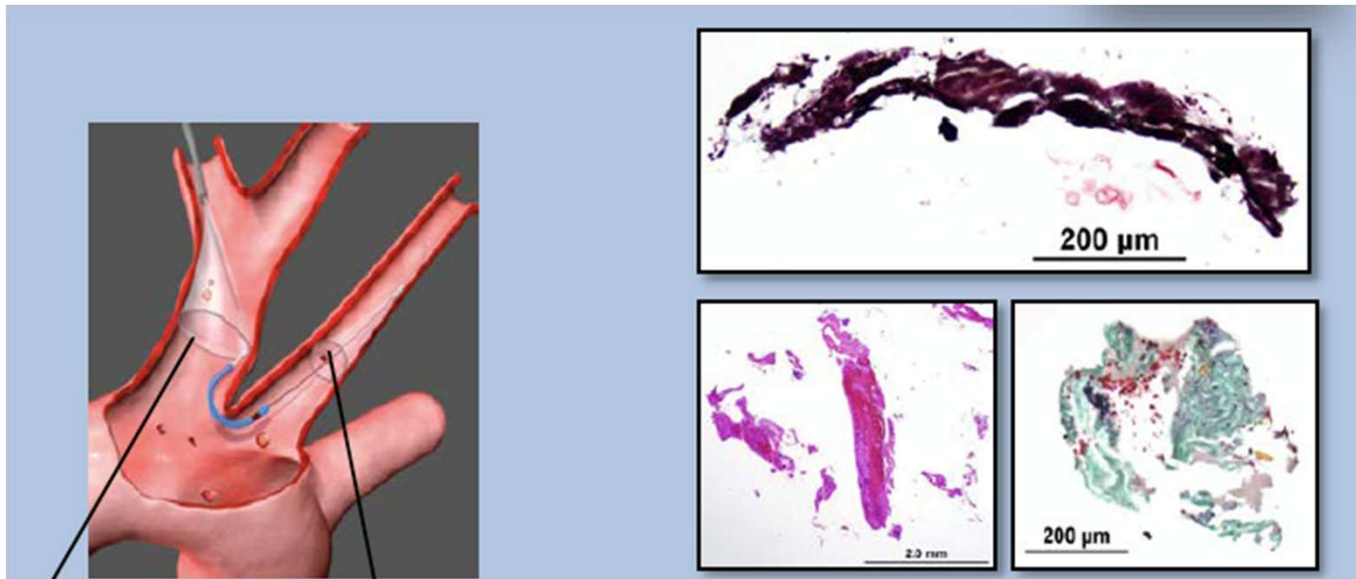
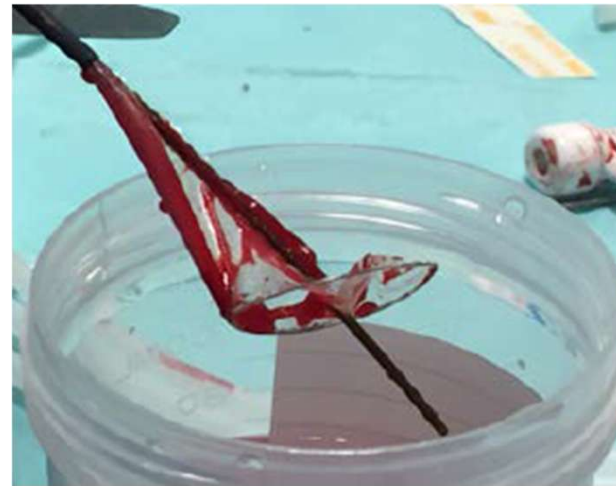


SCI after TEVAR : 63-81% by DWMRI

Kalhert, Ann Thorac Surg, 2014;98(1):53-8
Perera Br J Surg 2018;105(4):366-8

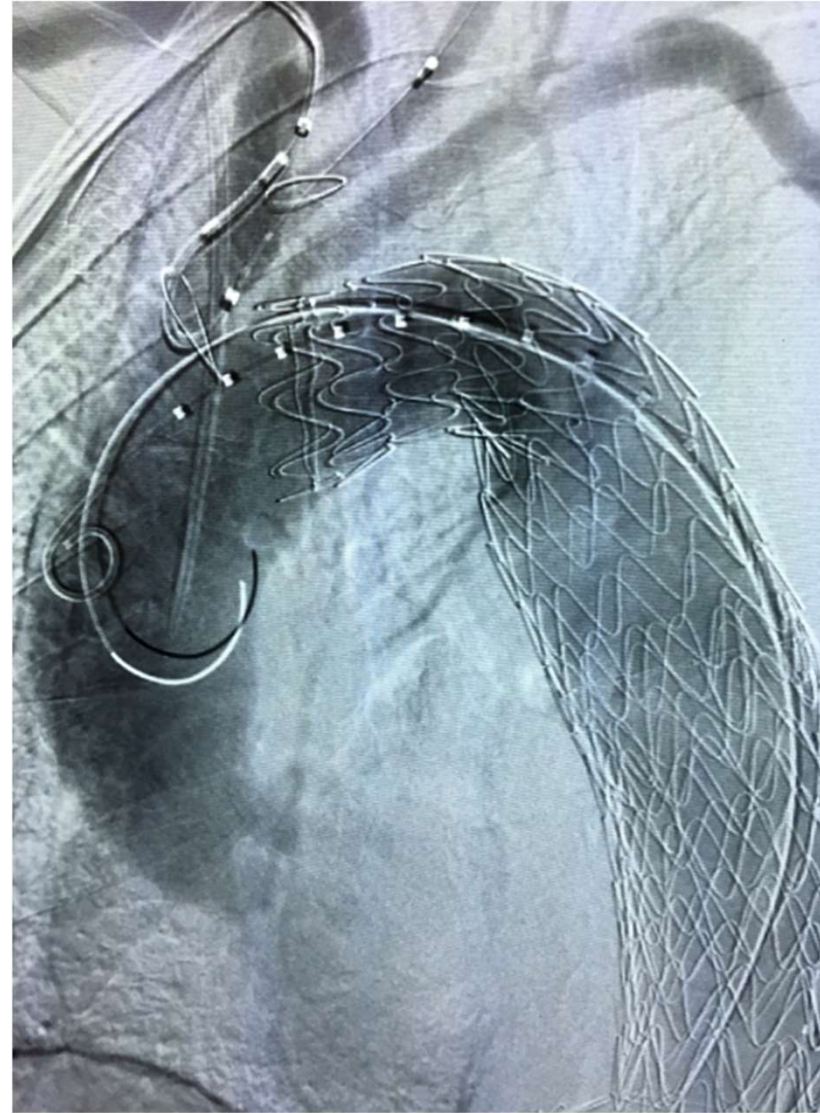
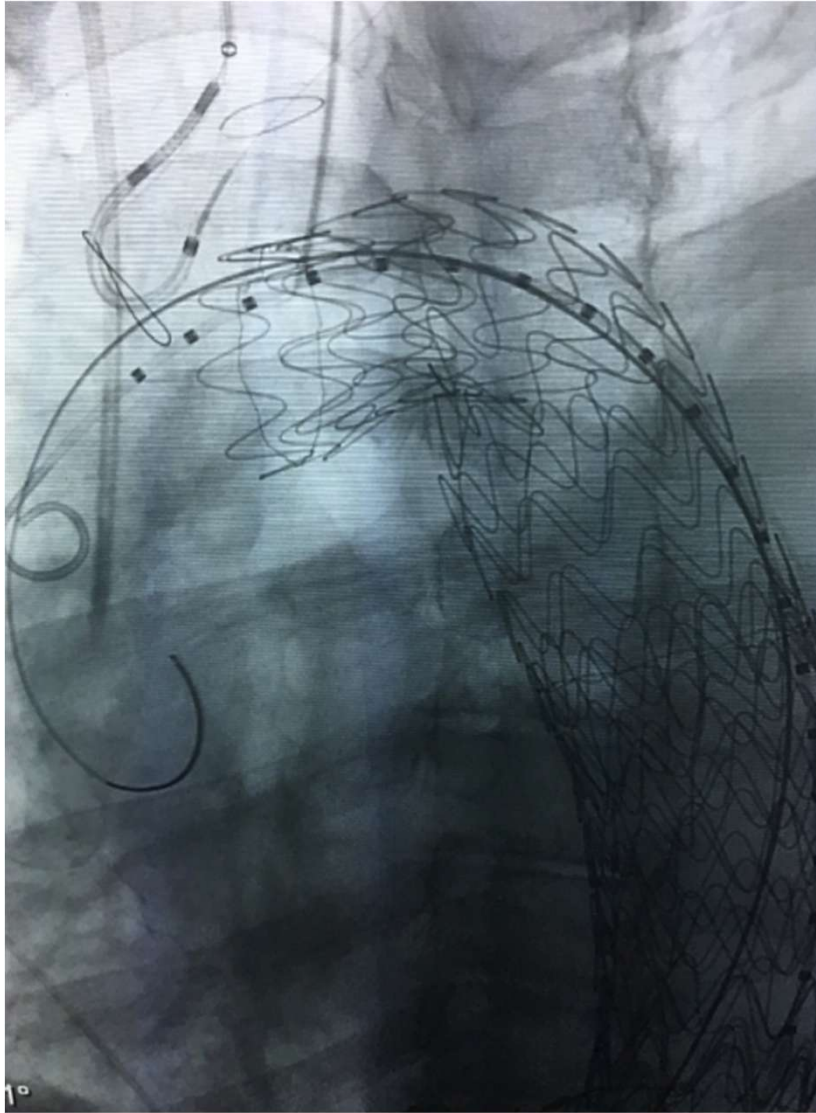


Sentinel Cerebral Embolic Protection, Claret Medical

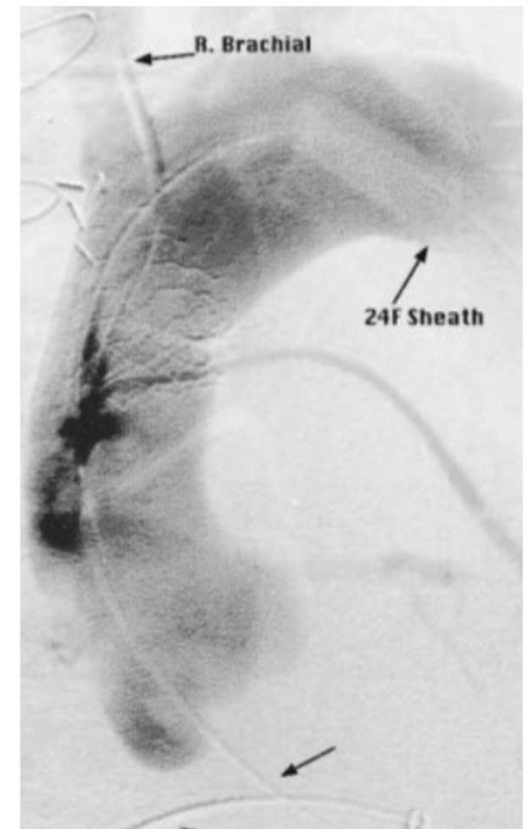
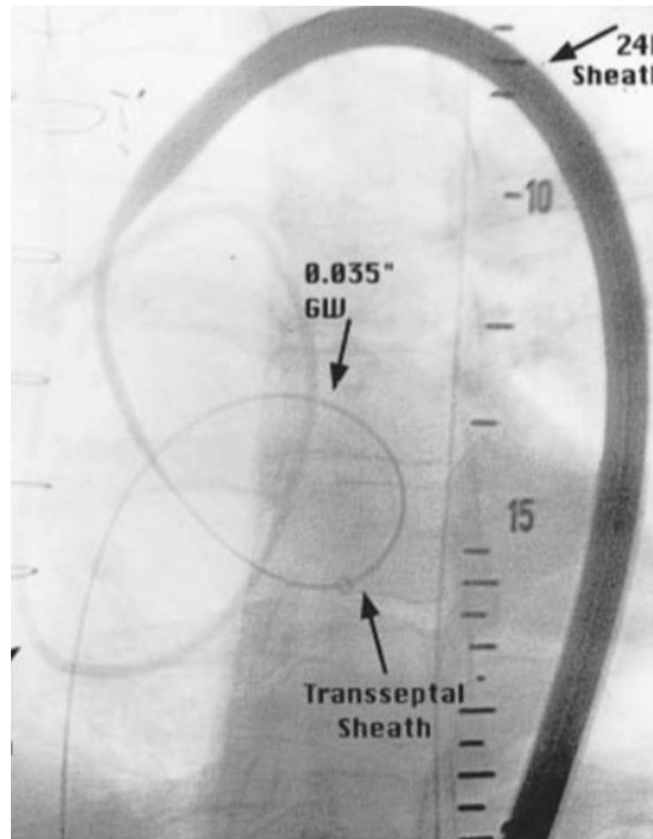


52% reduction new lesion volume on DWMRI post TAVR
Improved neurocognitive outcomes; TCT 2015

Cerebral Embolic Protection

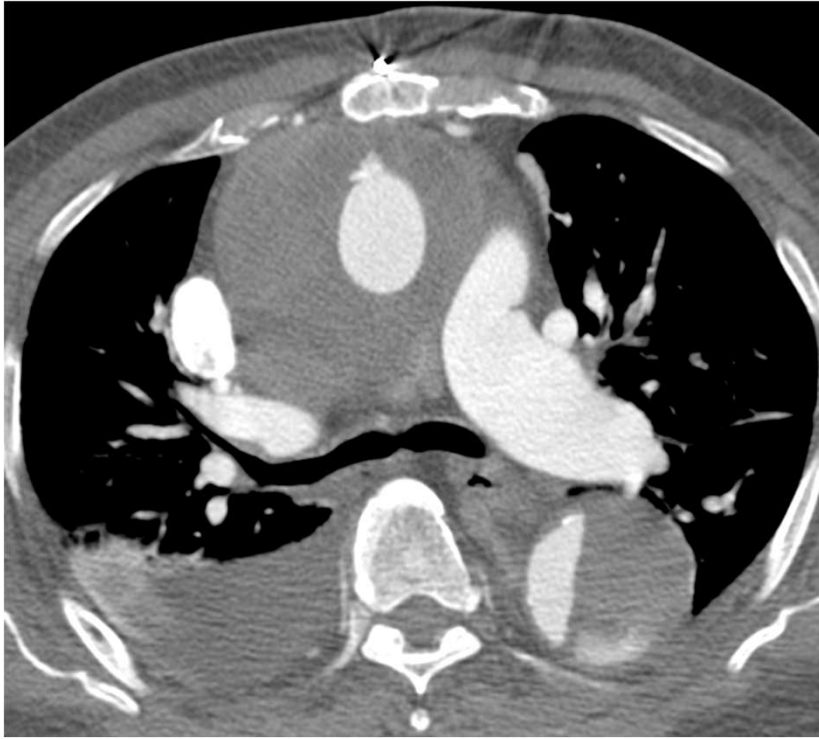


First reported TEVAR for TAAD

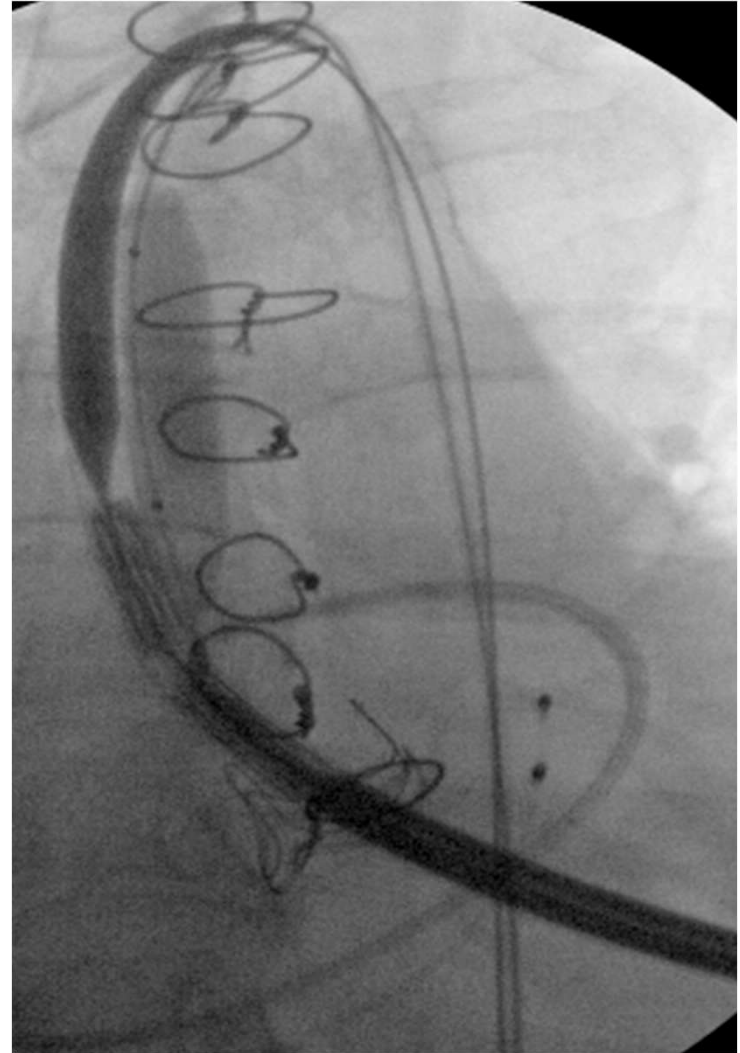


- 56 yo female TAAAD 5 months post CABG
- Successful TEVAR from femoral approach with exteriorization of wire via trans-septal approach

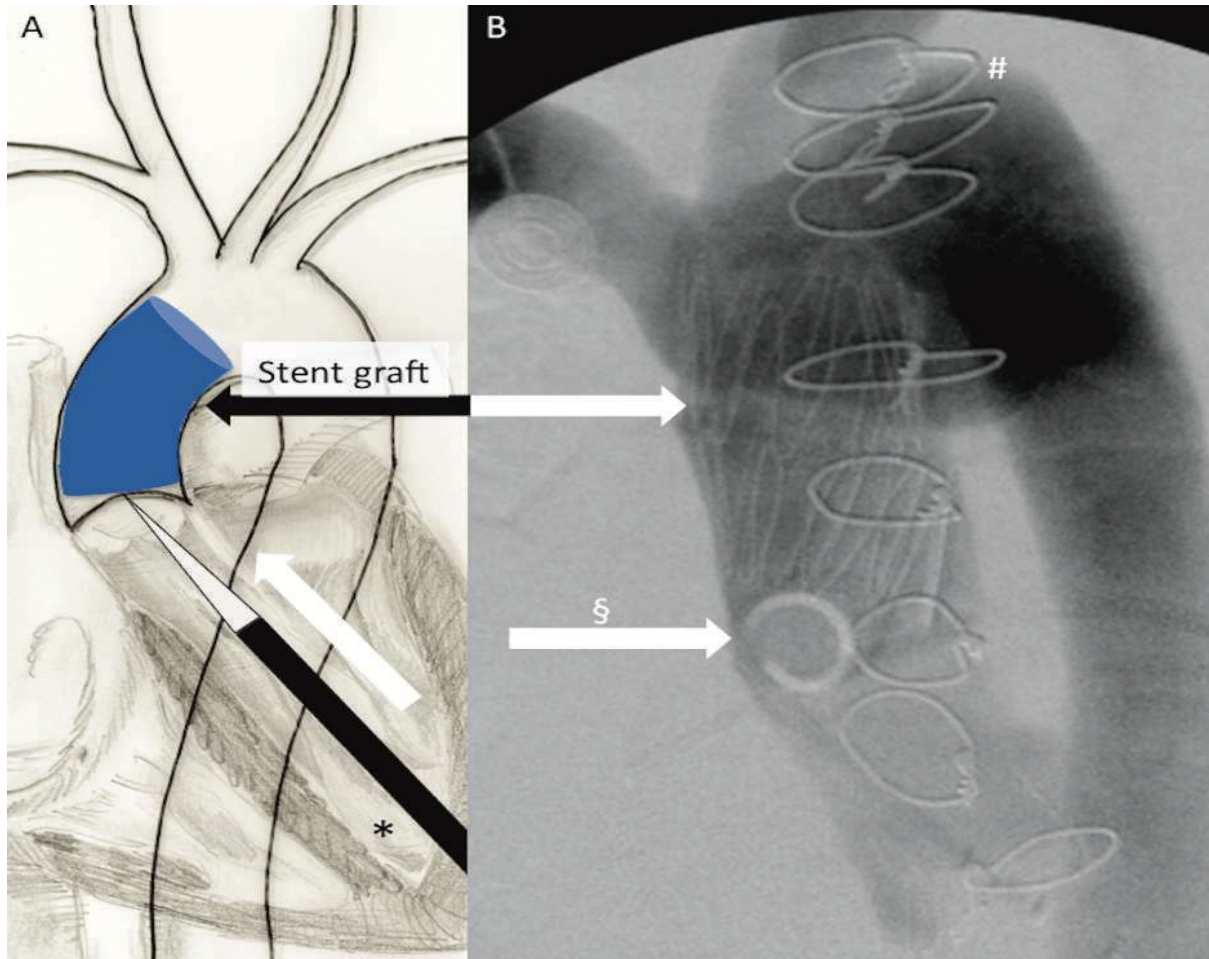
Trans-apical Ascending TEVAR



75 yo male 3 mo s/p type A dissection repair with
bioprosthetic valve conduit in 9/2012
Large peri-aortic hematoma with PSA
3 months Post repair

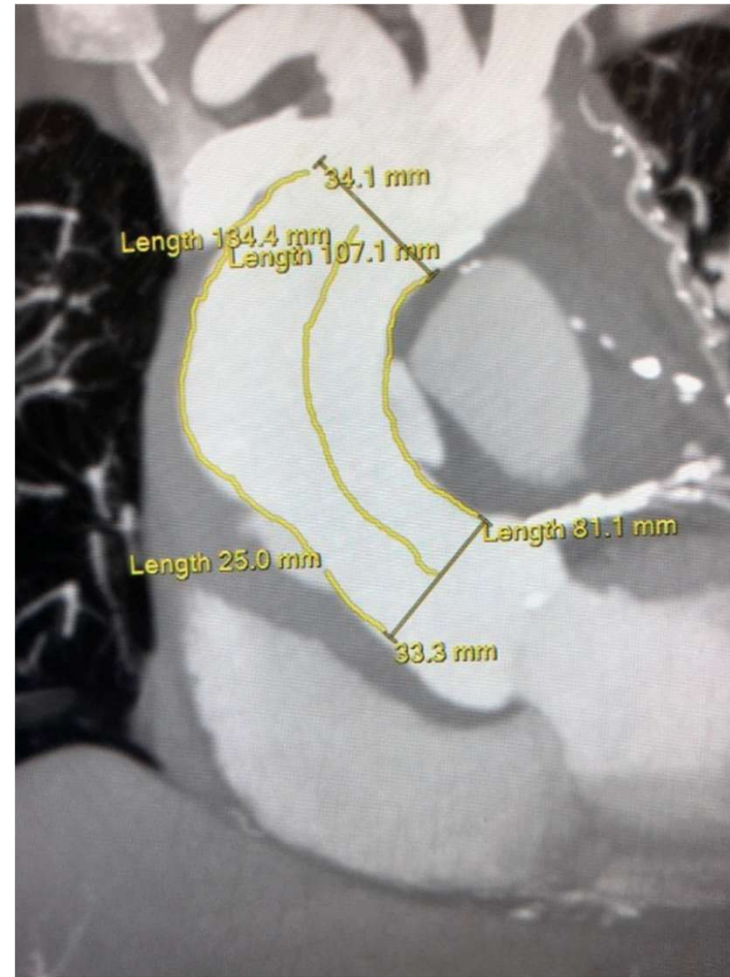
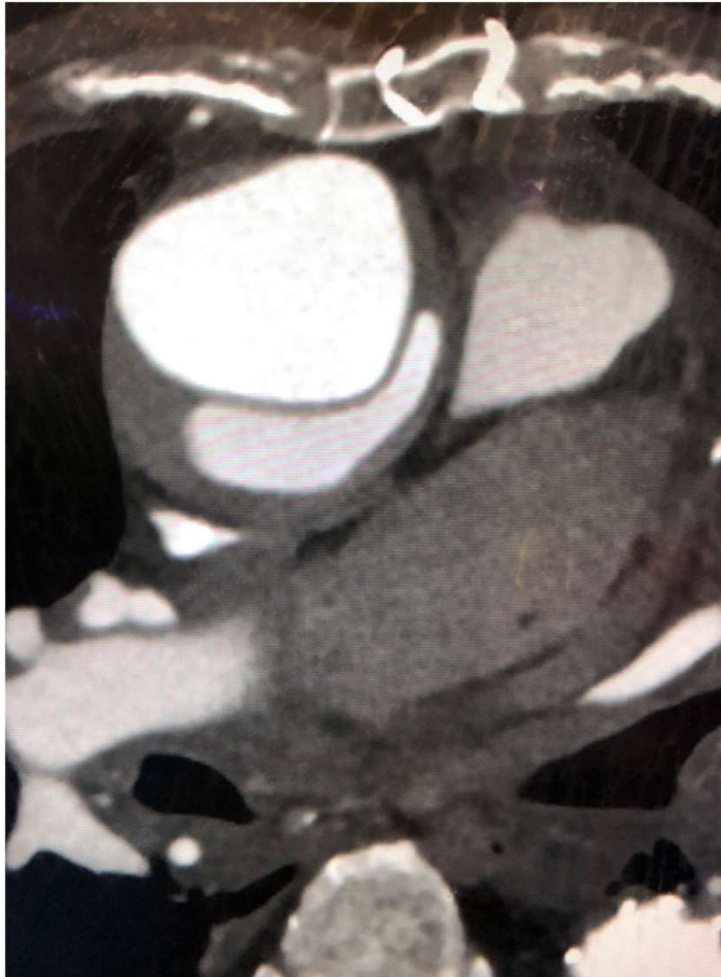

Ascending TEVAR



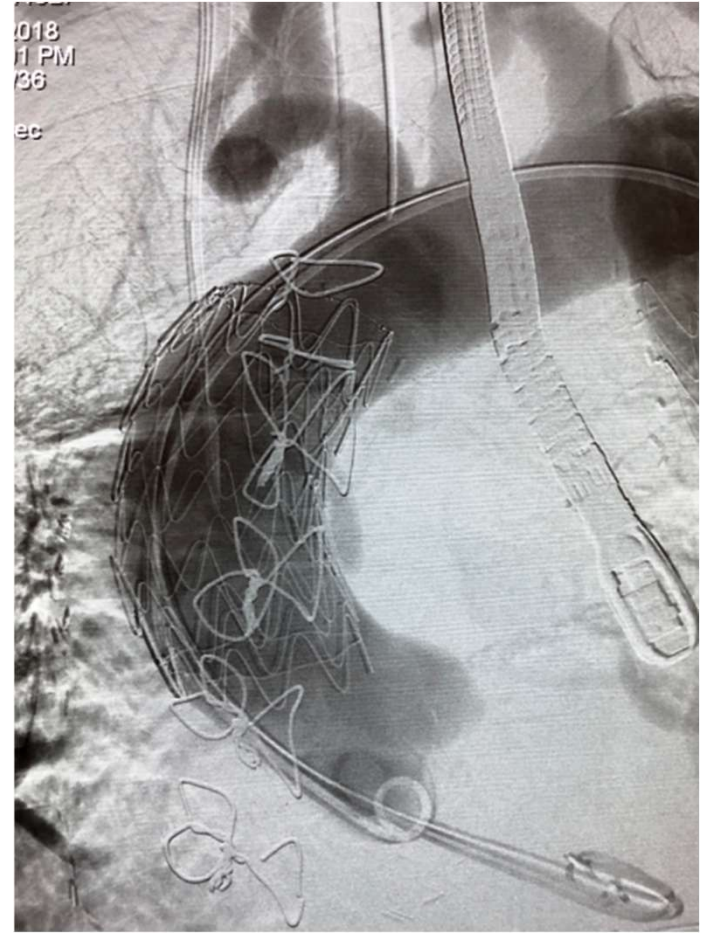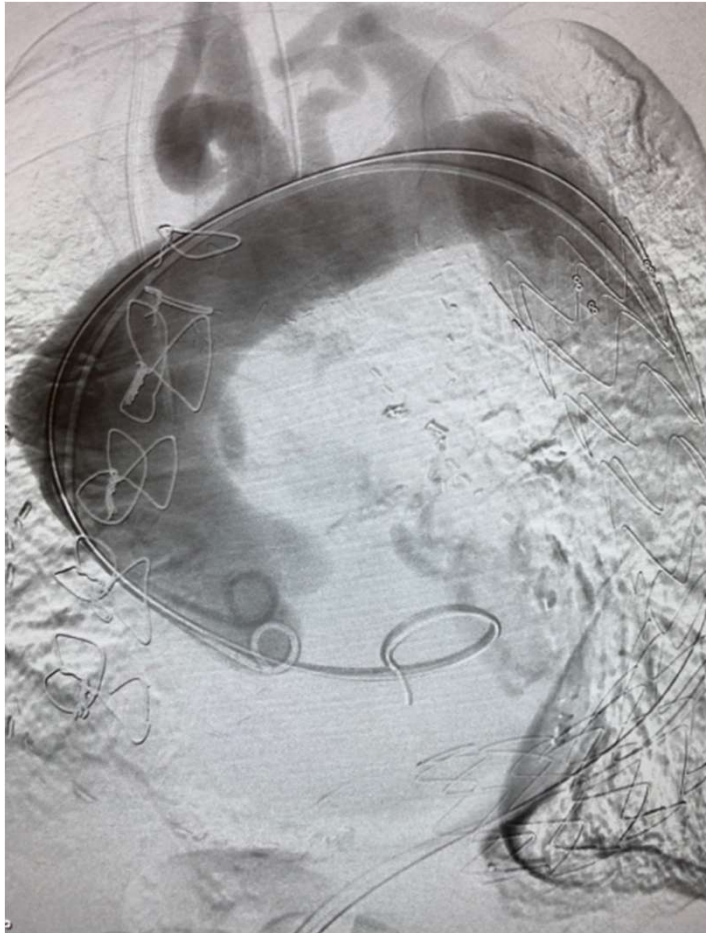
36mm x 5 cm stent graft via Trans-apical approach

Type A IMH/Dissection



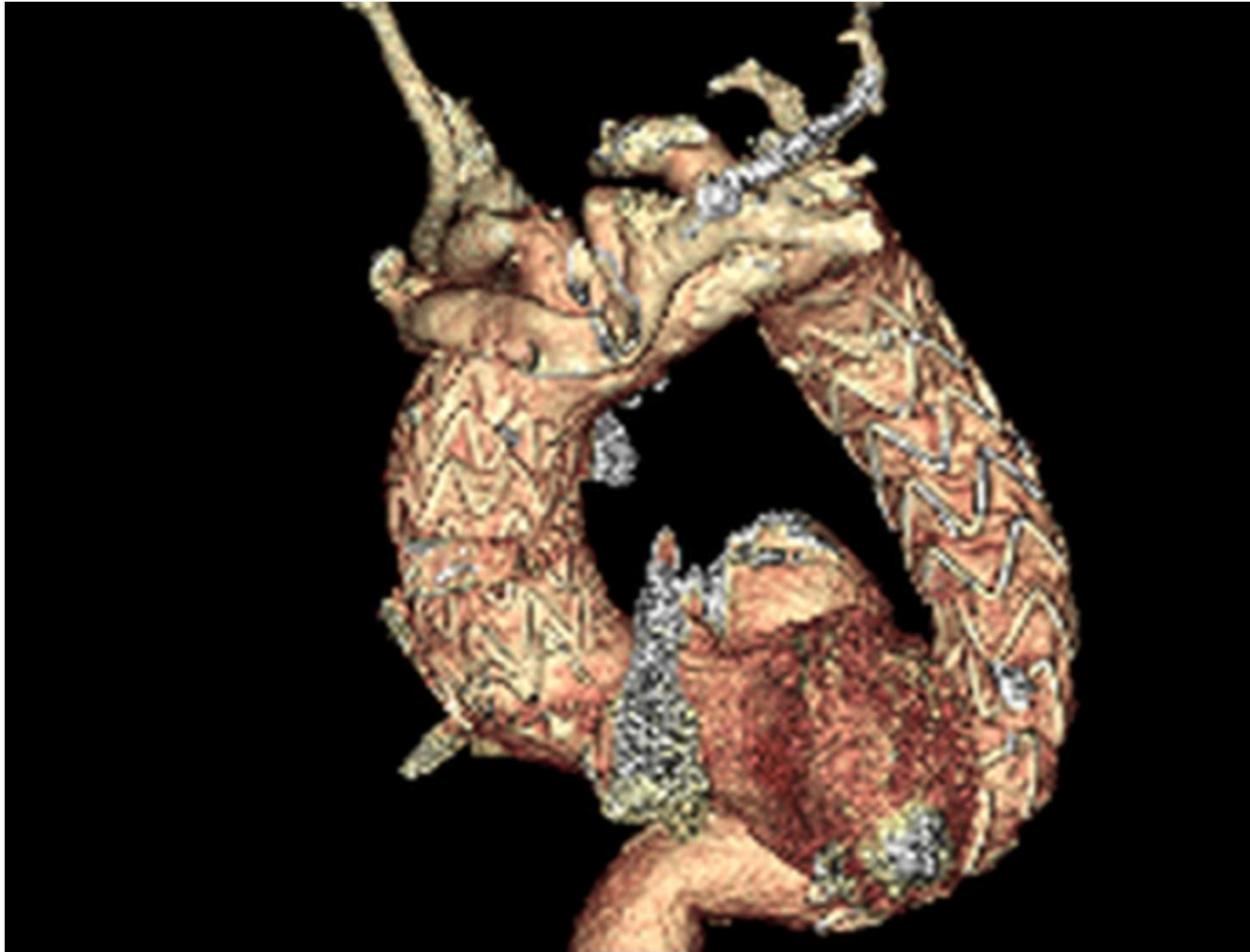
90 yo male with PAU/IMH ascending aorta progressing to focal contained rupture 1/18;
s/p TEVAR 8/17 for symptomatic IMH desc aorta

Trans-femoral Ascending TEVAR

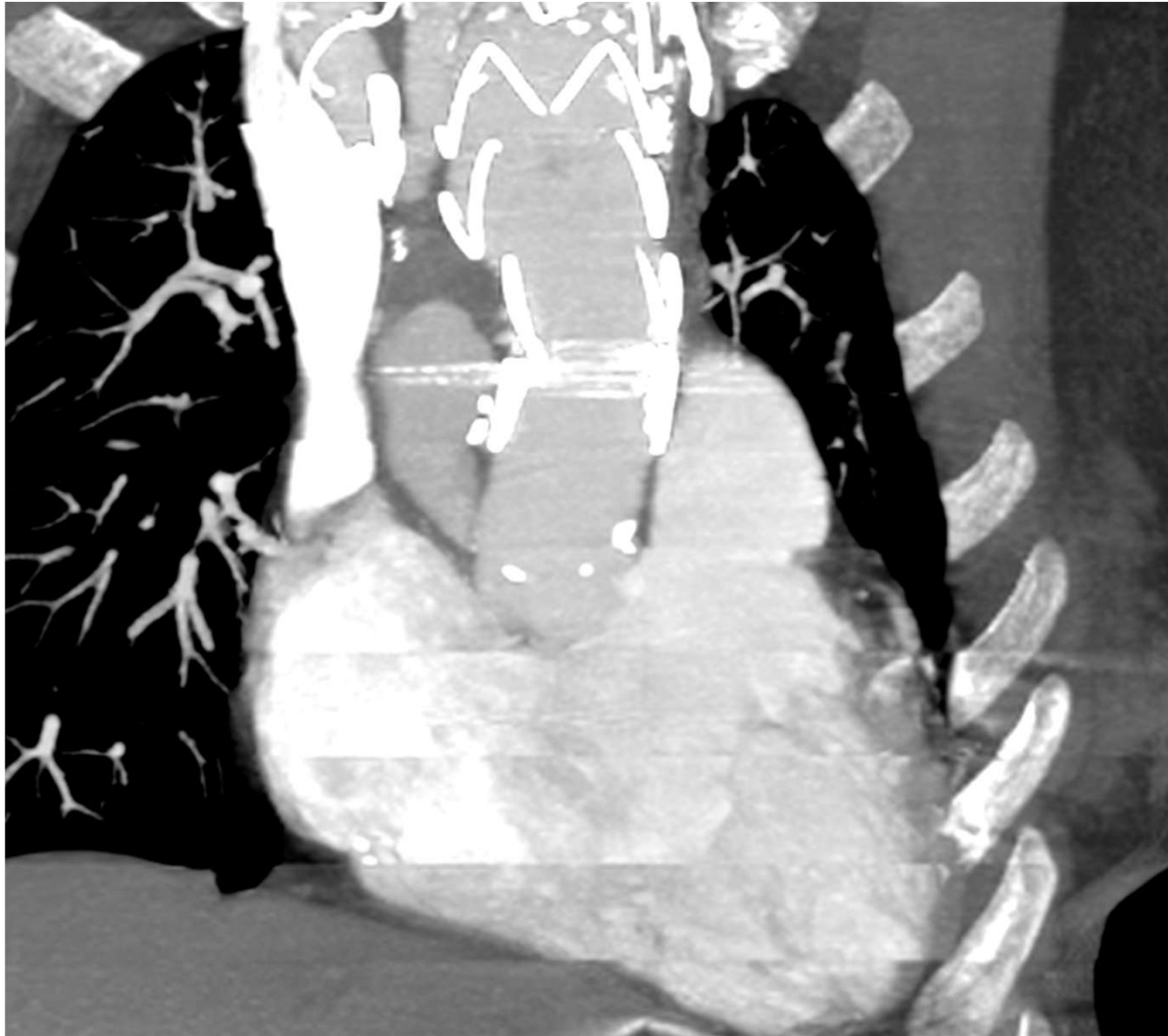


Trans-femoral TEVAR with 45 mm x 10 cm Gore stent graft

Follow-up CT at 18 months

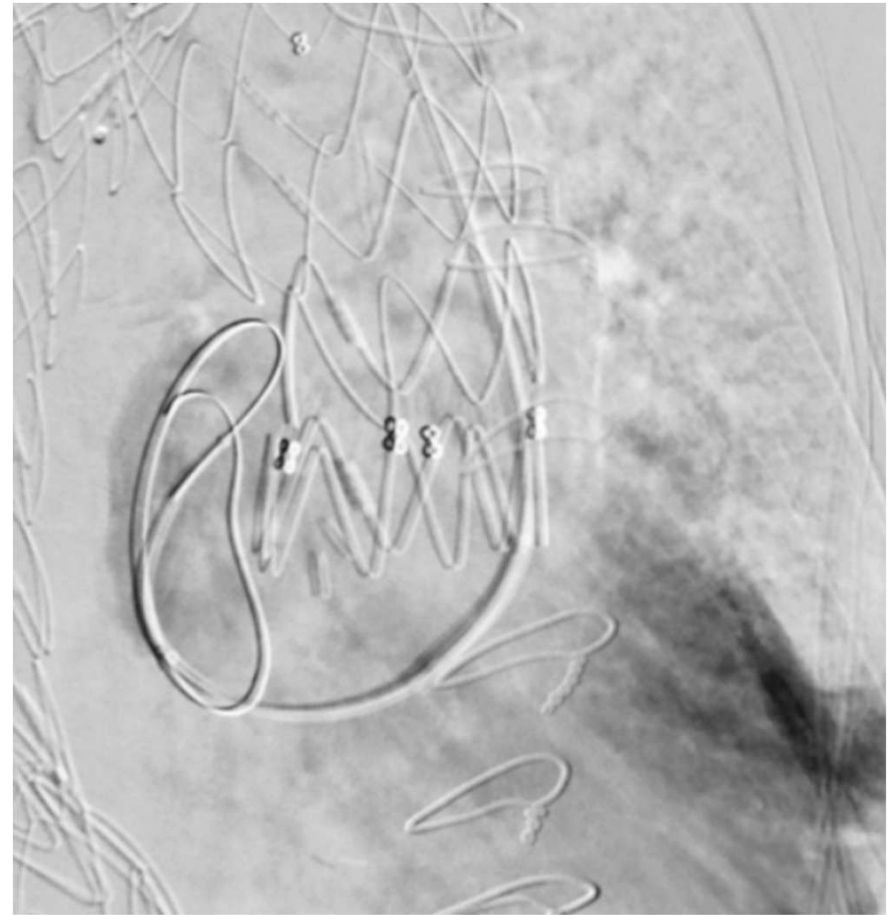
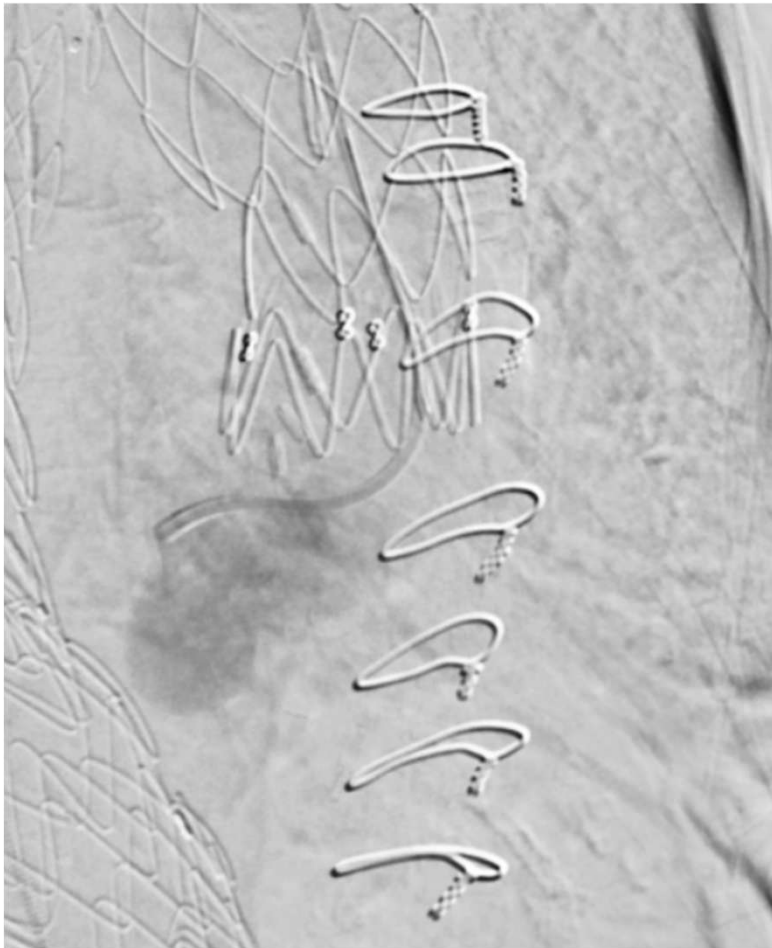

Pseudoaneurysm Embolization



80 yo female 3 years post Zone 0 TEVAR and arch debranching
with proximal PSA 2/18

Pseudoaneurysm Embolization



Pseudoaneurysm Embolization

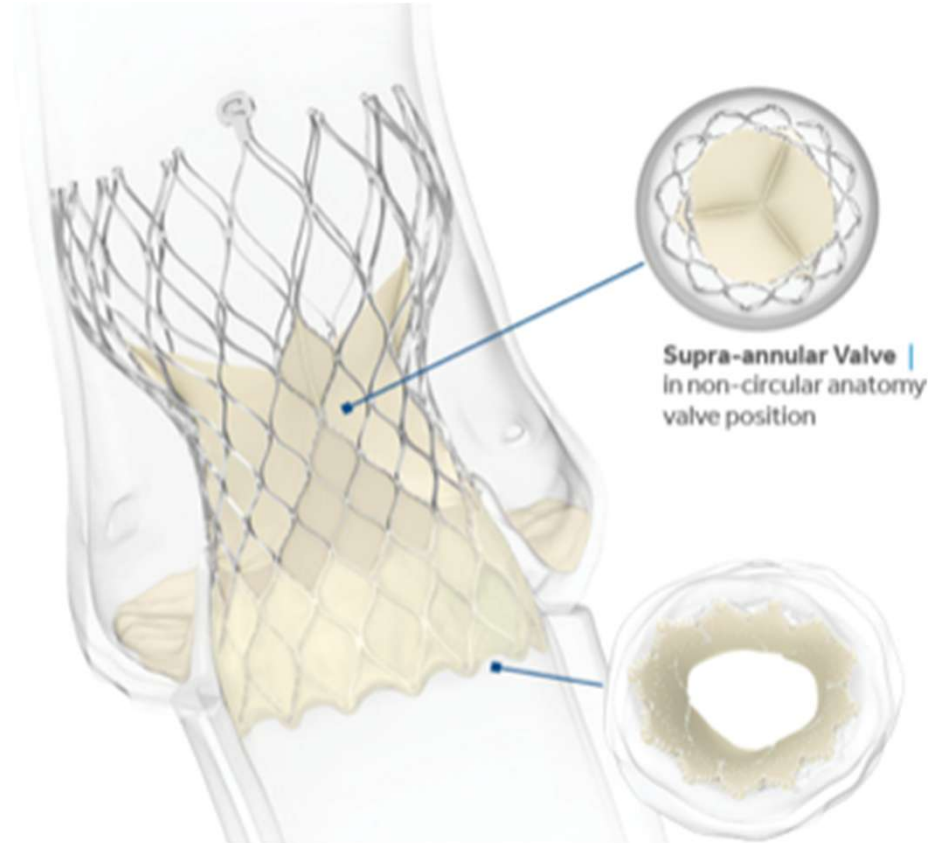


Successful coil embolization and vascular plug



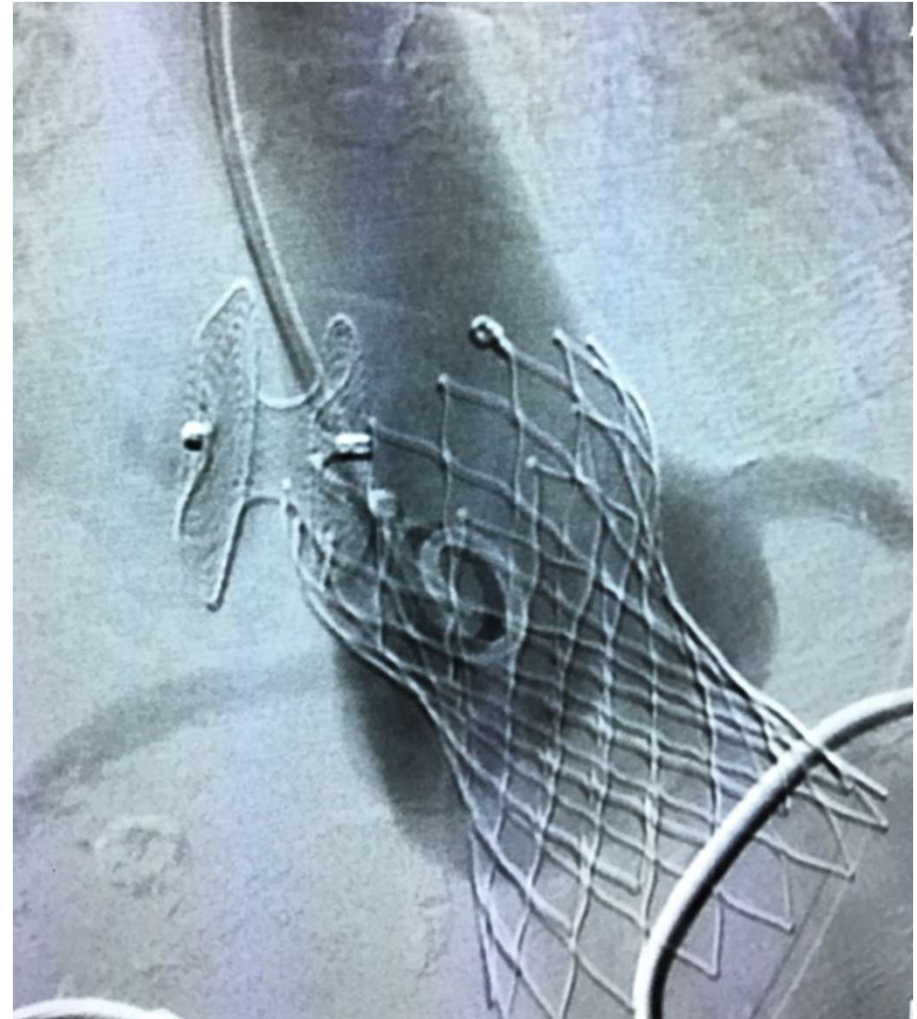
CTA 2 months post

Ascending PSA post TAVR



75 yo female post MV repair 2006, TAVR 6/17, EF 25% presented with PSA 5 mo post

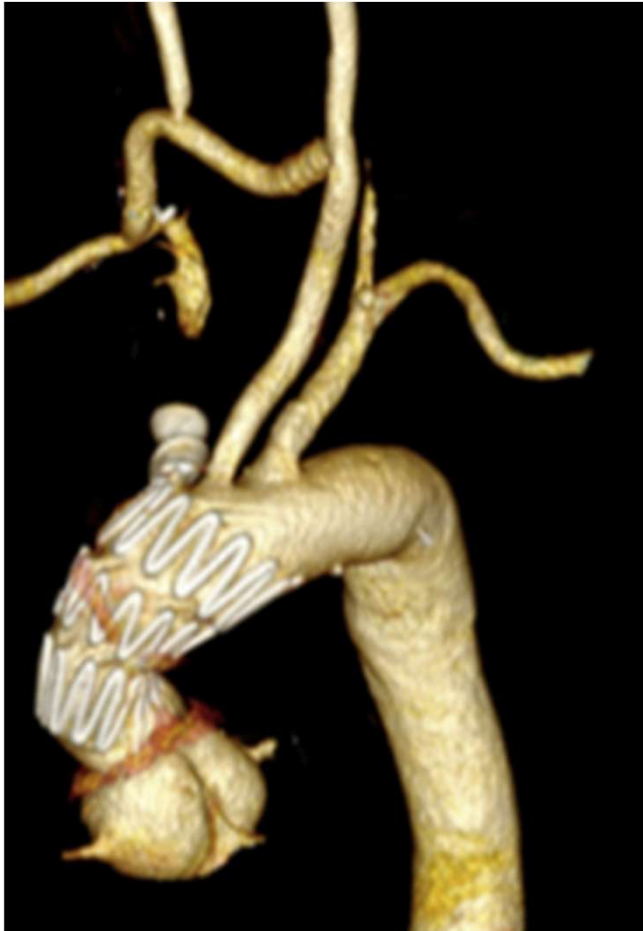Ascending PSA Plug



11/17: PSA closure with 13 mm Amplatzer Septal Occluder device

11/19 : TTE no flow in PSA, aortic root stable 38mm, EF 30-35%, no AI or AS

Mangialardi et al



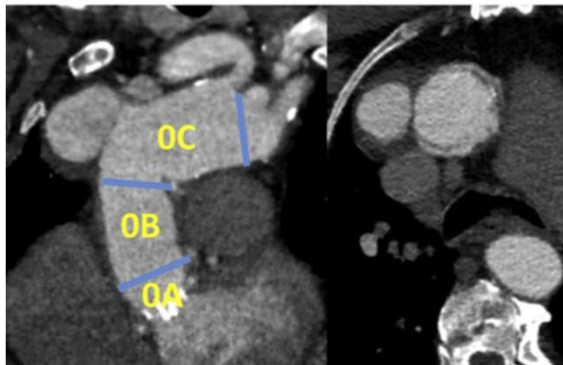
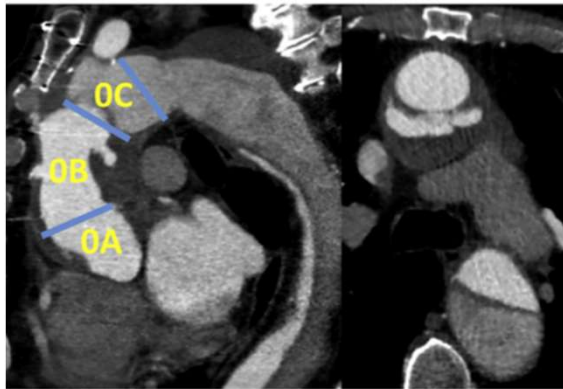
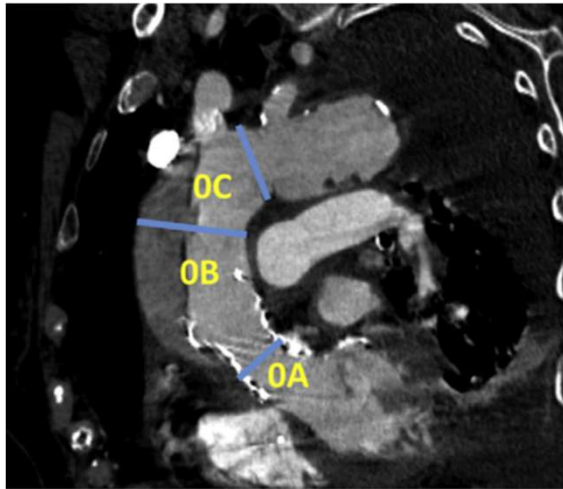
- From 2009-2013, 4 pts with TAAD underwent TEVAR
- Technical success 100% (stent graft diam 35-40 mm, length 55-81 mm)
- Mortality 0%,
- Median follow-up 15 mo

Zone zero thoracic endovascular aortic repair: A proposed modification to the classification of landing zones

Eric E. Roselli, MD,^{a,b} Jay J. Idrees, MD, MPH,^{a,b} Douglas R. Johnston, MD,^{a,b}
Matthew J. Eagleton, MD,^{a,c} Milind Y. Desai, MD,^{a,d} and Lars G. Svensson, MD, PhD^{a,b}

- 2006-2016
- 39 pts endovascular repair ascending aorta unfit for open surgery
- ATAAD 31%, IMH 5%, PSA 56%, chronic dissection 8%
- Asc TEVAR 36 pts
- Occluder device 3 pts

Roselli et al, CCF

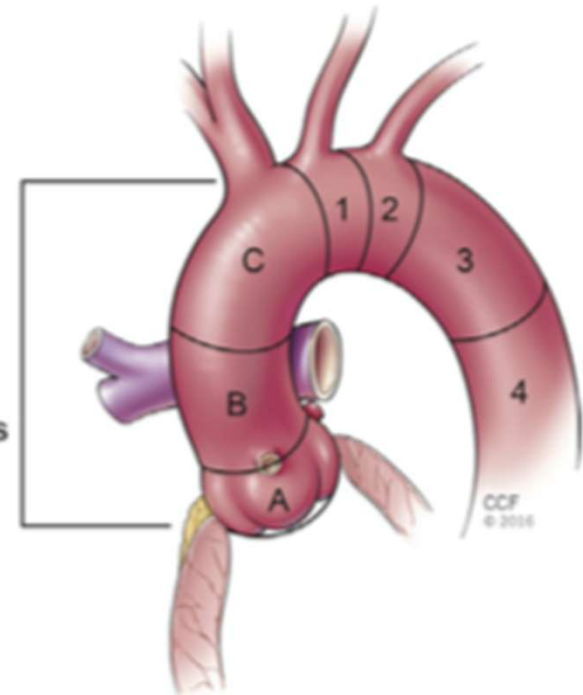


Zone 0

0C: RtPA to Innominate

0B: Coronaries to RtPA

0A: Anulus to coronaries

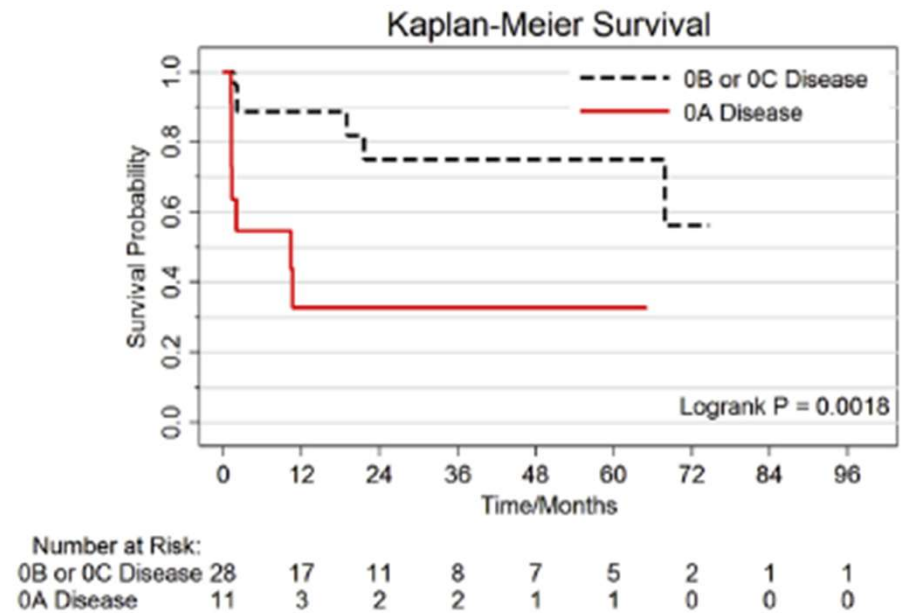
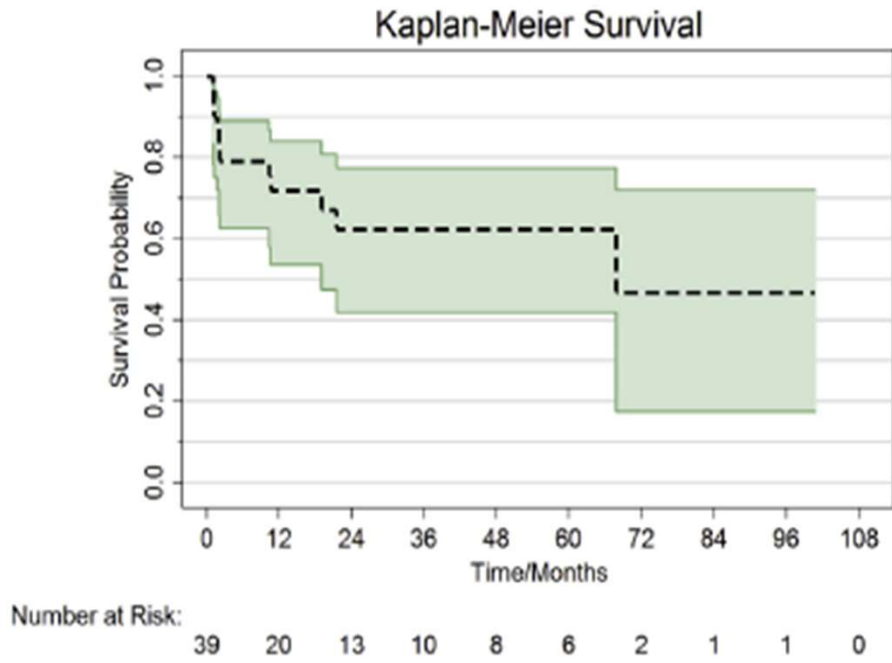


- With ATAAD, pathology extended to 0A 71%, 0B 29%
- With PSA, pathology in 0B 50%, 0C 45%, 0A 5%
- Device delivery: transfemoral 56%, transapical 22%, transaxillary 23%
- Device deployed with CPB in 2 pts

Roselli et al, CCF

- Operative mortality 13%, all after emergent ATAAD
- CVA 10%
- MI 5%, HD 5%
- Survival at 30 D, 1 yr, 5 yr
 - Overall 81%, 74%, 64%
 - PSA 100%, 90%, 68%
 - ATAAD/IMH 57%, 41%, 41%

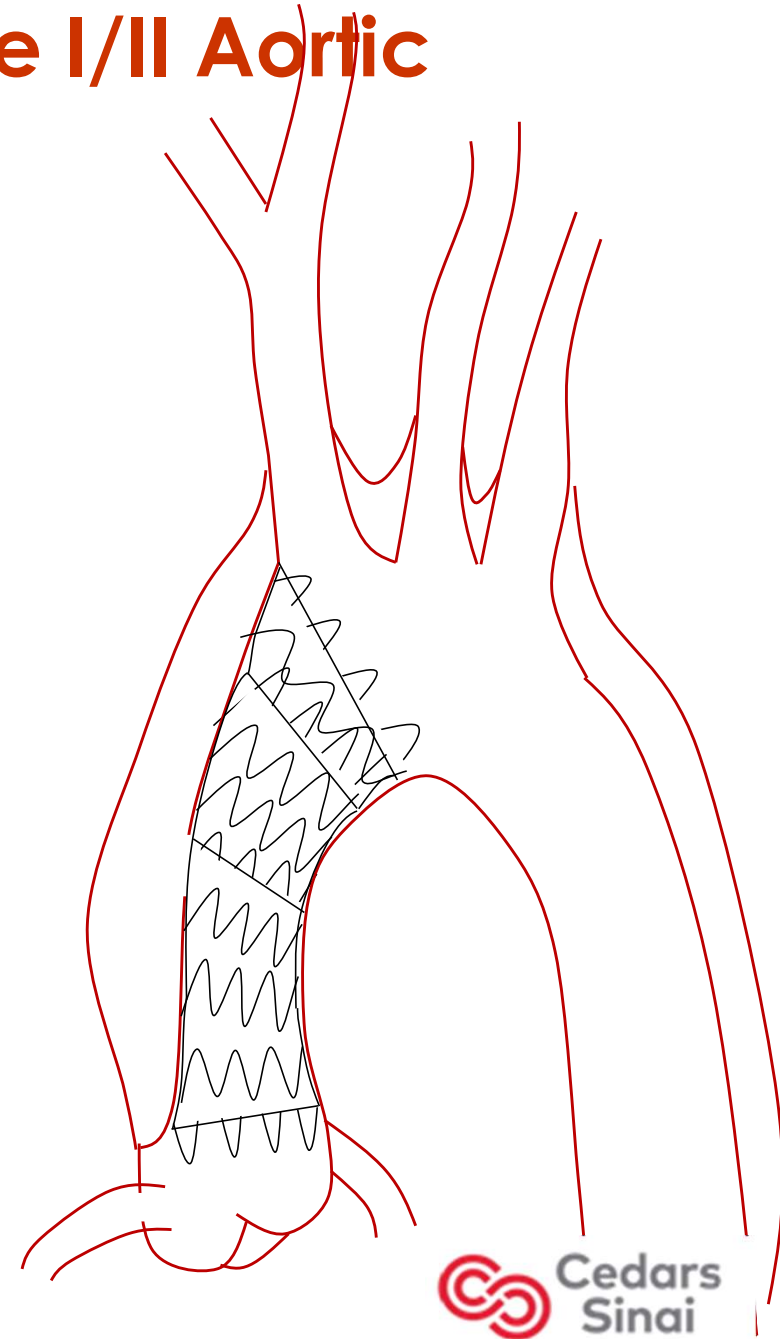
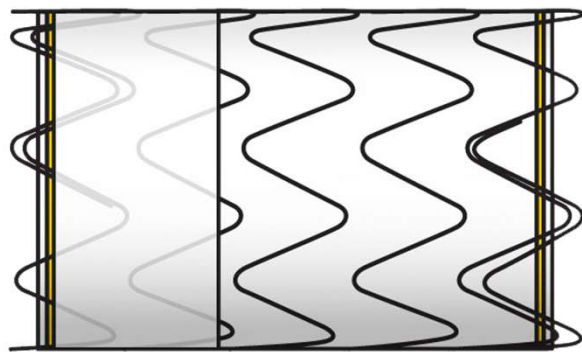
Survival



Predictors of mortality: Extension of disease to below OA (from annulus to coronaries) and older age

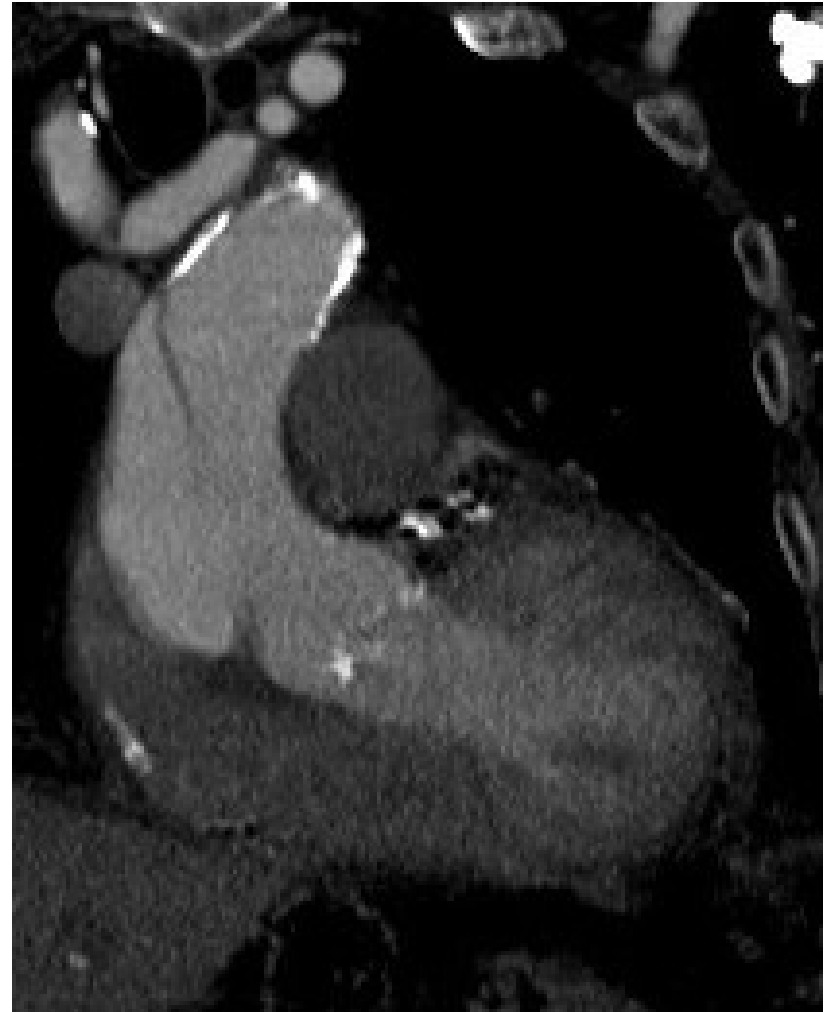
Evaluation of the GORE® TAG® Thoracic Branch Endoprosthesis in the Treatment of DeBakey Type I/II Aortic Dissection

- Early Feasibility Study
 - 10 patients, 3 Sites
- Primary treatment using TBE Aortic Extenders to stabilize the length of the dissected ascending aorta

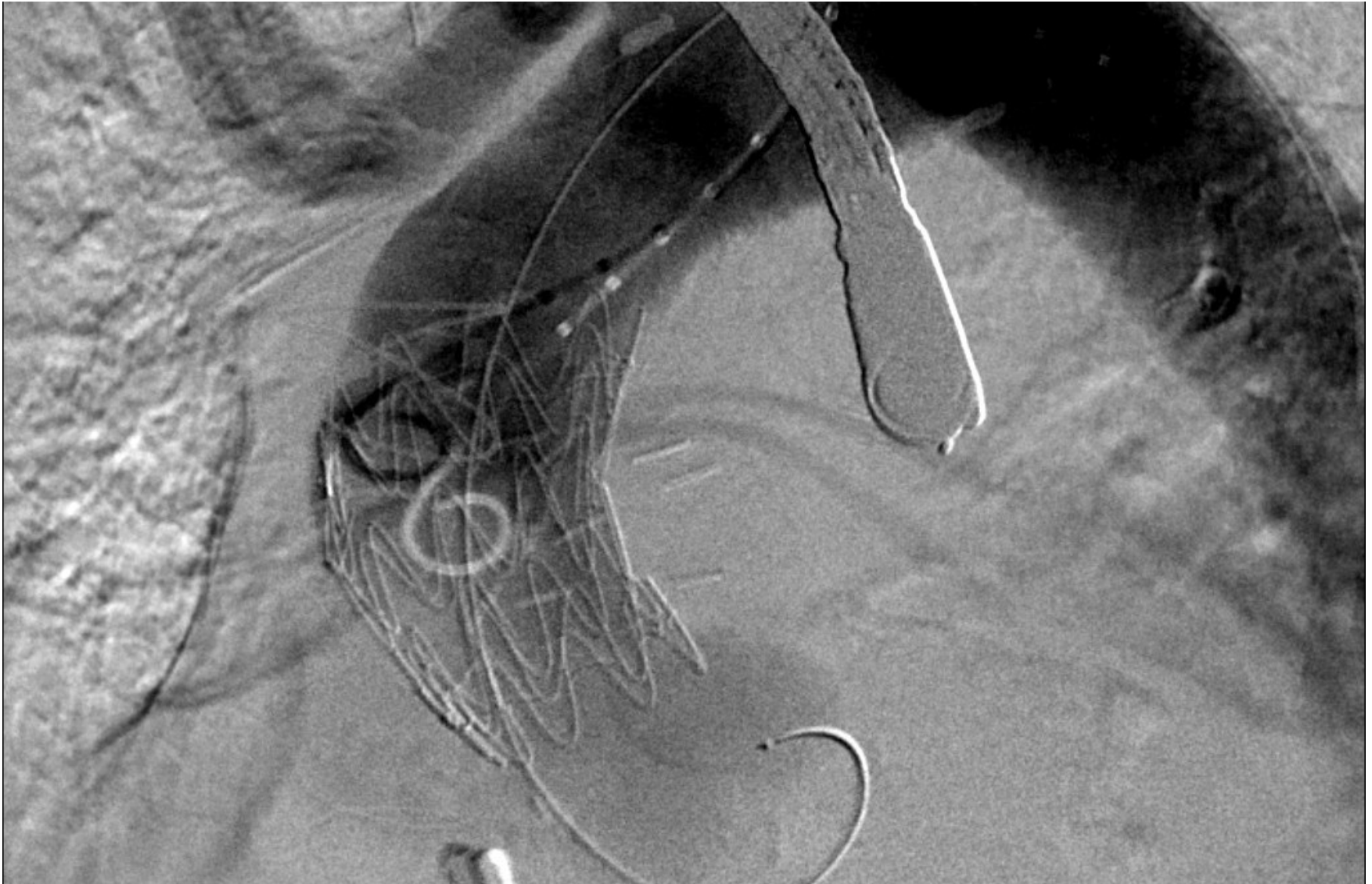

Acute Type A (DeBakey II) Dissection

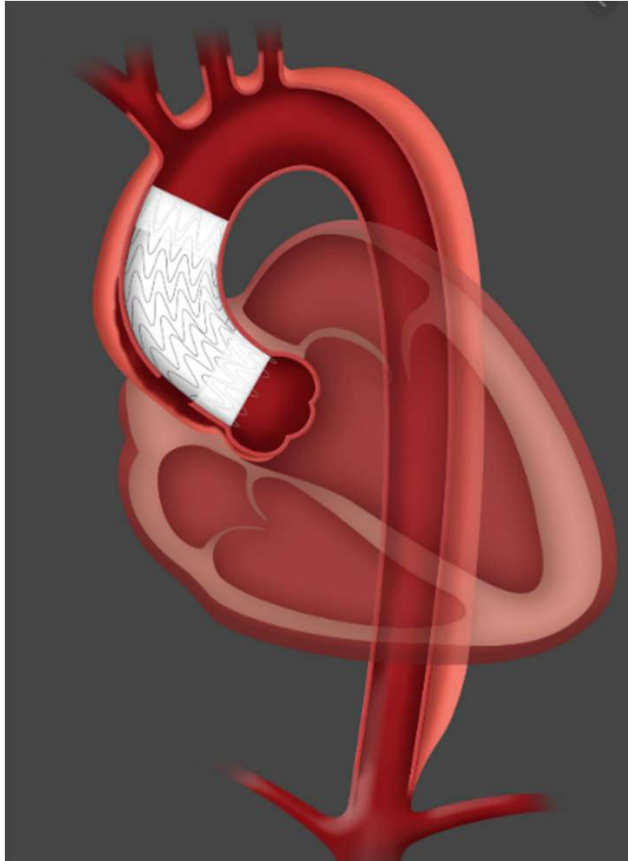
- 87 yo man
ATAAD
- PMH: HTN, HLD,
COPD
- PSH: CABG



Post Deployment Angiogram



New Ascending Stent graft (ASG)






- GORE ASG FDA IDE
- ARISE EFS study
- Site specific design (ascending aorta)
- Staged deployment
- Approved for 8 sites, 30 pts



GORE® Ascending Stent Graft

Deployment to Intermediate Diameter

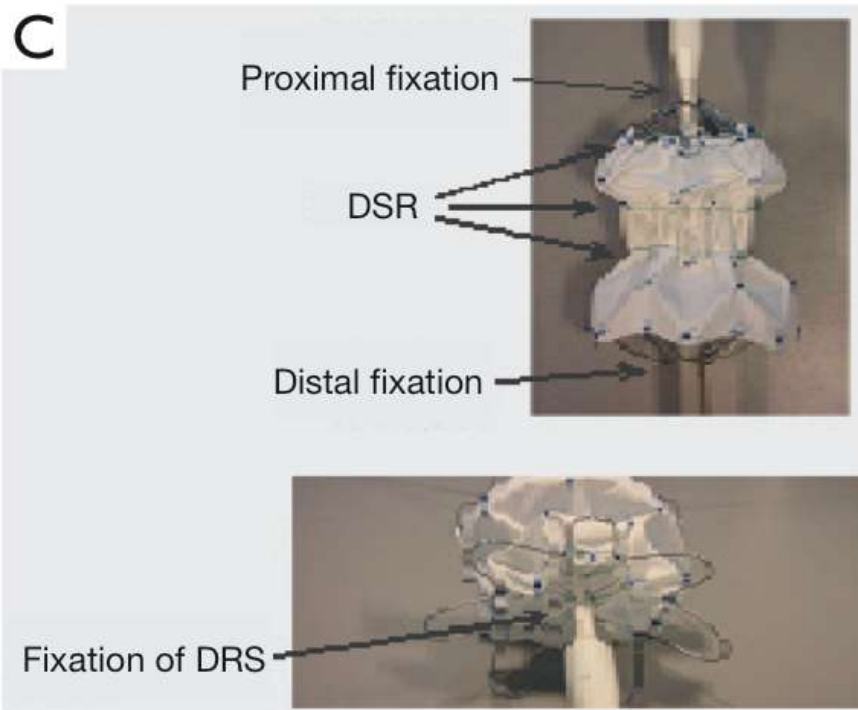




The GORE® ASG is initially deployed to 50% diameter, at which point blood is flowing through and around the device. Positioning adjustments can be made at this stage

GORE Investigational Device

Proximal angulation control
Available diameter 31-45 mm, length 7 - 10 cm

Cook Ascend



Proximal and distal bare stents to aid
Fixation and conformability

From the Society for Vascular Surgery

A systematic review of primary endovascular repair of the ascending aorta



Corbin E. Muetterties, MD,^a Rohan Menon, BS,^b and Grayson H. Wheatley III, MD,^c Philadelphia, Pa; Washington, D.C.; and Nashville, Tenn

- 118 patients treated from Jan 1995 to Jan 2017
- Indications:
 - Type A dissection 50%
 - Aortic Pseudoaneurysm 29.7%
 - Aortic aneurysm 5.1%
 - PAU 4.2%
 - Aortic rupture 2.5%
- Access:
 - Femoral 62.7%
 - Trans-apical 14.4%
 - Carotid 12.7%
 - Axillary 6.8%

Aortic Disease treated by Device type

Device category	No. of patients (%)	Aortic dissection	Pseudoaneurysm	PAU	IMH	Aortic aneurysm	Aortic rupture	Other
Thoracic stent	84 (71.2)	42	20	5	3	6	2	6
Custom-made stent	12 (10.2)	8	3	0	0	0	1	0
Abdominal cuff	13 (11)	2	10	0	0	0	0	1
Unknown stent	8 (6.8)	7	1	0	0	0	0	0
Thoracic cuff	1 (0.9)	0	1	0	0	0	0	0
Total	N = 118	59 (50%)	35 (29.7%)	5 (4.2%)	3 (2.5%)	6 (5.1%)	3 (2.5%)	7 (5.9%)

IMH, Intramural hematoma; PAU, penetrating atherosclerotic ulcer.

Complications

	No. (%)
Endoleaks	22 (18.6)
Reintervention	11 (9.3)
Nonaortic deaths	12 (10.2)
Aortic deaths	6 (5)
Open conversion	4 (3.4)
Stent migration	2 (1.7)
Postoperative myocardial infarction	4 (3.4)
Stroke	4 (3.4)
Device deployment failure	3 (2.5)
Other	11 (9.3)
Free of complications	71 (60.2)
Free of aorta-related complications	79 (67)

Results:

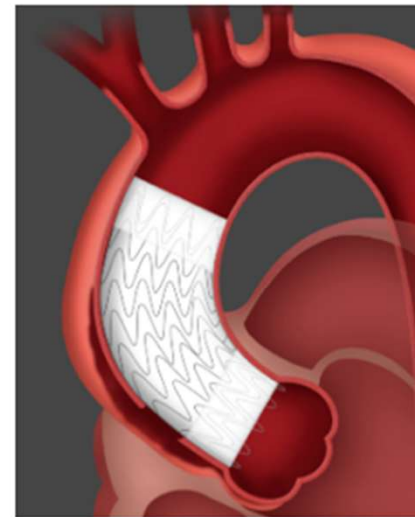
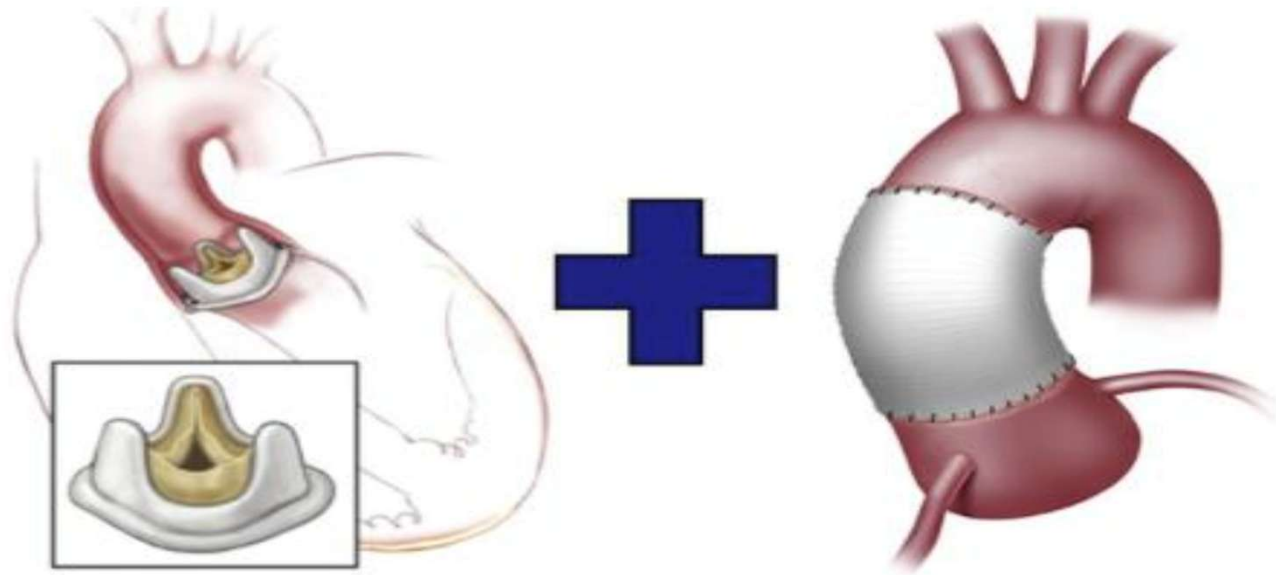
Aorta-related mortality 5%, all-cause mortality 15.2%,

Open conversion 3.4%, CVA 3.4%

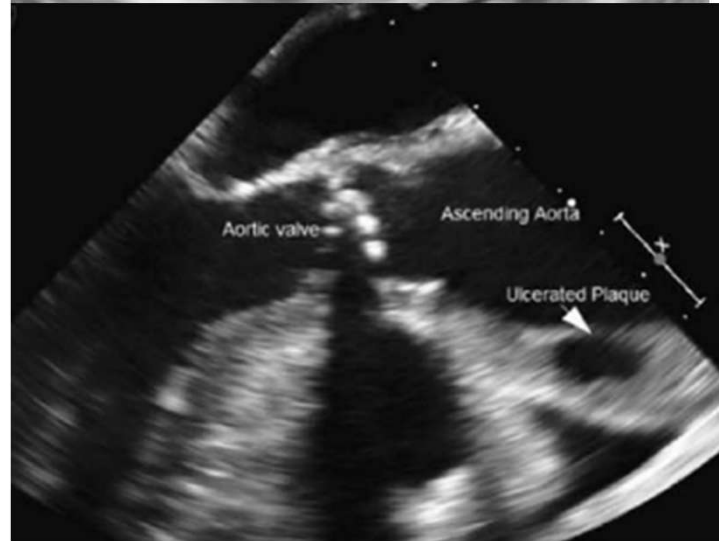
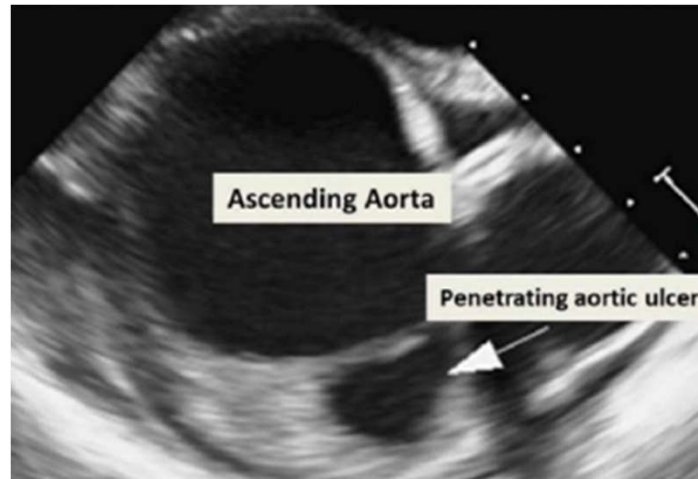
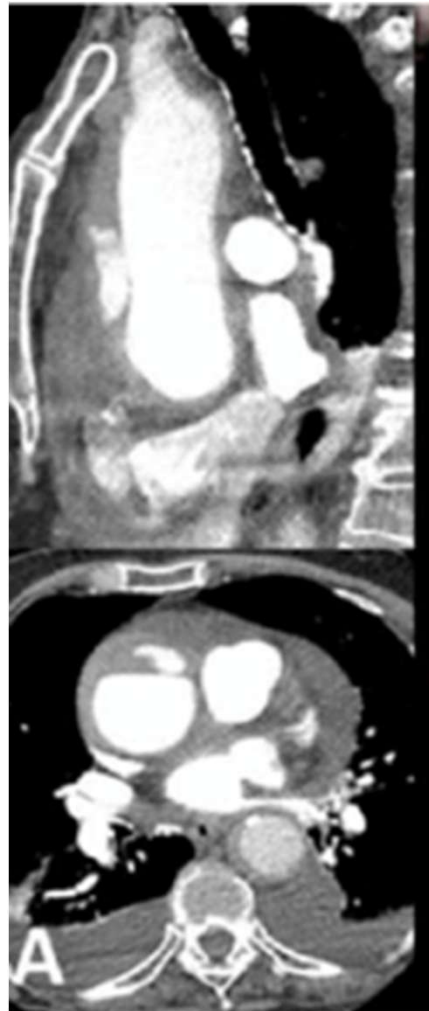
Type 1 endoleak 18.6%, Reintervention 9.3%

Mean follow up 17.2 months

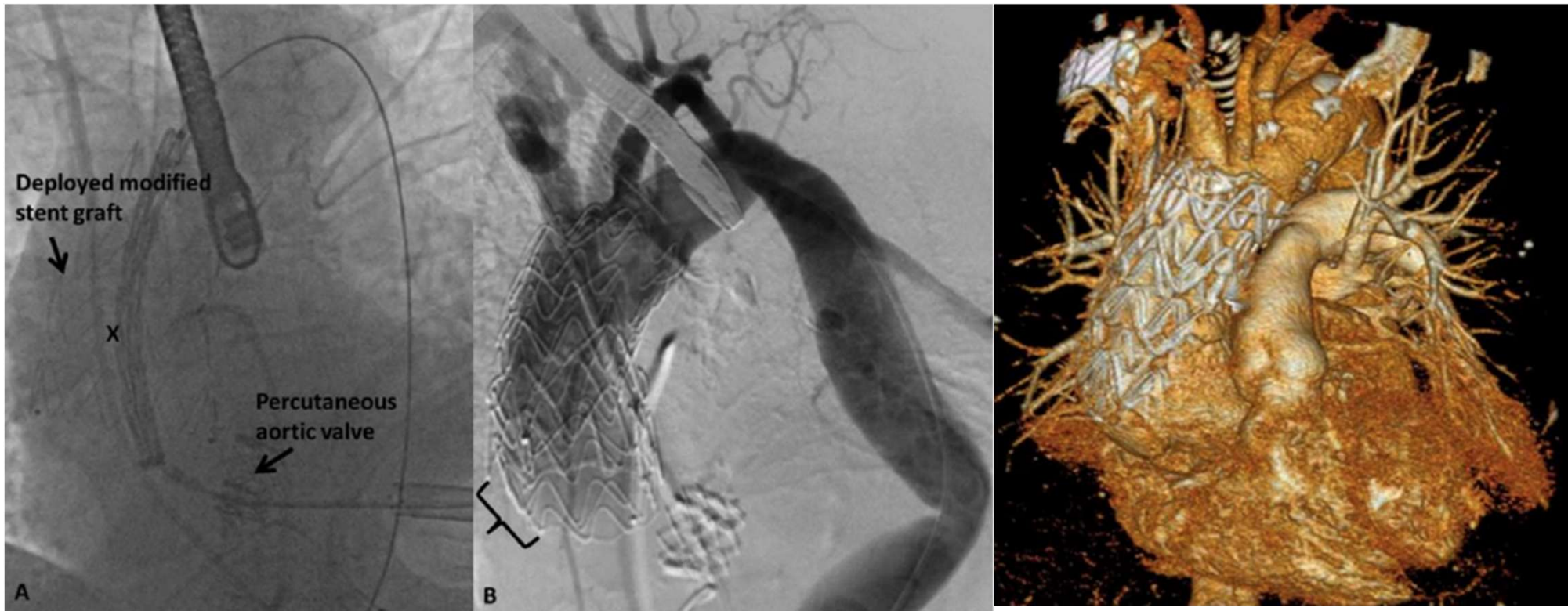Wheat procedure



Combined TAVR/TEVAR: Endo-Wheat

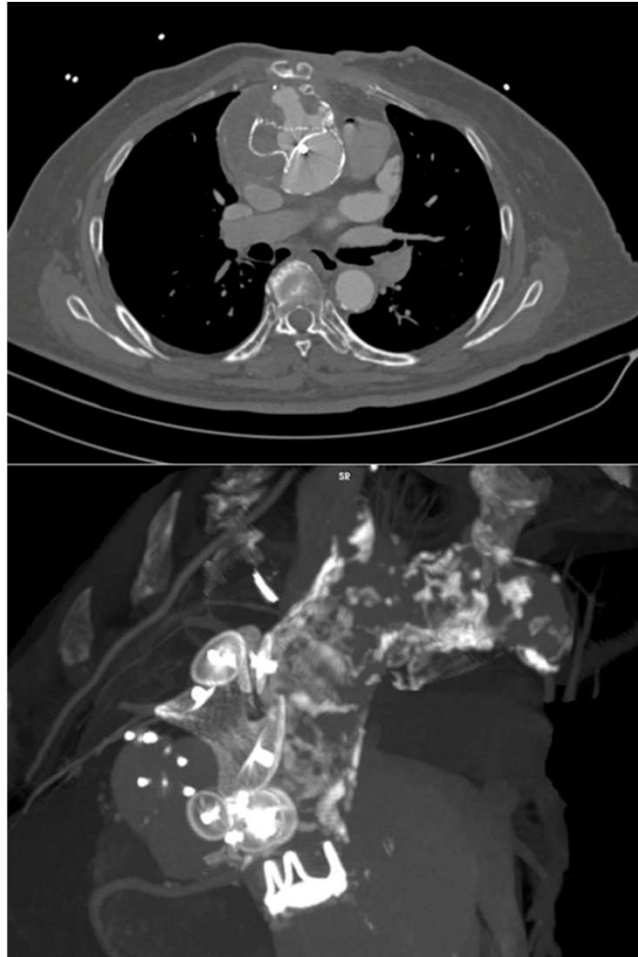


88 yo female presented with PAU, critical AS and pericardial tamponade



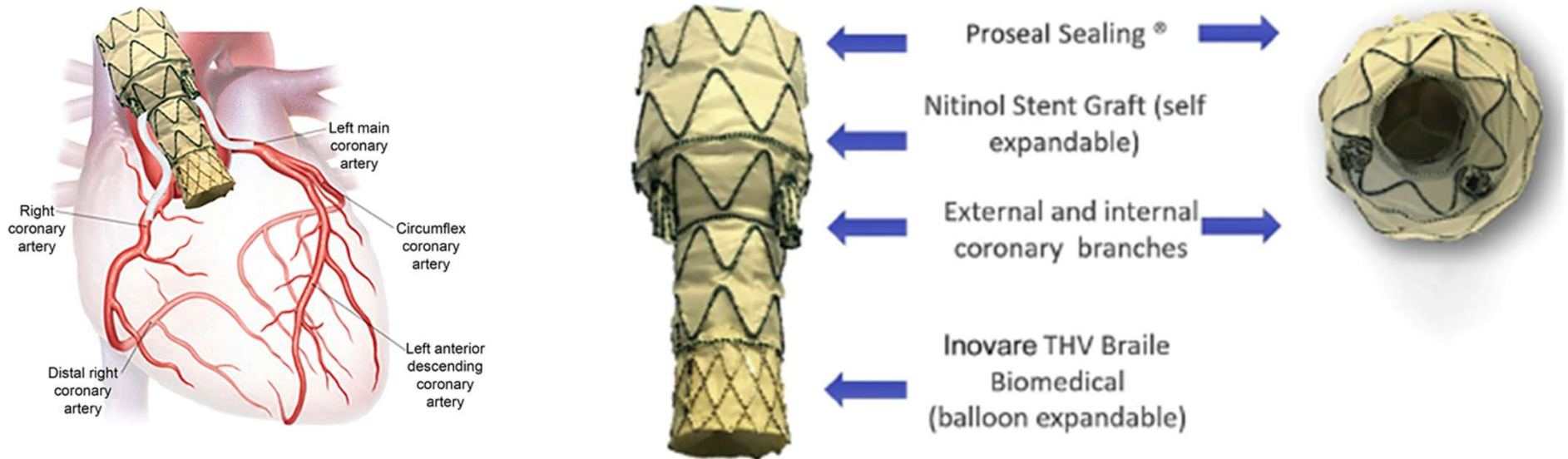
Procedure: 23 mm Balloon expandable valve, followed by Gore CTAG 45 mm x 10 cm stent graft
First reported single stage TAVR/TEVAR via trans-apical access

First In-Human Endo-Bentall



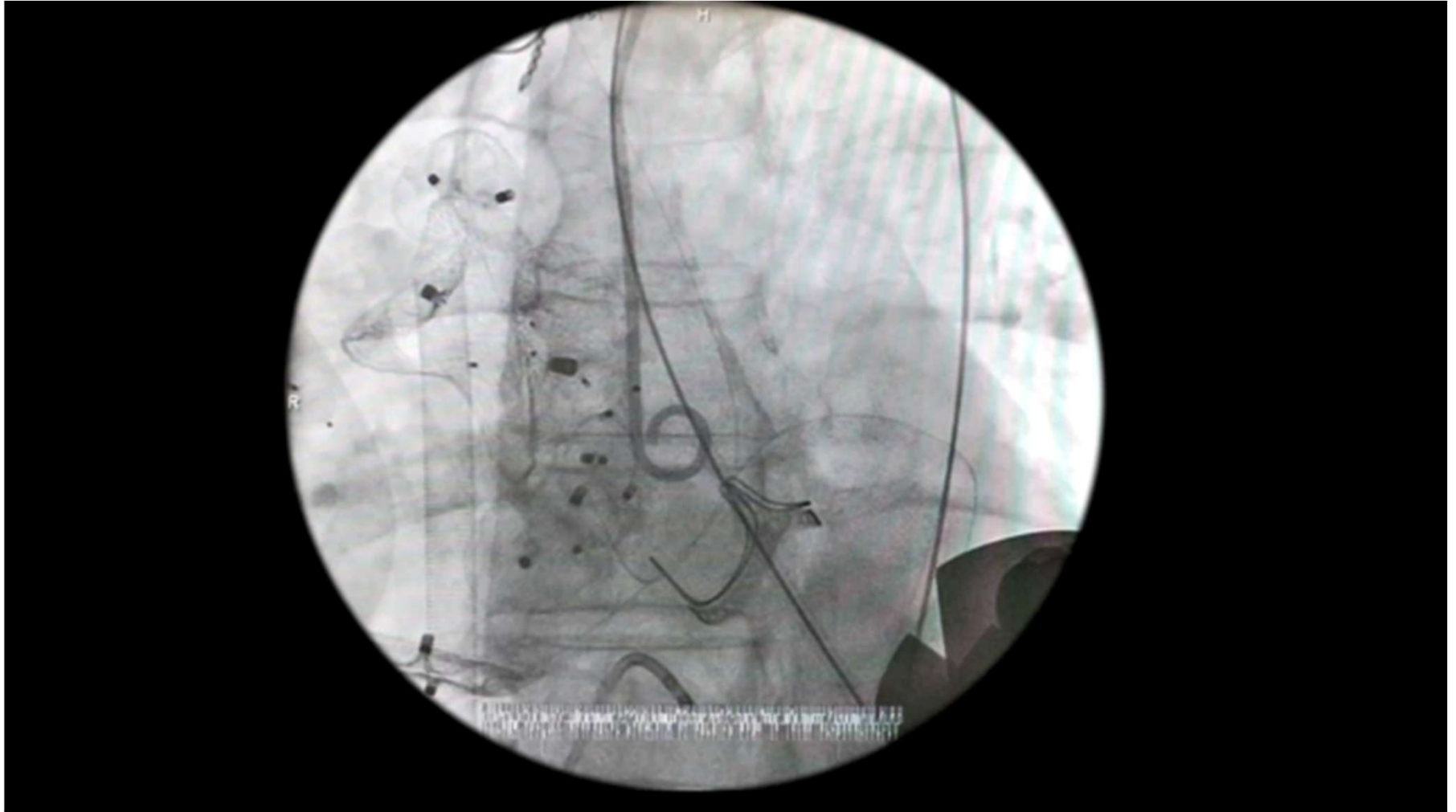
64 yo female post AVR in 2014 with 23 mm Pericardial valve with PSA at aortic suture line and fistula to skin, unsuccessful percutaneous closure w 7 vascular occluders, with porcelain aorta, AVR degeneration MG 28.5; EuroSCORE 28.5%

Endo-Bentall Prosthesis

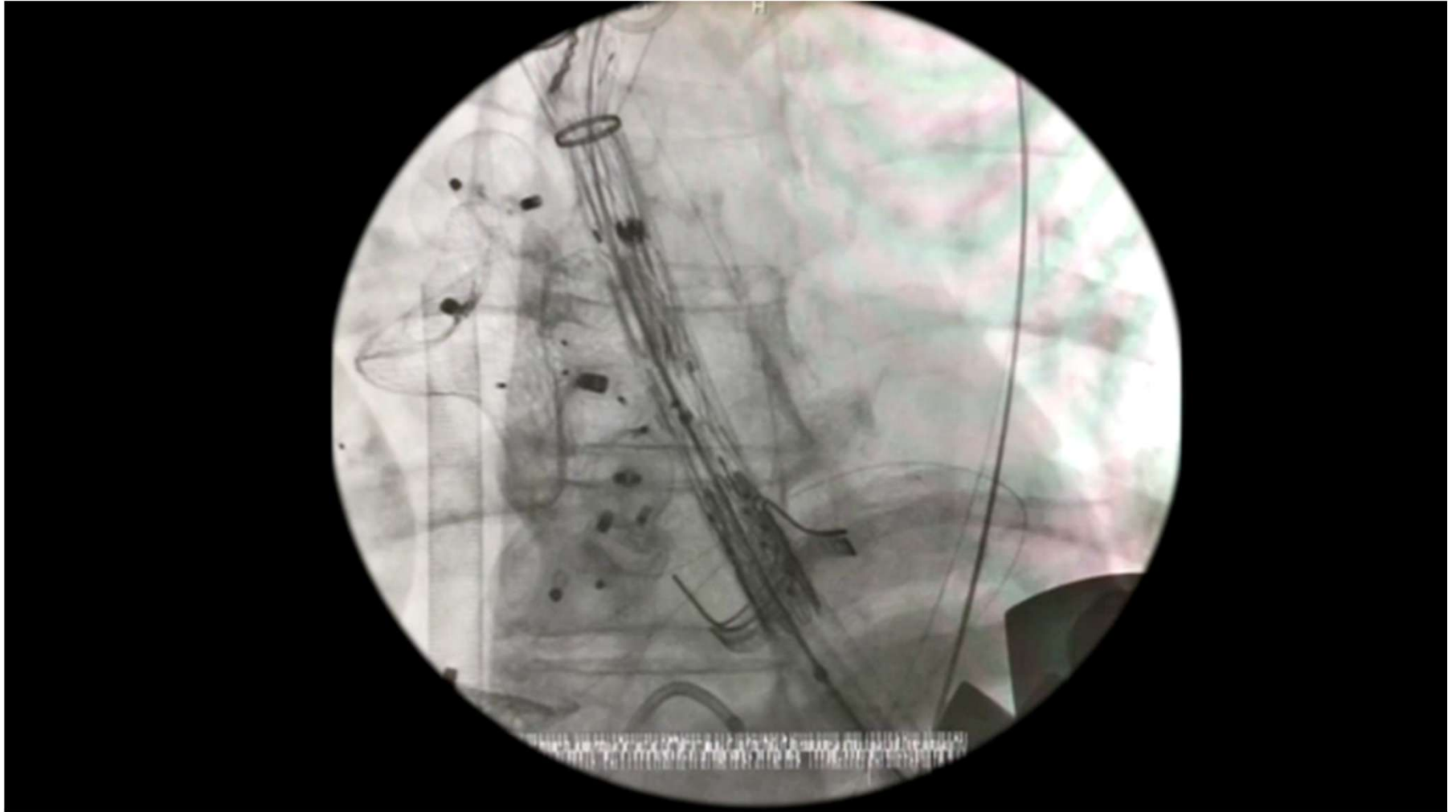


- Pt with PSA defect 6 mm below STJ near non-coronary sinus
- Custom made device, Balloon expandable TAVR valve (22 mm Braile Inovare) attached to self-expandable 40 mm diameter aortic stent with coronary artery branches 2 cm from ostia after aortic stent deployment
- Following deployment of endoprosthesis via trans-apical approach, coronary arteries were treated with bridging covered stents with ECMO support

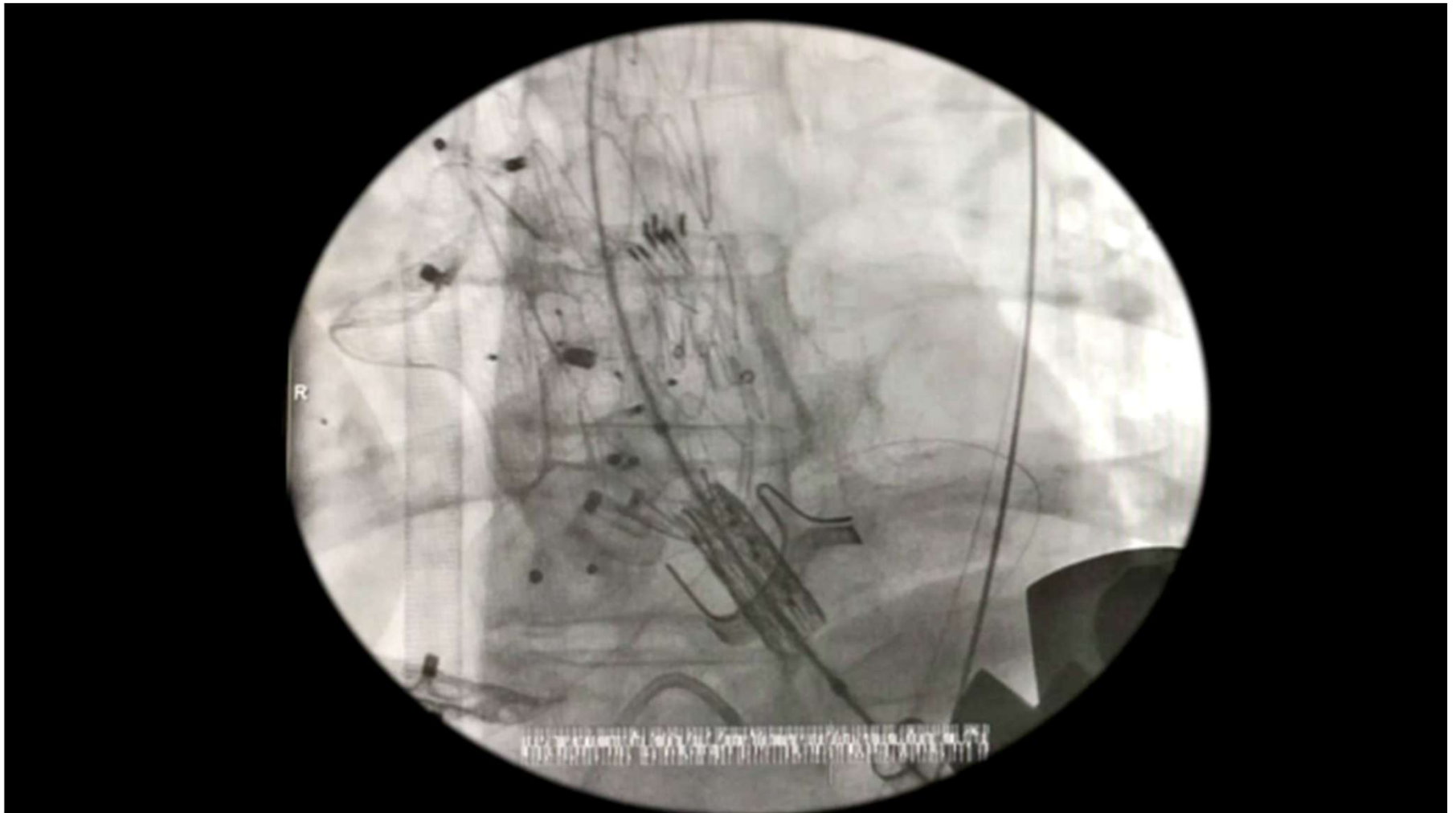
Pre-Intervention



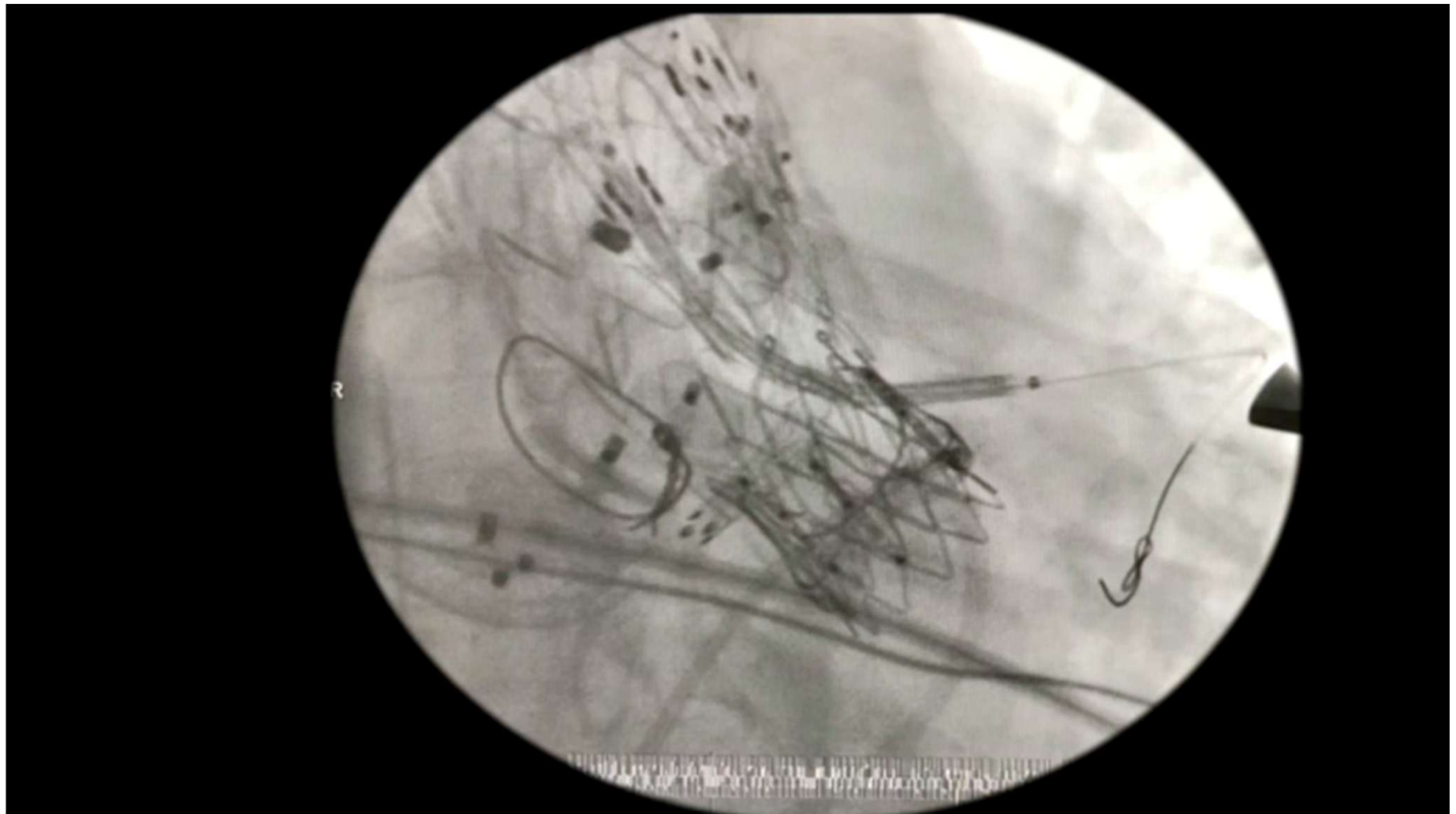
Endo-prosthesis Deployment



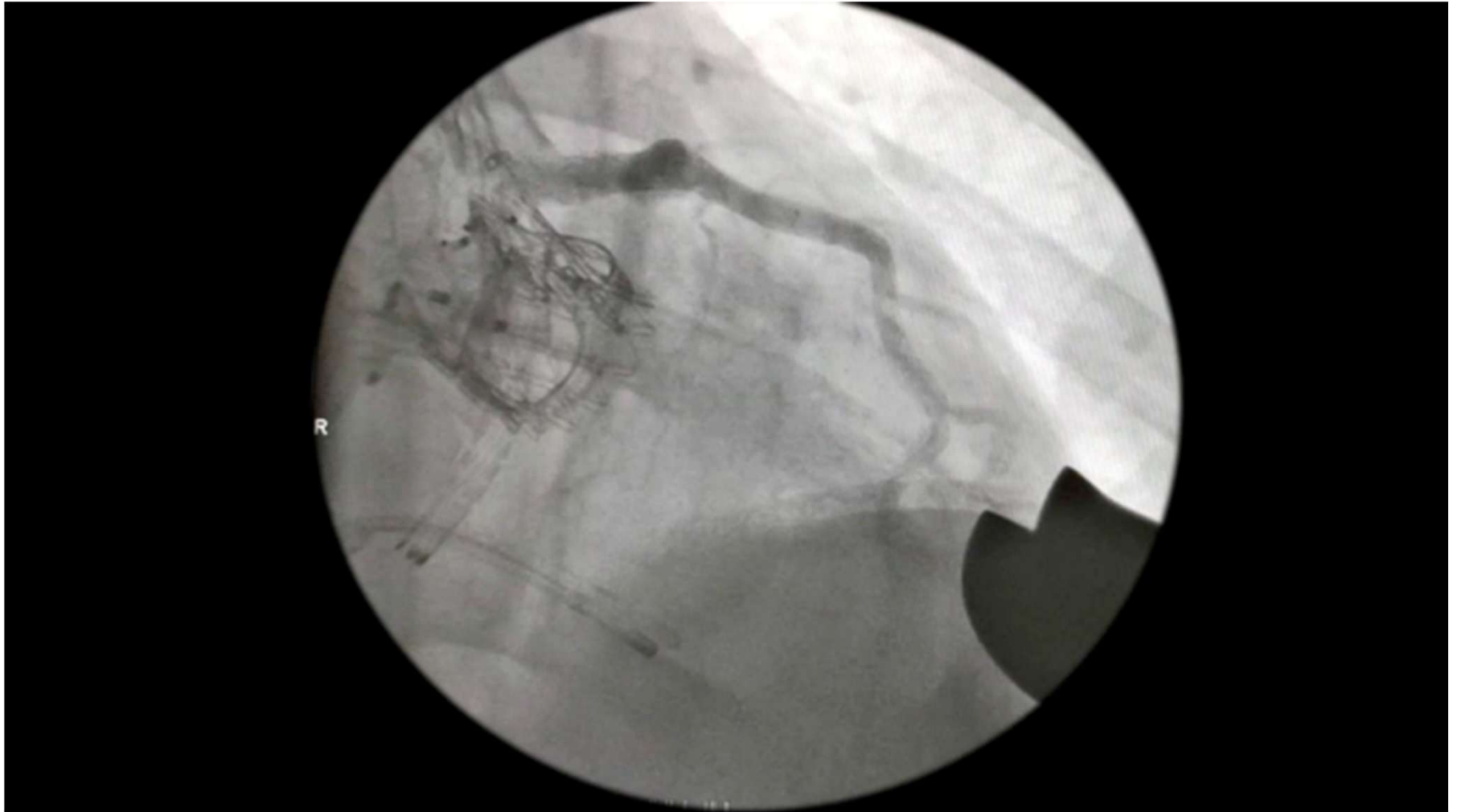
TAVR Valve-in-Valve



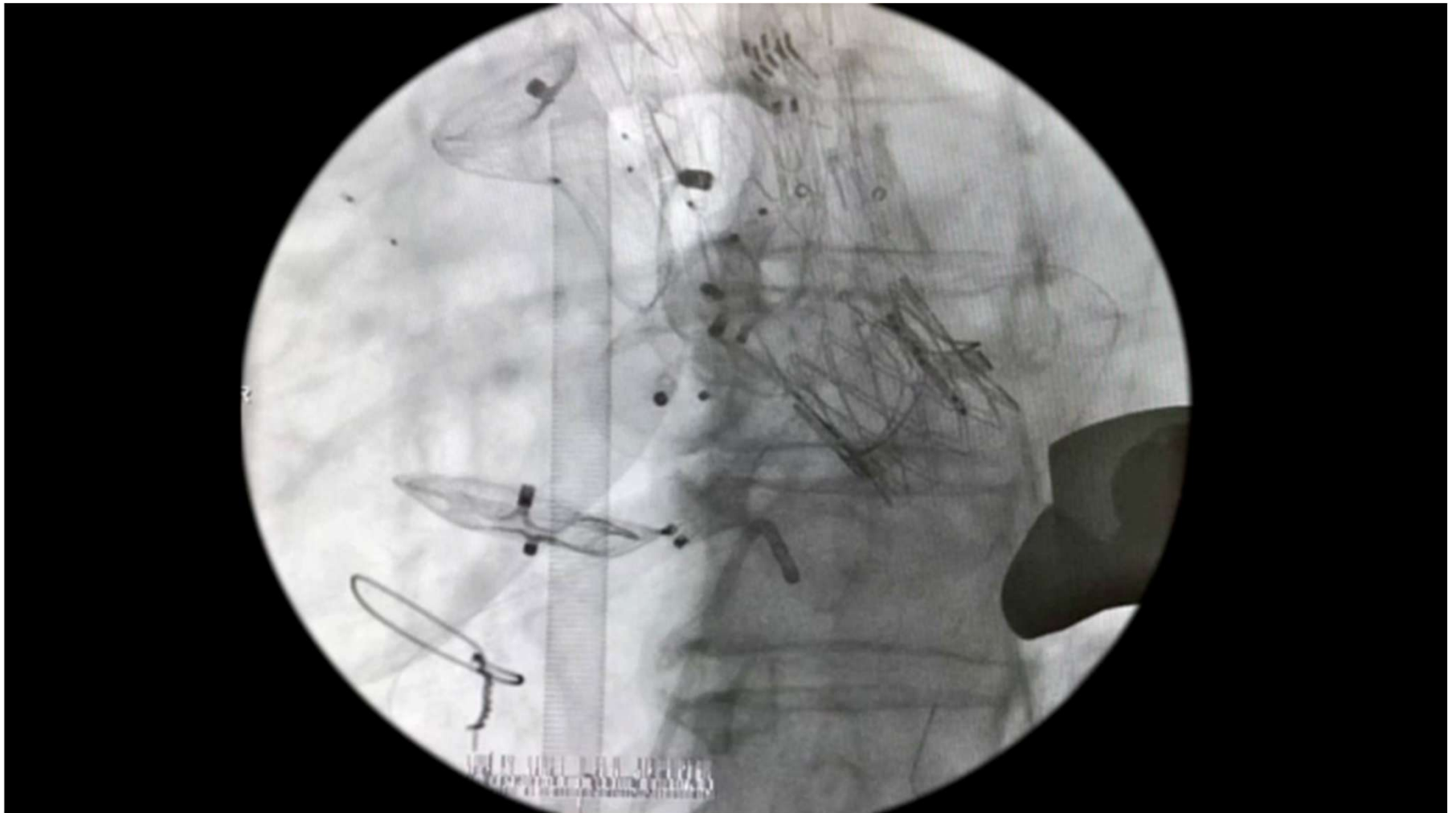
L Main stent



LCA angiogram

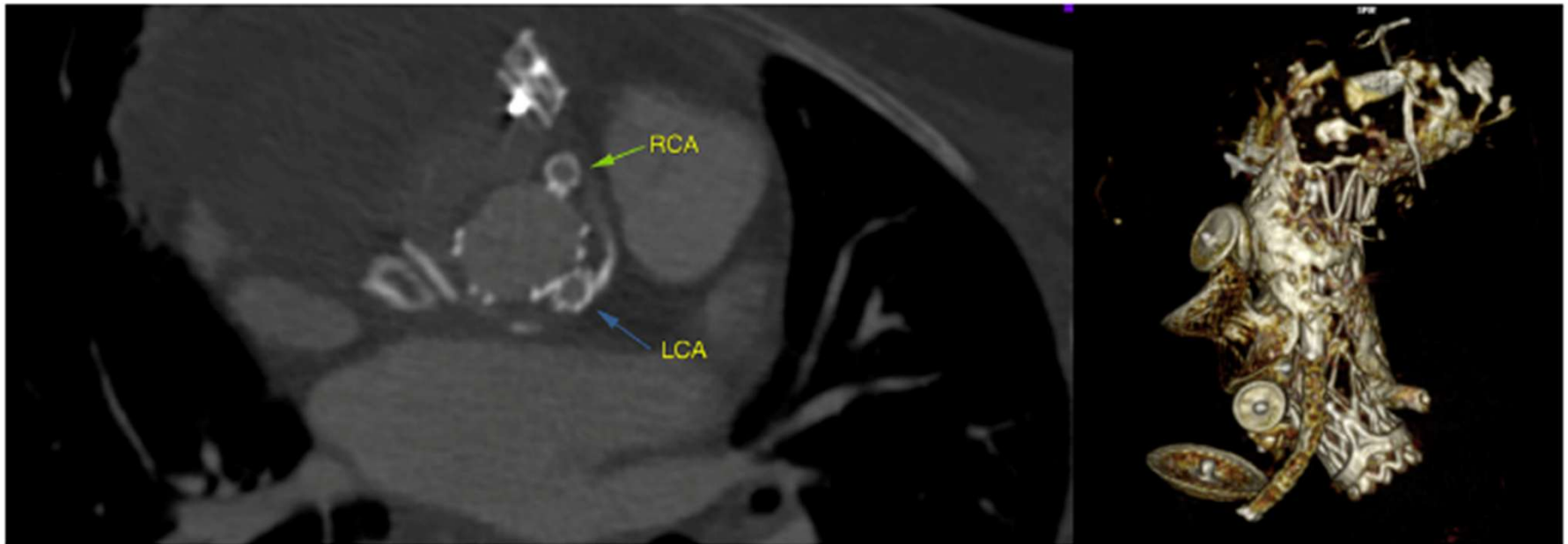


RCA stent angiogram



Total procedure time 390 minutes, discharge POD 7 without complications

4-month CT

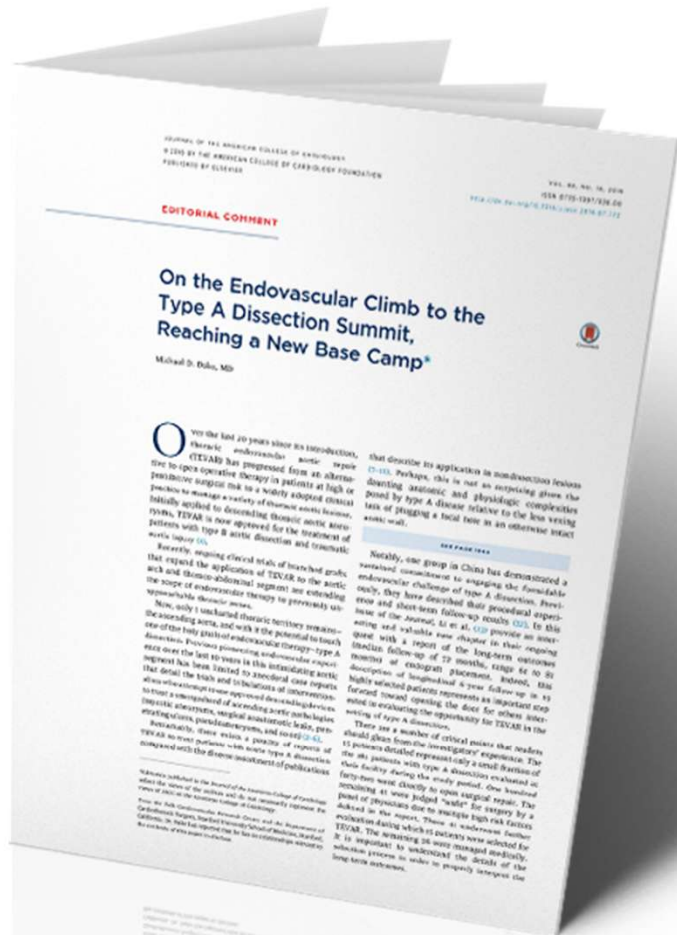


Right and left coronary stents are patent. Additionally, the pseudoaneurysm is fully excluded without endoleaks. Finally, the prosthesis is reconstructed in 3 dimensions. Left main = left coronary connection stent (**blue arrow**); RCA = right coronary artery connection stent (**green arrow**).

Pt alive at 9 months without MI or symptoms

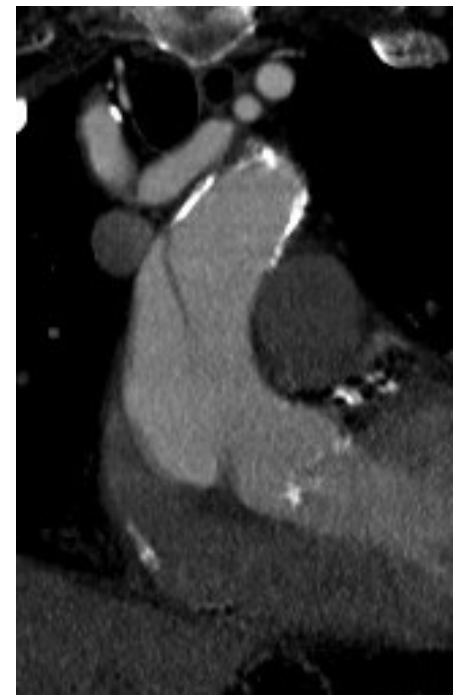
On the Endovascular Climb to the Type A Dissection Summit, Reaching a New Base Camp

- ...beyond the novelty level of “look, it can be done” to the next developmental stage, poised on the threshold of a prospective clinical trial.



Endovascular Ascending Repair

- Technically feasible
- Rapidly evolving technology
- Tailor the therapy to the patient risk profile, anatomy, expertise, and available technology
- Highly skilled multi-disciplinary team
- Significant opportunities for innovation
 - Conformable, tapered elastic devices
 - Steerable, repositionable system
 - TAVR-TEVAR valve-conduit devices with coronary branches for aortic root pathology

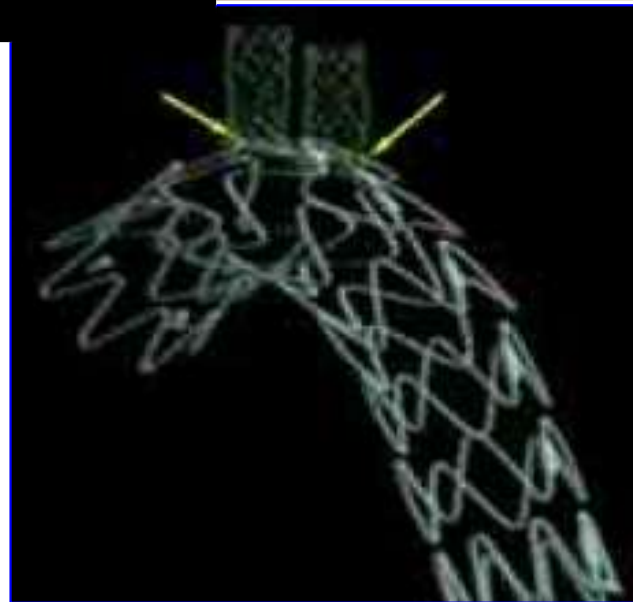

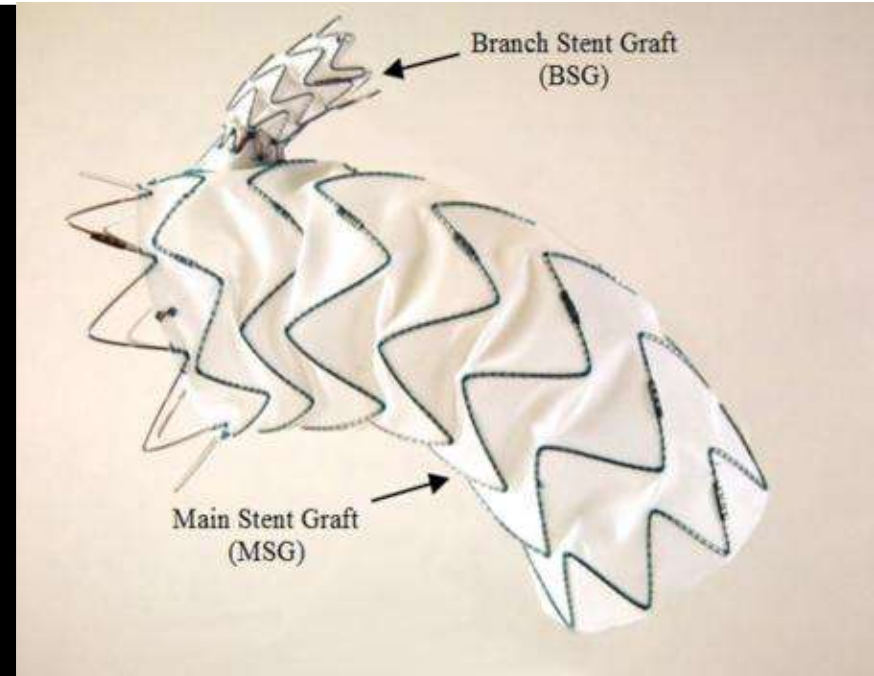
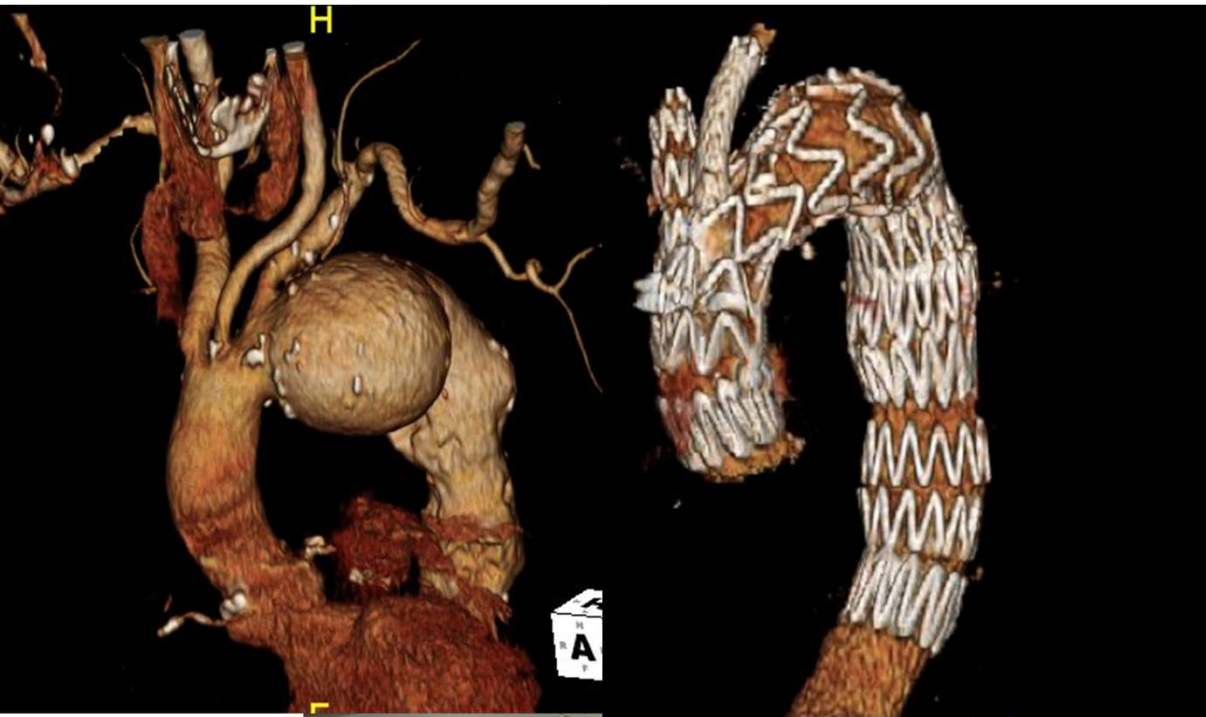


Thank You



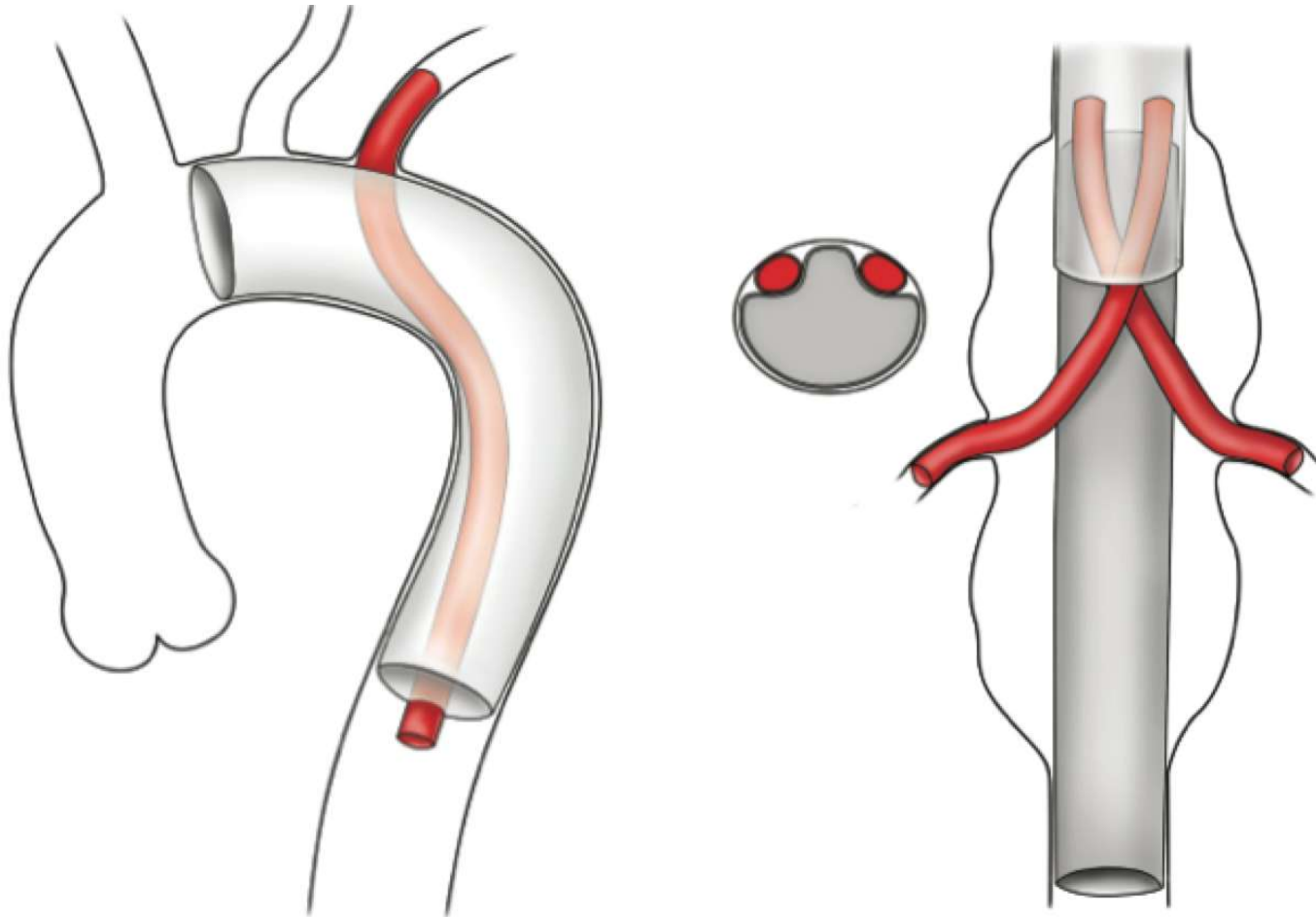


Branched vessel/fenestrated technology



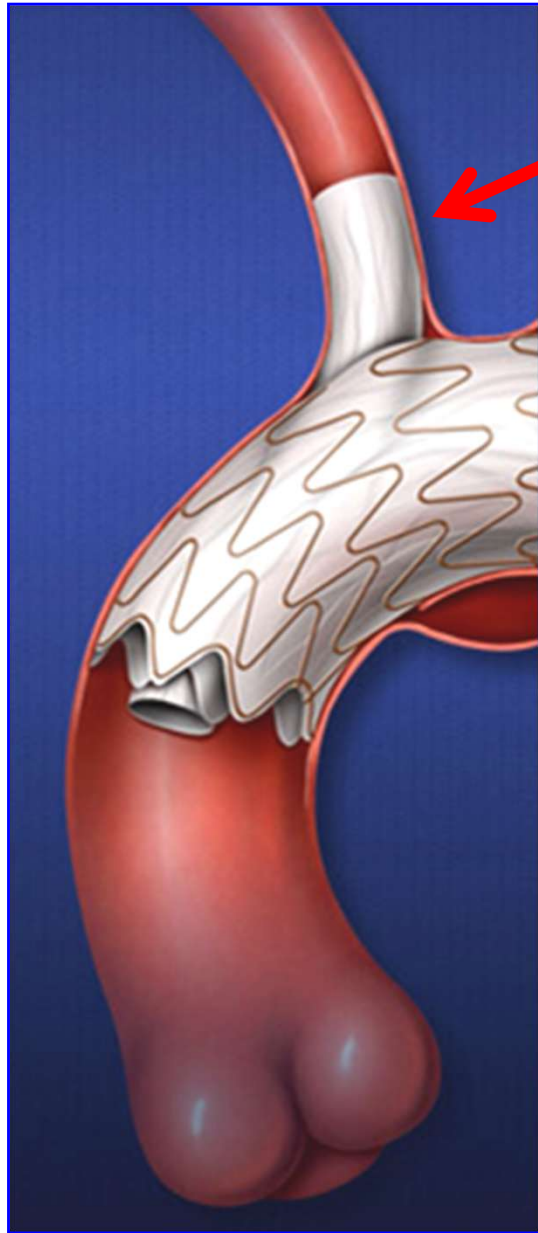
Terminology

- “Parallel graft” (PG) is all-encompassing term for chimneys, snorkels, periscopes...



Technical Aspects

- Over-sizing of aortic stent graft by 20%
- Either self-expanding or balloon-expandable stents for parallel stents
 - Self-expanding increased conformability
 - Balloon-expandable more accurate deployment, increased radial force
 - No demonstrated superiority of either
- Kissing balloon deployment



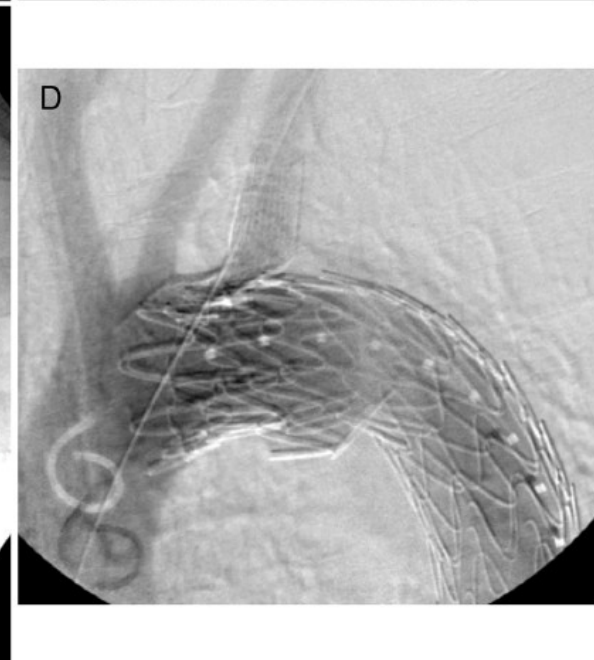
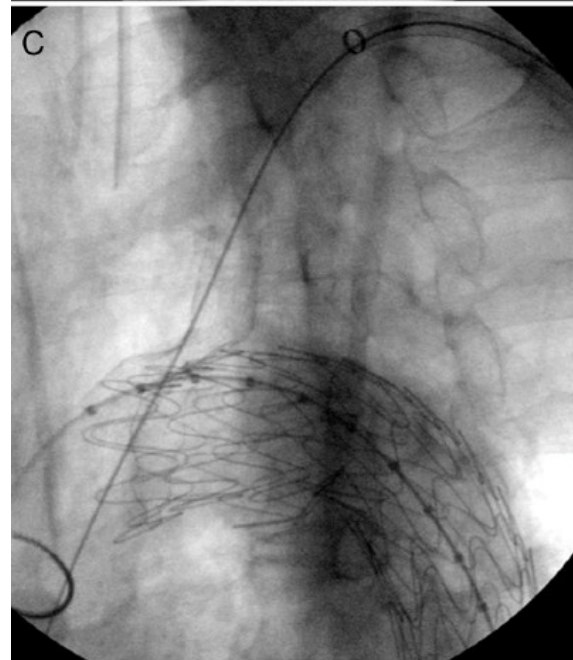
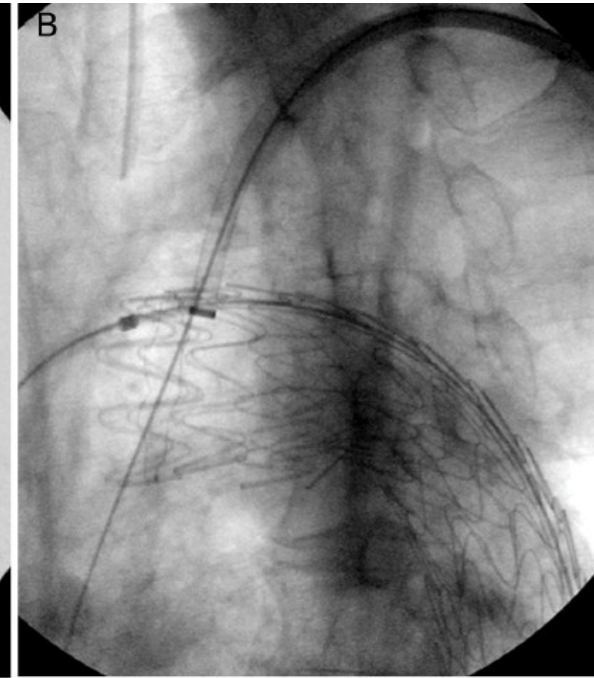
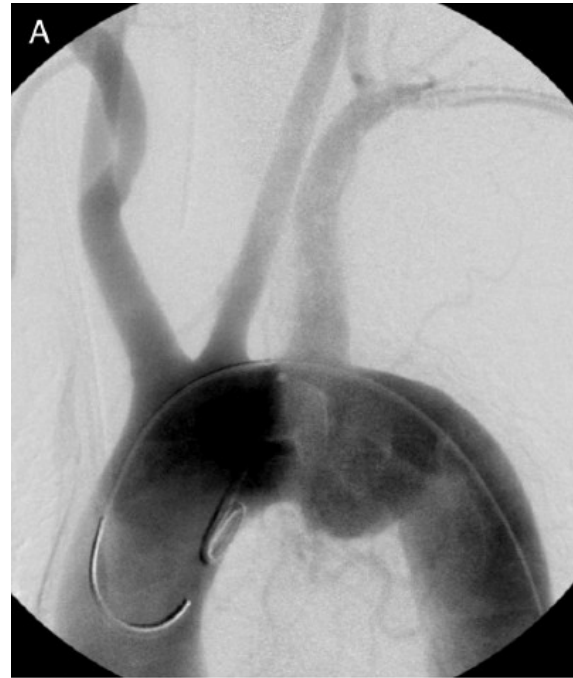Innominate PG

**“It works better
than it should!”**

Frank Veith

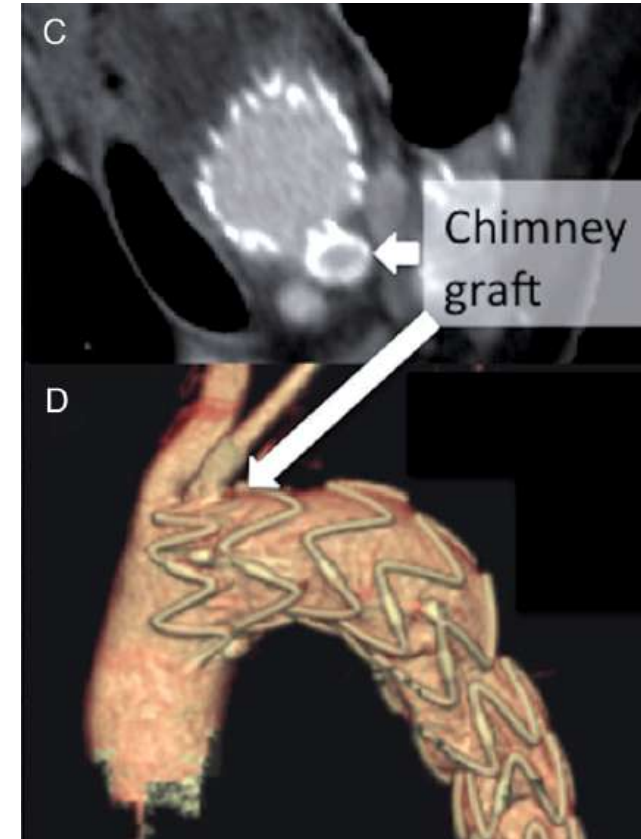
Parallel Graft in the Aortic Arch

- 72yo pt, emphysema pre-lung transplant, 4.8cm pseudoaneurysm
- Left brachial access
- 12 F delivery sheath
- choice of chimney stent
 - 20% Over-sizing of TEVAR
- kissing deployment



PG in the Aortic Arch: Outcome

- 94 pts, 101 chimney stent grafts
- Path: 1/3 aneurysm, 1/3 dissection
Emergent 28%
- 3.2% early mortality, CVA 5.3%
 - 18% endoleak, Type Ia 6.4%
- 100% patency, 8.5% mortality at 11 mo
- Innom A- 44% complications
(CVA plus endoleak)
- L CCA- 22% complications
- L SA- 0% complications



Parallel Grafts

PROS

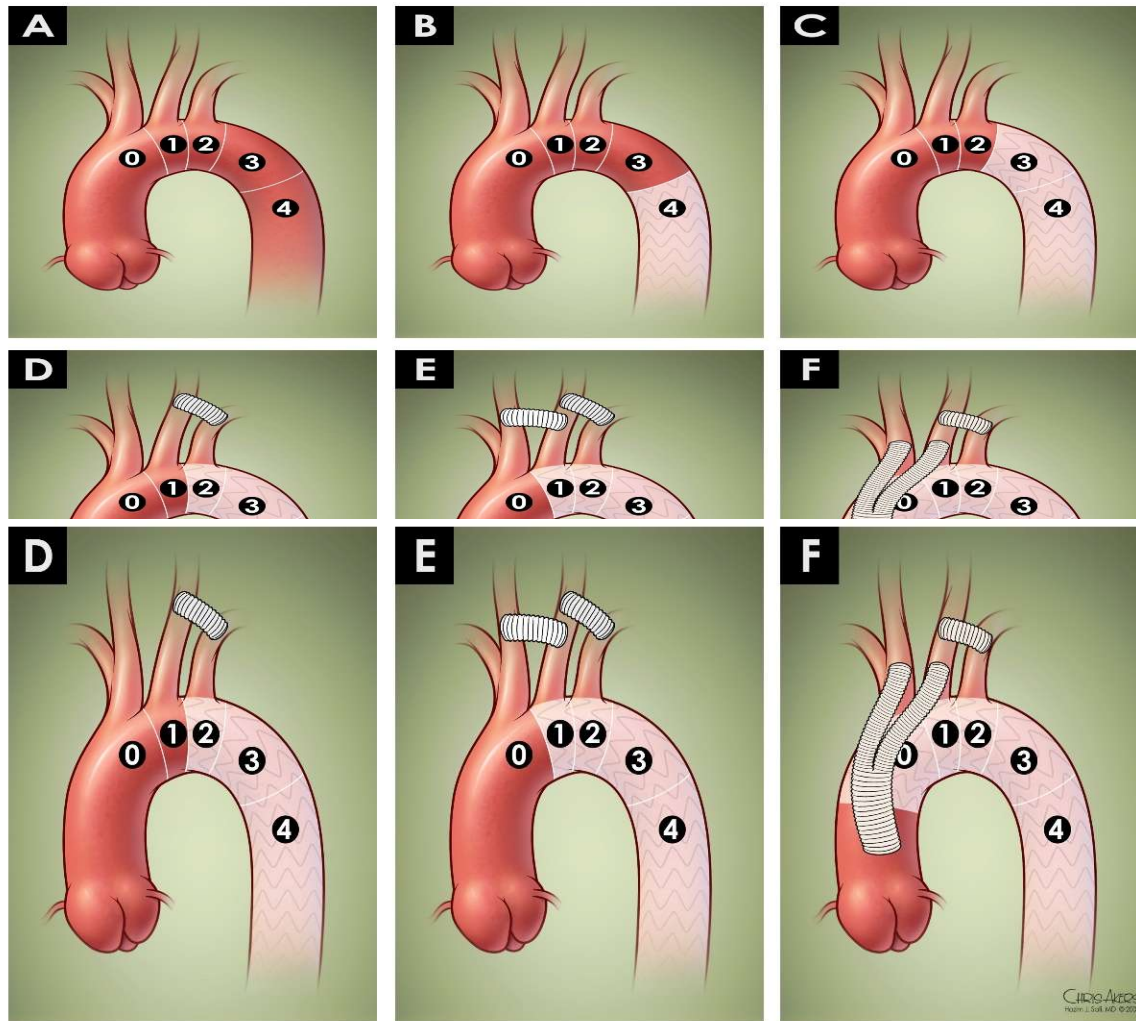
- percutaneous access (mostly)
- bail-out/rescue
- readily available (off-the-shelf)
- seem to work in most cases

CONS

- potential for type I endoleak
- stent/endograft interaction
 - uncertain long-term results
- Worse outcome compared to hybrid TEVAR



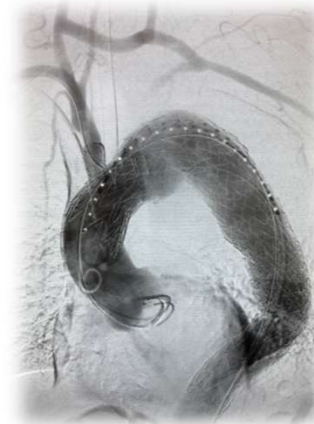
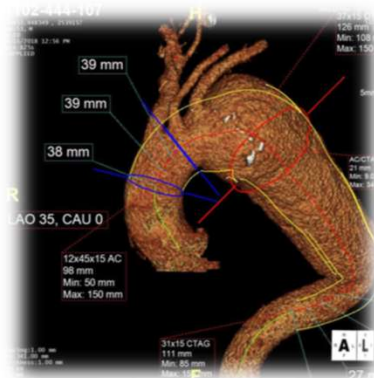
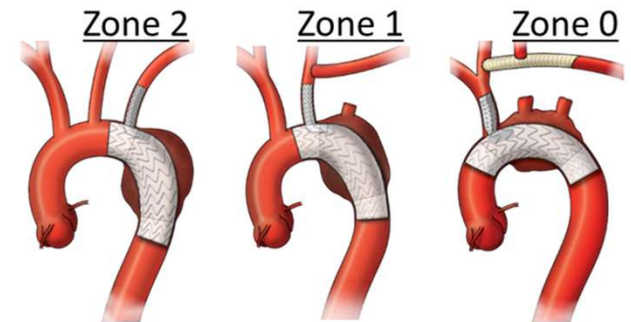
Using hybrid aortic arch replacement, most of the arch and descending aorta can be replaced without need of sternotomy or heart-lung machine



Research: GORE TBE

Received IRB approval
for the Gore TBE
investigational device
research protocol

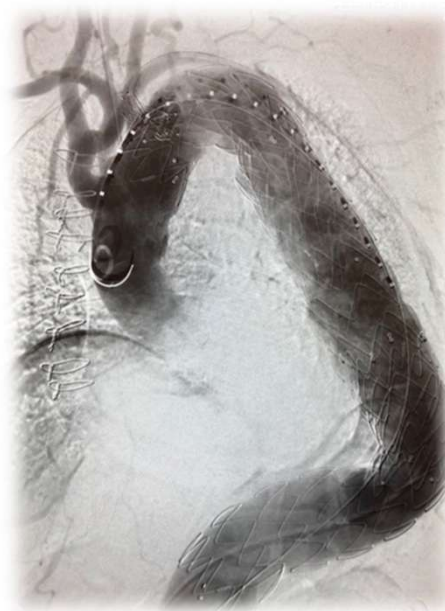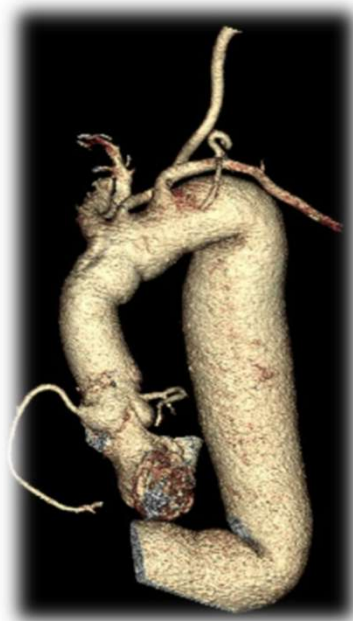Screened: 13
Enrolled: 6



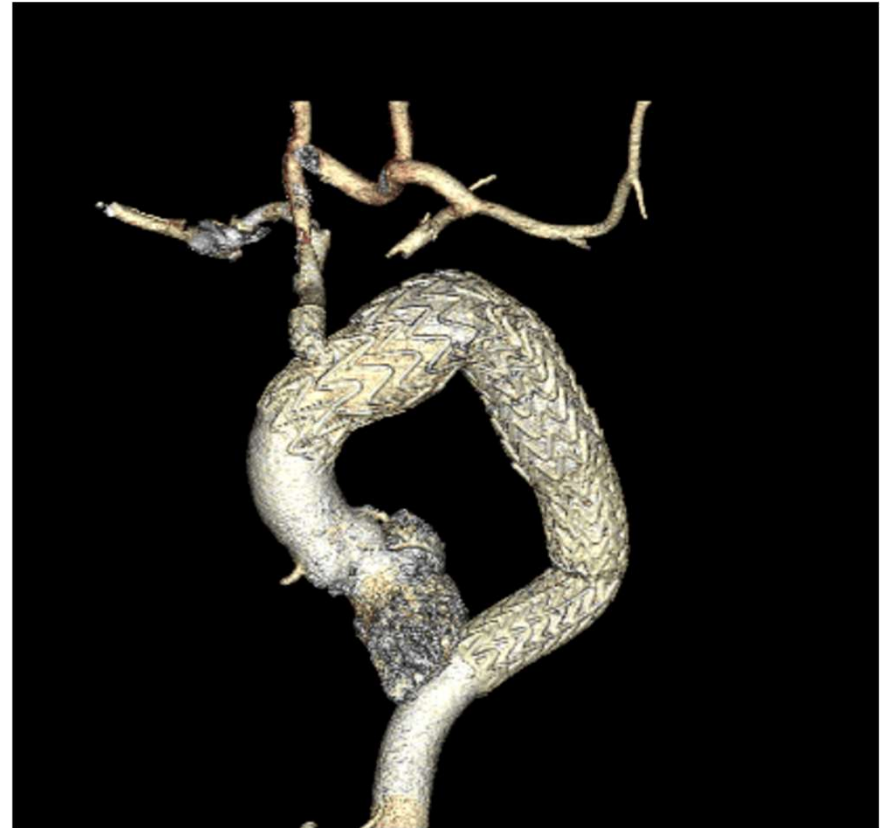
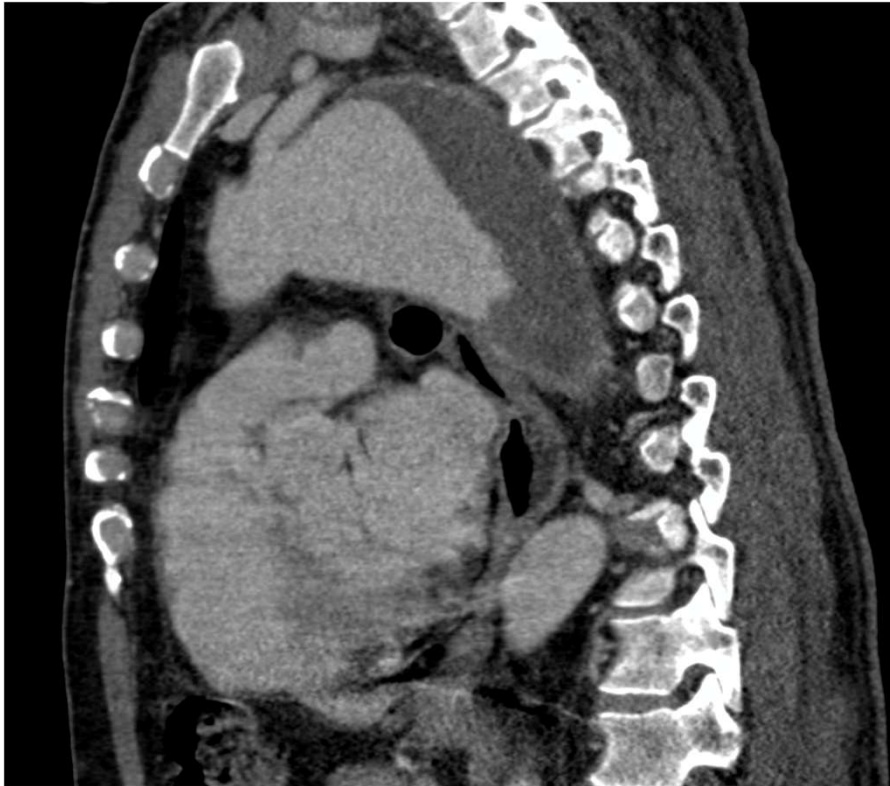
Research: Valiant Mona LSA

Received IRB approval
for the Valiant Mona
LSA investigational
device research
protocol

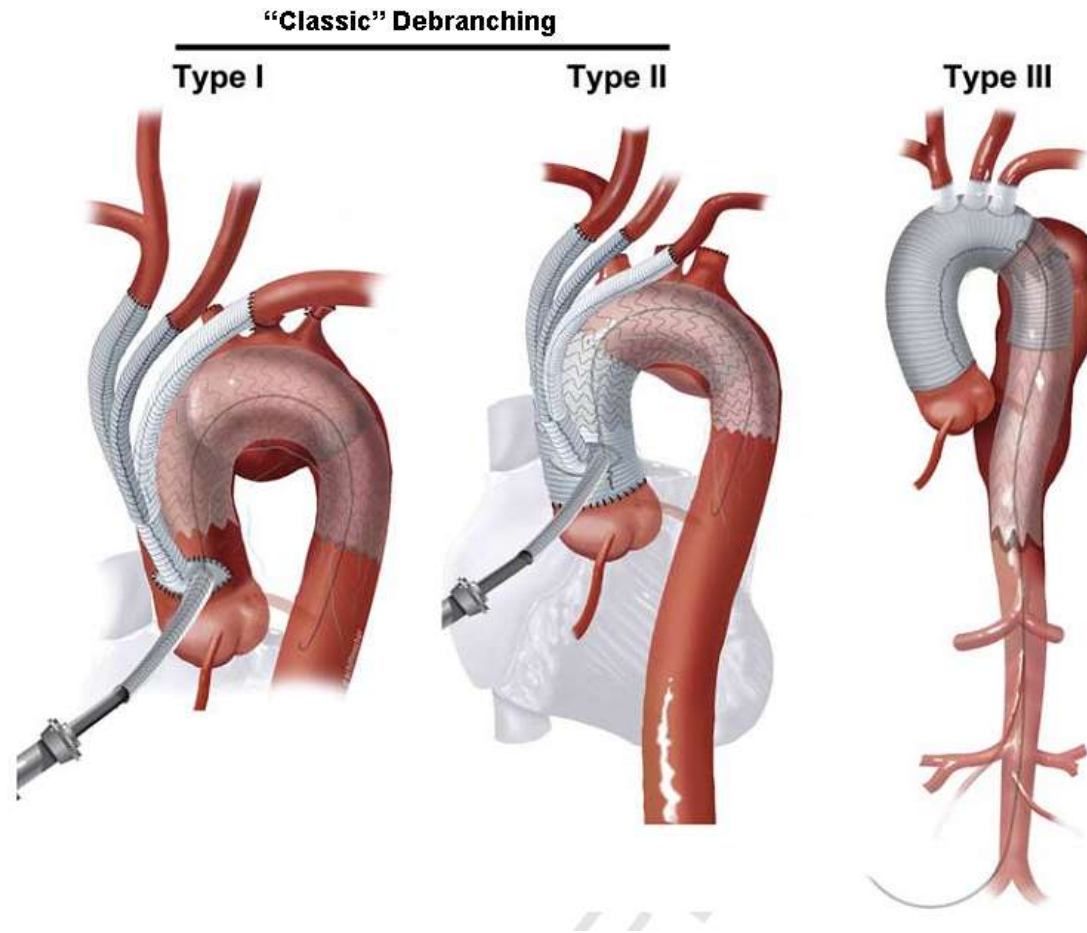
Screened: 3
Enrolled: 1



Arch Debranch with Zone 0 TEVAR



Hybrid aortic arch replacement



Type I: Zone 0 TEVAR with arch debranching; require asc aorta diam < 38 mm

Type II: Replace asc aorta to create proximal landing zone TEVAR zone 0

Type III: Acs/Total arch replacement with elephant trunk

Conventional Arch Replacement vs Hybrid

Bavaria et al, JTCVS 2010;140:590-7

	Hybrid		Open total arch		P
	N = 27		N = 45		value
In-hospital mortality	3	11%	7	16%	.739
Stroke	1	4%	4	9%	.644
Transient neurologic deficit	0		5	11%	.15
Permanent paraplegia	2	7%	0		.137
Reversed spinal cord ischemia	3	11%	0		.049
renal failure	5	19%	5	11%	.486
Renal failure requiring new hemodialysis	3	11%	3	7%	.665
Reoperation for bleeding	0		1	2%	1.00
Afibrillation	9	33%	13	29%	.793
Mean hospital stay (d)	20.1	15.9	17.5	16.2	

Age stratification and mortality

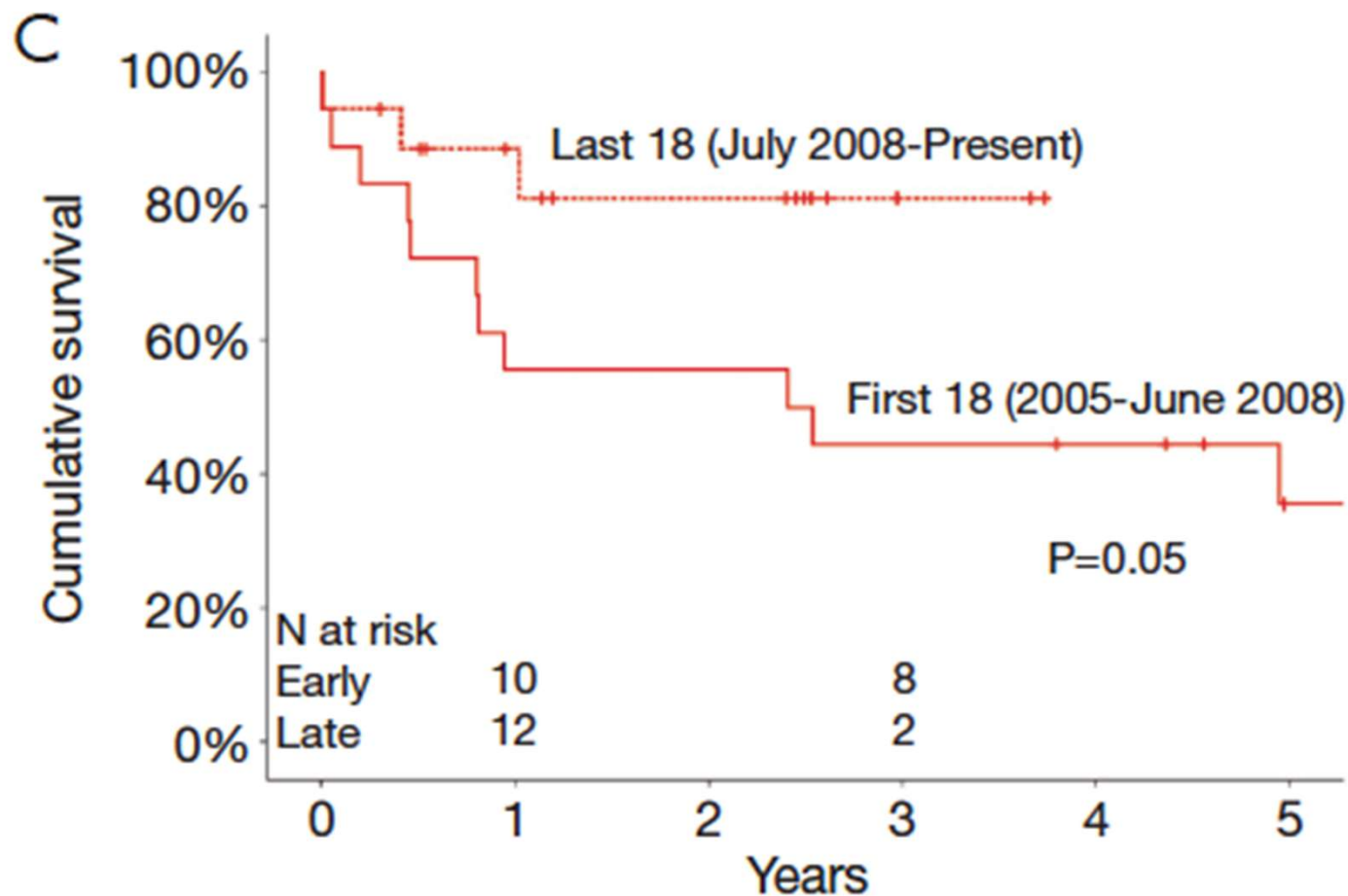
	In-hospital mortality			
	Hybrid arch		Open total arch	
<75 y	2	14%	3	9%
>75 y	1	8%	4	36%

Hybrid Type I/II Arch

Table 1 Patient demographics

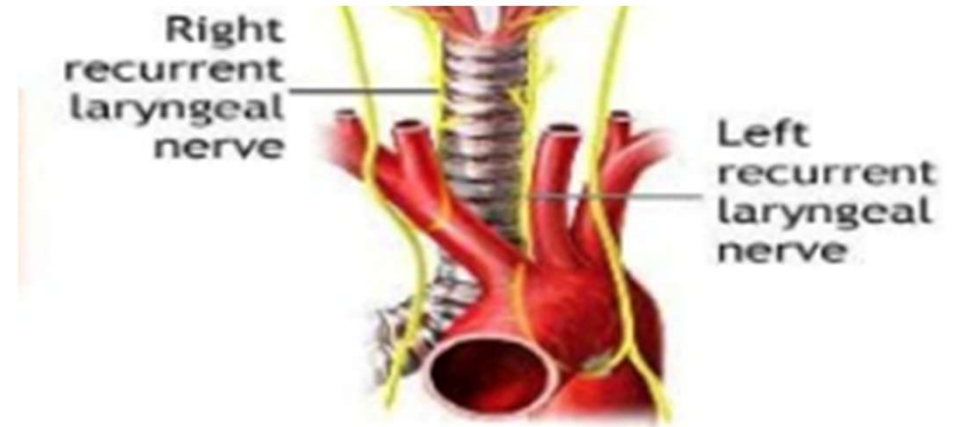
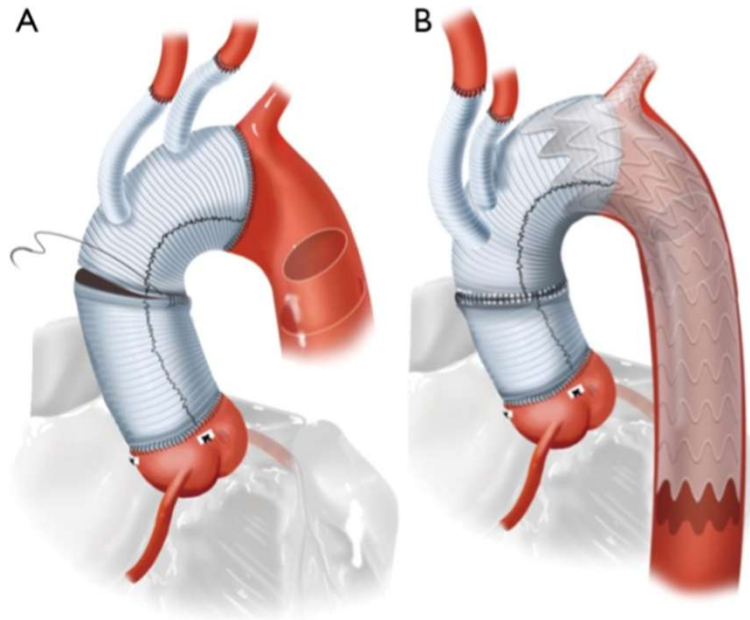
Preoperative characteristics	All hybrid	Type I	Type II
Number of patients	36	28	8
Age	70.7±8.0	69.3±7.5	71.1±8.3
Male gender (%)	23 (64%)	18 (64%)	5 (63%)
Prior cerebrovascular accident	15 (42%)	12 (43%)	3 (38%)
Chronic lung disease	14 (39%)	11 (39%)	3 (38%)
Prior myocardial infarction	12 (33%)	9 (32%)	3 (38%)
Chronic renal insufficiency	6 (17%)	6 (21%)	0 (0%)
Smoker (current or history)	29 (81%)	23 (82%)	6 (75%)
Aortic pathology			
Aneurysm	29 (81%)	25 (89%)	5 (63%)
Maximum diameter (mean, cm)	7.1±1.5	7.1±1.5	7.4±1.4
Chronic dissection	4 (11%)	1 (4%)	3 (38%)
Failure of prior TEVAR	1	1	
Pseudoaneurysm (post-traumatic transection)	2 (6%)	2 (7%)	

Outcomes for Hybrid Type I/II Arch



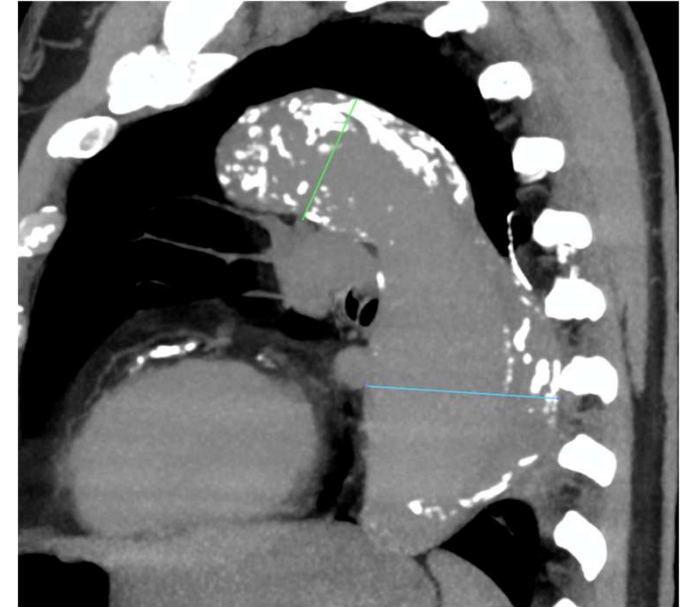
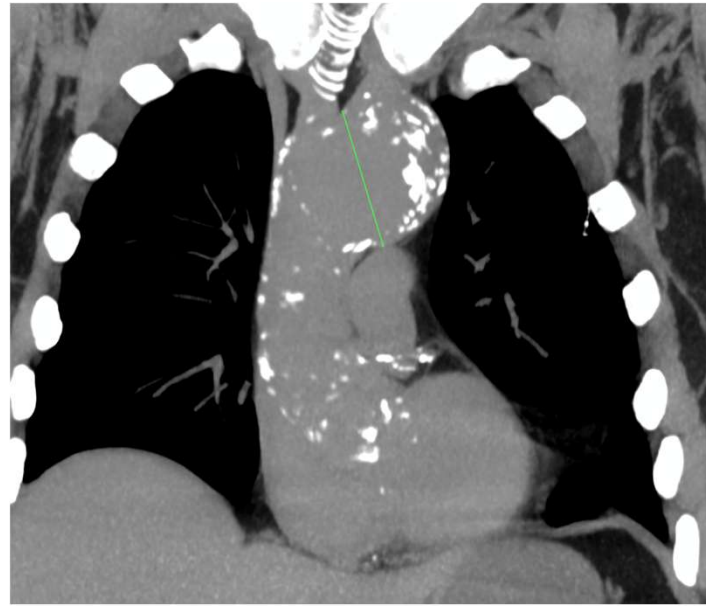
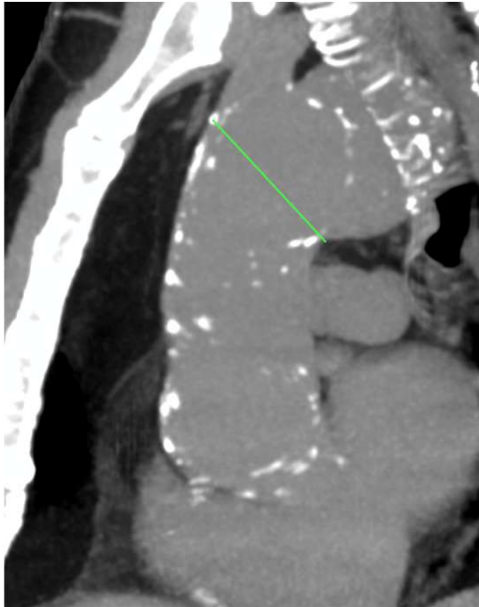Hospital mortality 8%, Stroke 8%, Permanent paraplegia 6%, Renal Failure 8%

Zone 2 Arch



Open zone 2 arch for repair of acute type A dissection (A) and completed repair with branched TEVAR graft docking into aortic graft and LSCA (B) panel. TEVAR, thoracic endovascular aortic repair.

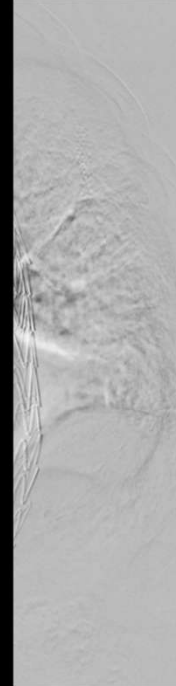
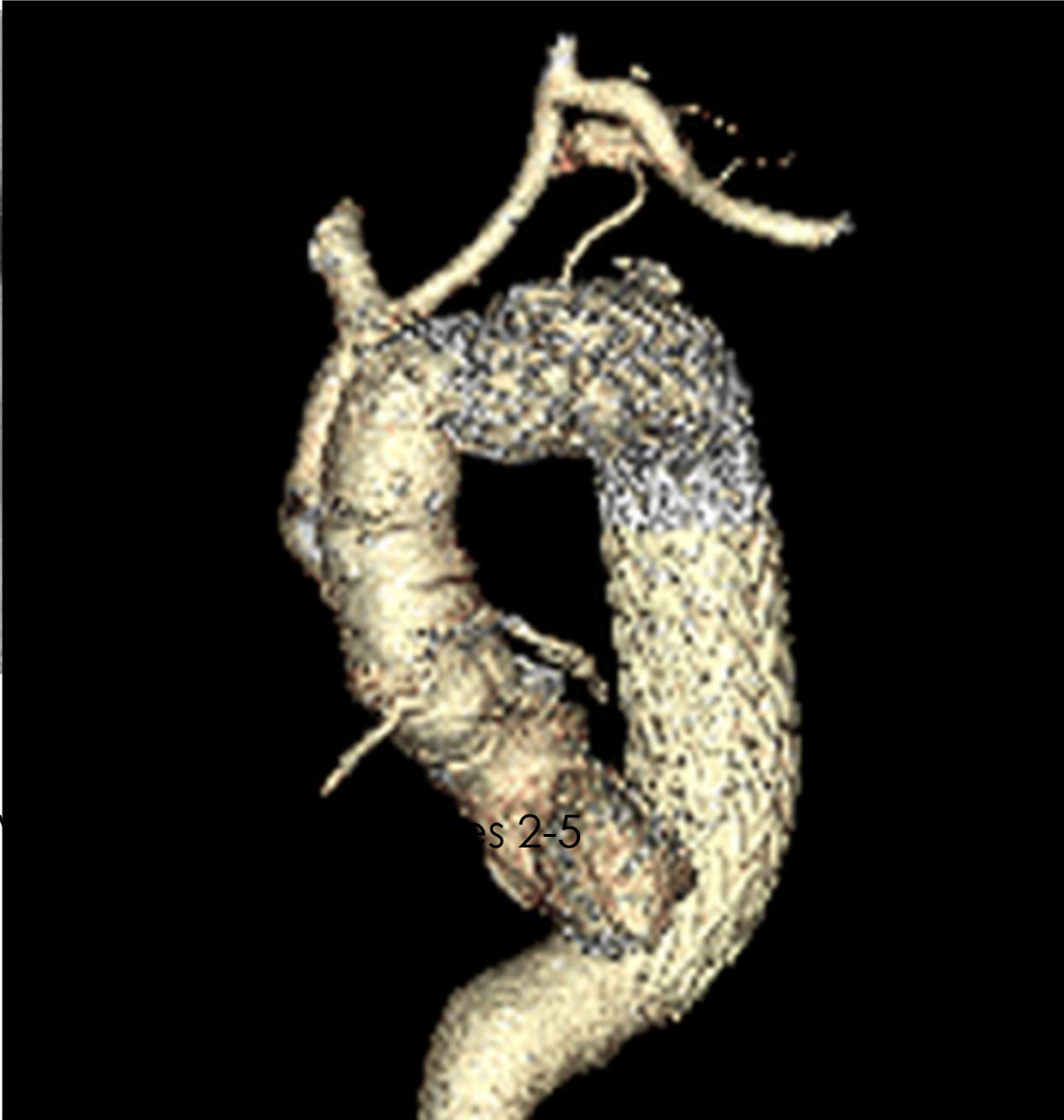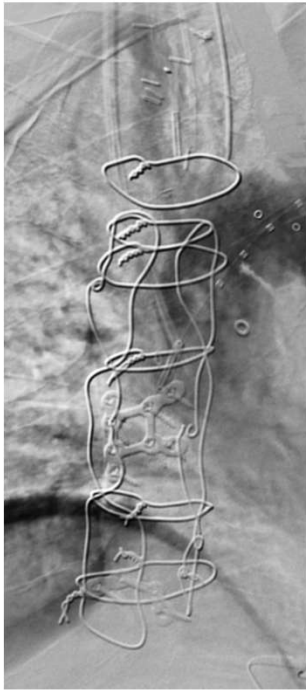
Hybrid Zone 2 Arch Repair



71 yo male with CRI, osteosarcoma LLE with chronic prosthesis infection presented with enlarging 6.5 cm DTAA, arch 4.5 cm

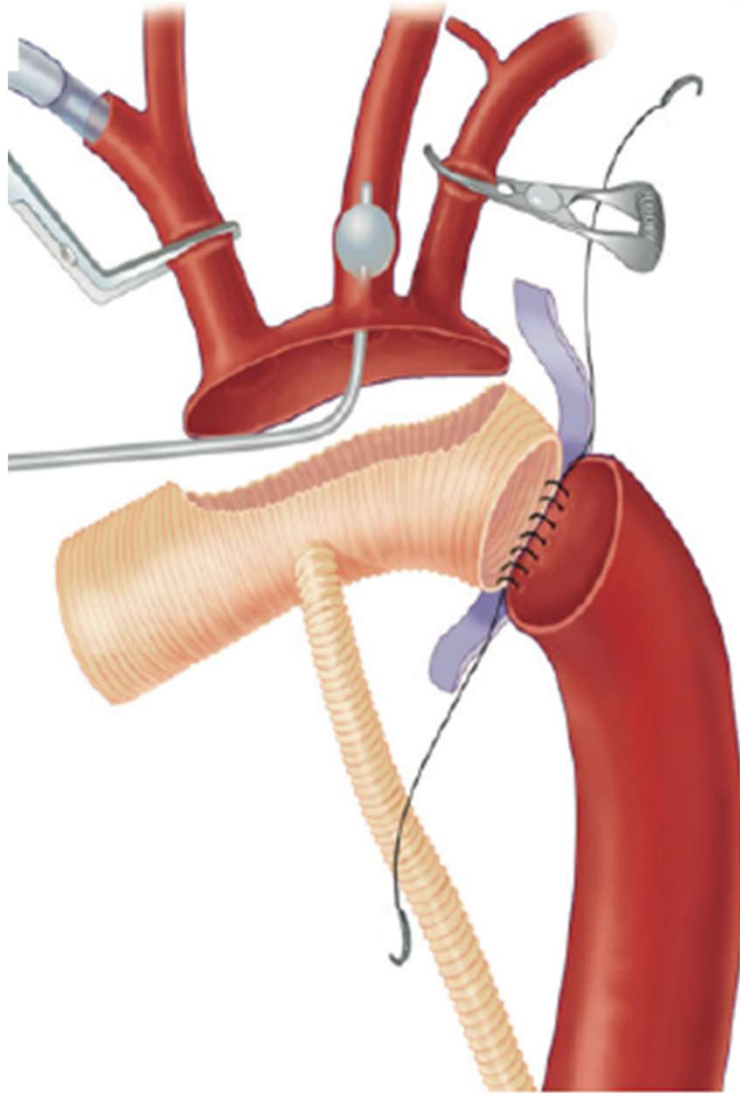
8/17: Replace ascending aorta and Zone 2 arch with 30 mm Sienna graft, Bilat ACP
And L Carotid-subclavian bypass

2nd stage TEVAR



12/17: TEVAR stages 2-5

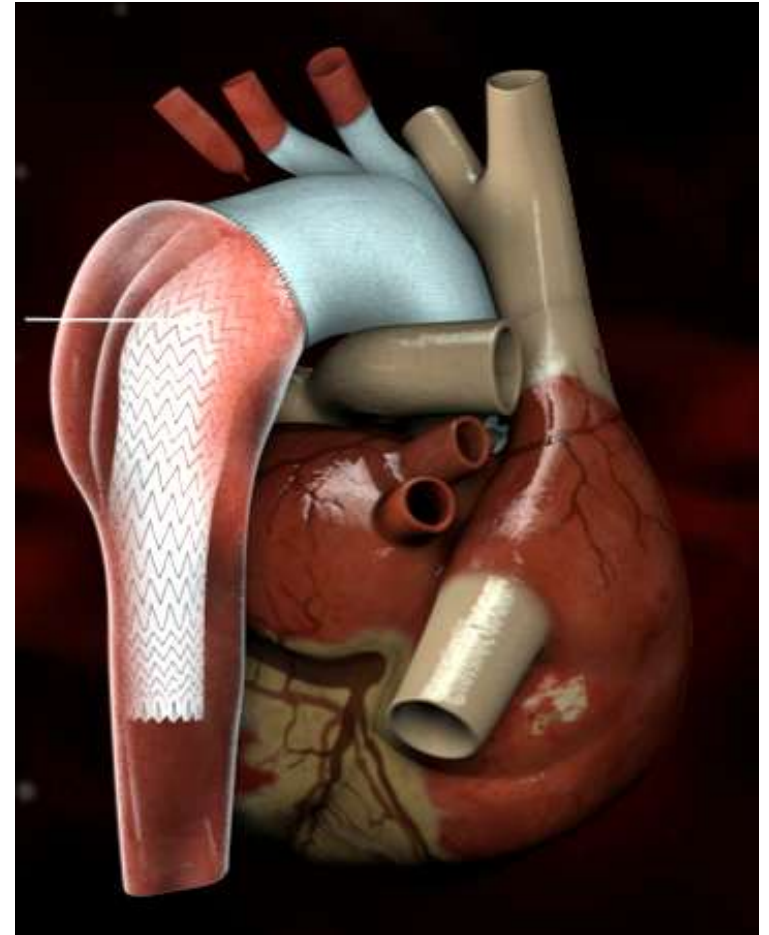
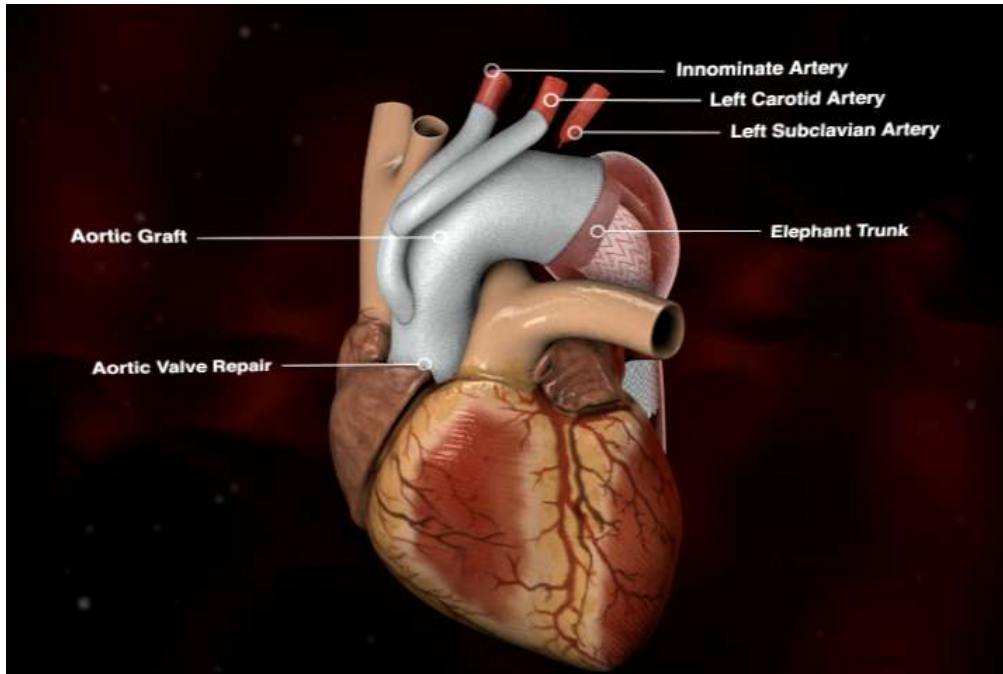
Open Arch Repair



Current Techniques

- Moderate/deep hypothermia
- Circulatory arrest
- Selective cerebral perfusion
- Distal aortic perfusion
- CSF drain

Frozen Elephant Trunk



- A concept aimed at reducing subsequent distal aortic operations (30% post type A repair)
- Obviates 2nd stage Thoracotomy and reduction interval mortality

Aortic Arch Replacement

Table 1 Some important results of total arch replacement published during the last decade

Author	Year	Pts.	M. age	Emergency	Hosp. death	PND/TND
Kazui	2007	420	71	29%	9.3%	3.2%/4.7%
Kouchoukos	2008	51	–	NP	3.9%	0/1.9%
Ogino	2008	431	–	26%	4%	3.3%/10.6%
Sundt	2008	347	–	33%	8.9%	8.4%/NP
Iba	2011	1,007	–	26%	4.7%	3.5%/6.7%
Okita	2013	423	69	32%	4.5%	3.3%/NP

Pts, patients; M. age, mean age; Hosp. death, hospital death; PND, permanent neurologic disorder; TND, transient neurologic disorder; NP, non-precise.

Mean Mortality 6%; Mean Permanent Neurologic Deficit 4%

A systematic review and meta-analysis of hybrid aortic arch replacement

Konstantinos G. Moulakakis^{1,2}, Spyridon N. Mylonas³, Fotis Markatis¹, Thomas Kotsis³, John Kakisis¹, Christos D. Liapis¹

¹Department of Vascular Surgery, Athens University Medical School, Attikon University Hospital, Athens, Greece; ²The Systematic Review Unit, The Collaborative Research (CORE) Group, Sydney, Australia; ³Vascular Unit, 2nd Clinic of Surgery, Aretaieion Hospital, Medical School, University of Athens, Athens, Greece

- All published studies up to December 2012 examined
- 956 patients underwent arch debranching (AD) procedures
- 1316 underwent frozen elephant trunk (ET) technique

Demographics/Results

Table 3 Demographic variables and comorbidities of the patients

	AD	ET
Total number of studies	26	20
Total number of patients	956	1,316
Gender (male %)	71.9	72.9
Mean age (years)	67.1 (64.3-70.0)	58.5 (54.2-62.8)
Comorbidities		
Nicotine consumption	63.5% (48.7-78.3%)	53.7% (35.3-72.1%)
DM	20.7% (12.6-28.9%)	8.0% (4.2-11.8%)
Hypertension	92.3% (86.6-97.9%)	77.5% (70.8-74.1%)
Renal impairment	19.0% (12.9-25.1%)	8.7% (5.9-11.5%)
Cerebrospinal disease	17.6% (10.6-24.7%)	9.9% (4.7-15.1%)
CAD	31.4% (24.0-38.7%)	15% (9.7-20.2%)
COPD	29.8% (22.8-36.8%)	16.8% (8.3-25.4%)
History of previous cardiovascular surgery (thorax, abdomen)	30.1% (21.6-38.5%)	32.1% (23.8-40.4%)

AD, arch debranching group; ET, elephant trunk group; DM, diabetes mellitus; CAD, coronary artery disease; COPD, chronic obstructive pulmonary disease

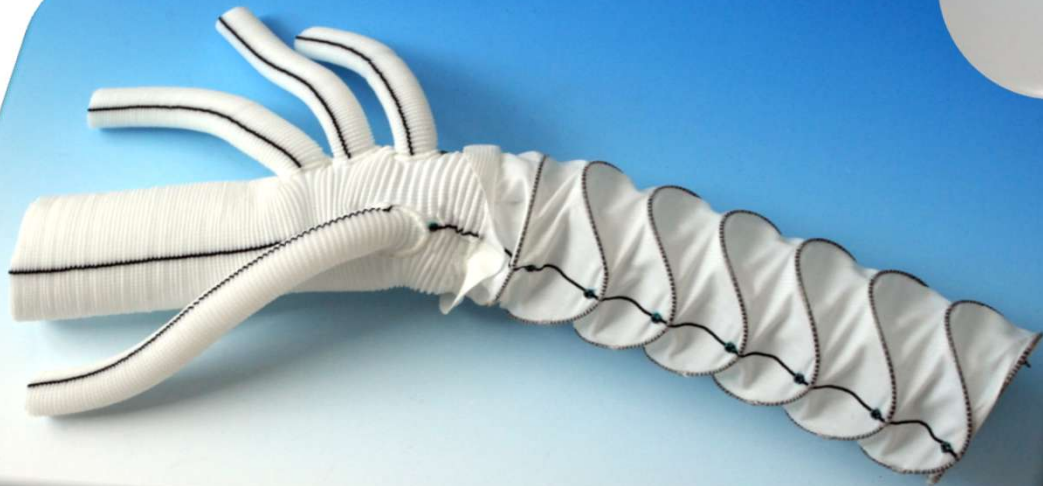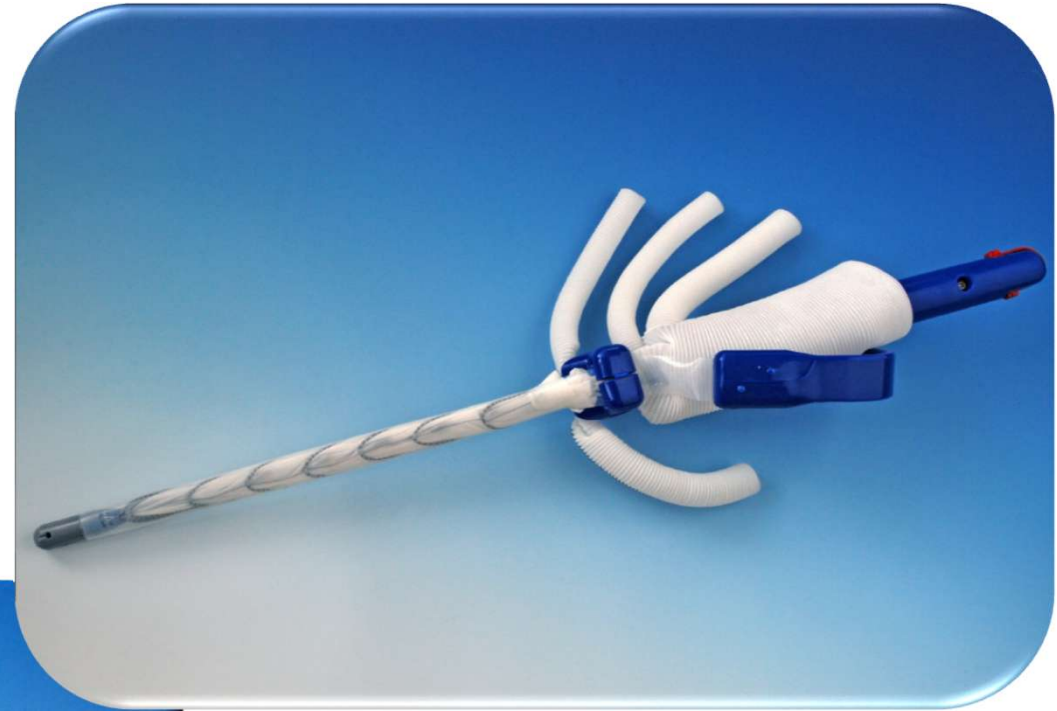- 30-day mortality 11.9% arch debranching, 9.5% for ET
- CVA 7.6% AD, 6.2% ET
- Spinal cord injury 3.6% AD, 5.0% ET
- Renal failure (HD) 5.7% AD, 3.8% ET

Conclusions

- Open total arch replacement remains gold standard for patients who are physiologically fit
- Hybrid endovascular arch replacement may be indicated selected patients with increased medical risk and anatomically feasible

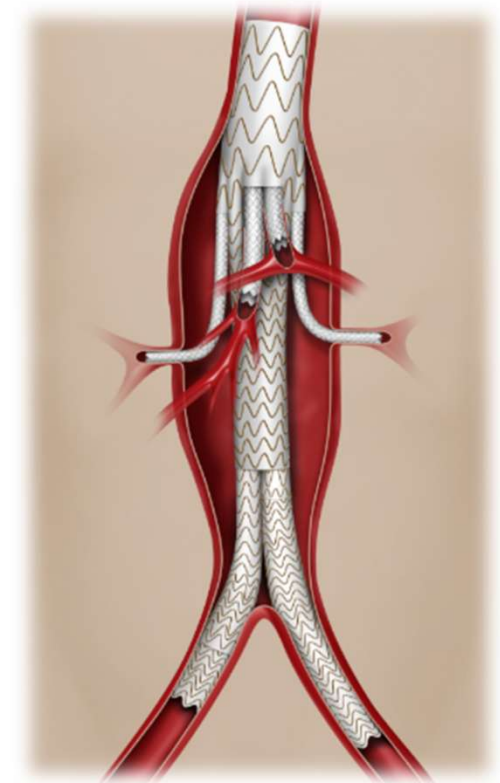
Vascutek Graft

Thoraflex has
branches for total
arch replacement



GORE® EXCLUDER® Thoracoabdominal Branch Endoprosthesis (TAMBE)

- Modular construction
 - Off-the-shelf components
- Design for Durability
 - EXCLUDER and CTAG technology
 - All components supplied by one manufacturer
 - Proven compatibility between components
 - CBAS coated branch component leveraging the flexibility of Viabahn and radial force of balloon expandable stent
- Ease of use
 - Pre-cannulated side branch portals
 - C3 Repositionability
 - Multi-stage Deployment



*Caution: Investigational Device. Limited by United States law to investigational use only.

W.L. Gore & Associates

Total aortic arch replacement with a novel four-branched frozen elephant trunk graft: first-in-man results[†]

Malakh Shrestha*, Maximilian Pichlmaier, Andreas Martens, Christian Hagl, Nawid Khaladj and Axel Haverich

Department of Cardio-thoracic, Transplantation and Vascular Surgery, Hannover Medical School, Hannover, Germany

- Vascutek first-in-man experience
- From April 2010 to August 2011, 34 patients underwent hybrid operation [14 aneurysms, 20 dissections (18 acute)].
- Hybrid graft deployment technical success 100%
- 30 day mortality AADA 17%

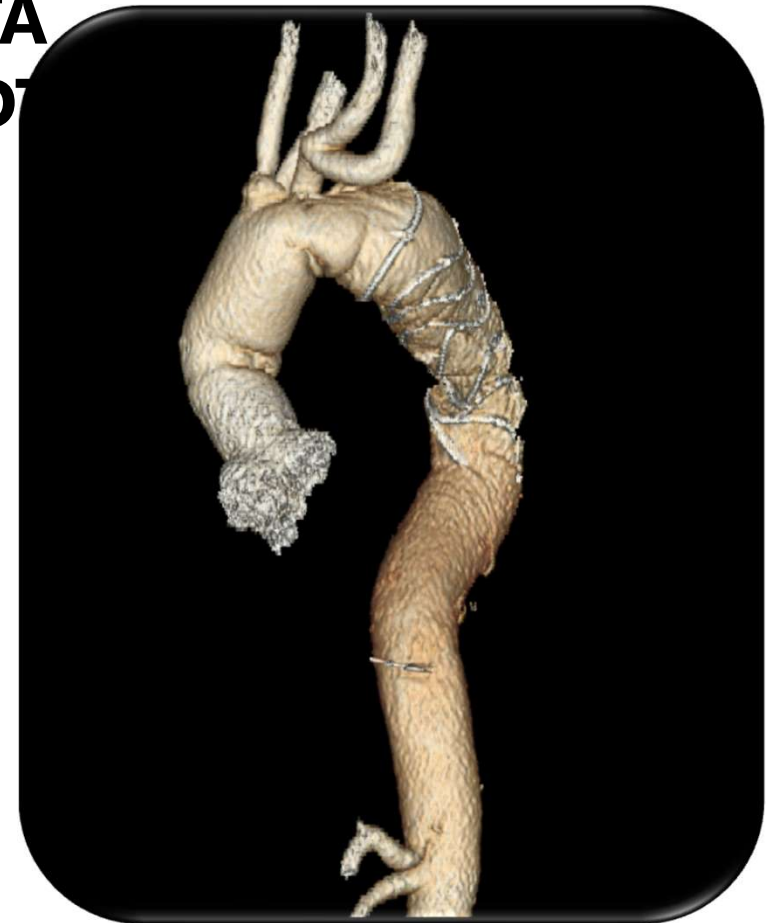Vascutek graft

Pro

- 1) reducing type Ia endoleak,
- 2) making distal anastomosis easier (collar)
- 3) Thrombosis of false lumen in DTA
- 4) Reverse remodeling of stented DTA
- 5) Easier Stent graft deployment?

Con

- 1) Paraplegia risk?
- 2) Increased cost?
- 3) Blind insertion of the device in the DTA under hypothermic circulatory arrest



Anatomic suitability of TEVAR

- 30-50% of patients anatomically suitable treatable TEVAR segment
- Criteria:
 - Intimal tear 10 mm above STJ, and at least 5 mm proximal to innominate
 - Absence of severe AI, cardiac tamponade, patent coronary artery bypass grafts, involvement of aortic root, or CTD

Moon, J Vasc Surg 2011;53:942

Sobocinski, Eur J Vasc Endovasc Surg 2011;42:442

Genetics



TAAD1, 5q 13-14

Guo D, Hasham S, Kuang SQ, Vaughan CJ, Boerwinkle E, Chen H, Abuelo D, Dietz HC, Basson CT, Shete SS, Milewicz DM. Familial thoracic

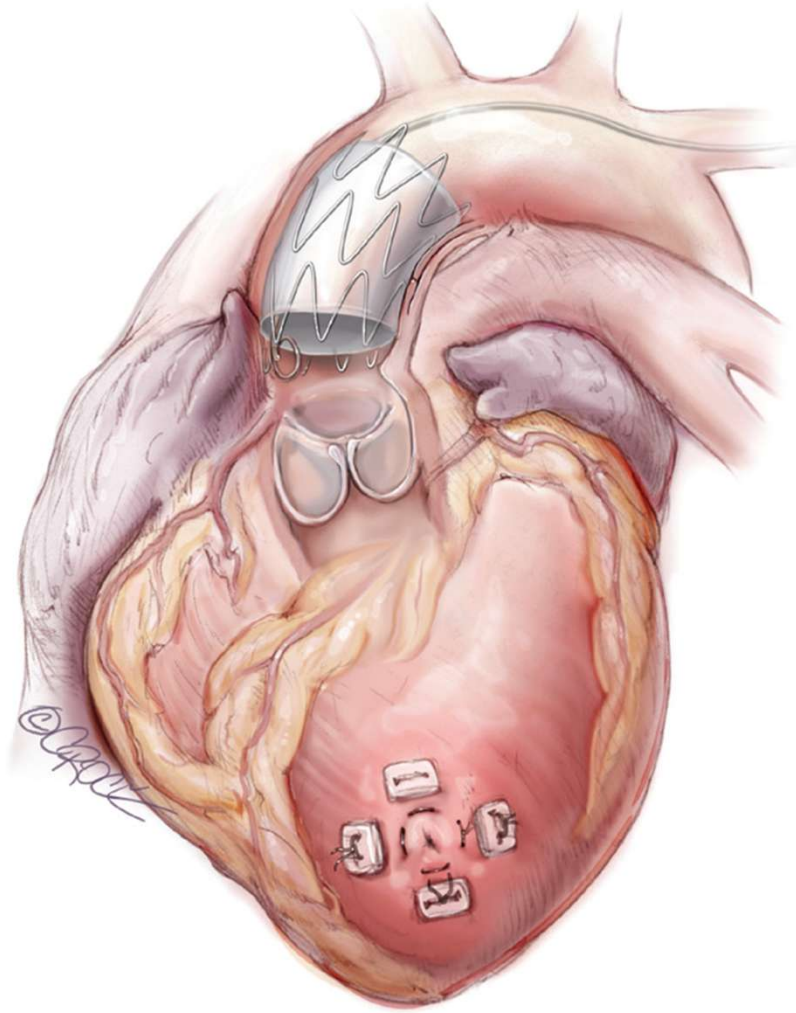
**Thoracic Aortic Aneurysms
& Dissections are familial in
20% of cases**

Thoracic Aortic Aneurysms and Dissections. NEJM. 2005

MYH11 mutation (Human Molecular Genetics. 2008)

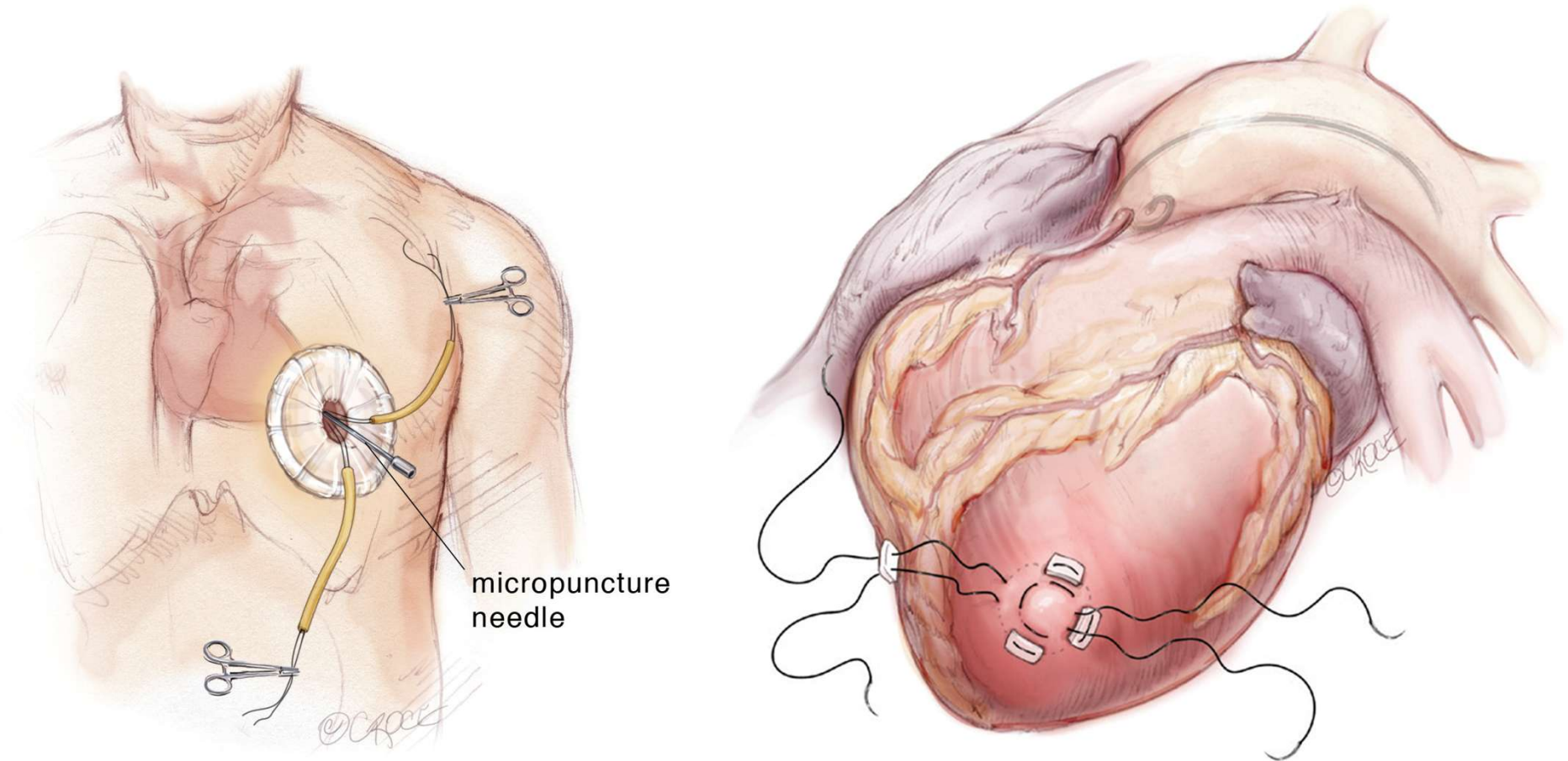
Mutations in smooth muscle alpha-actin (ACTA2) Am. J. Human Gen. 2009

Endovascular Technique



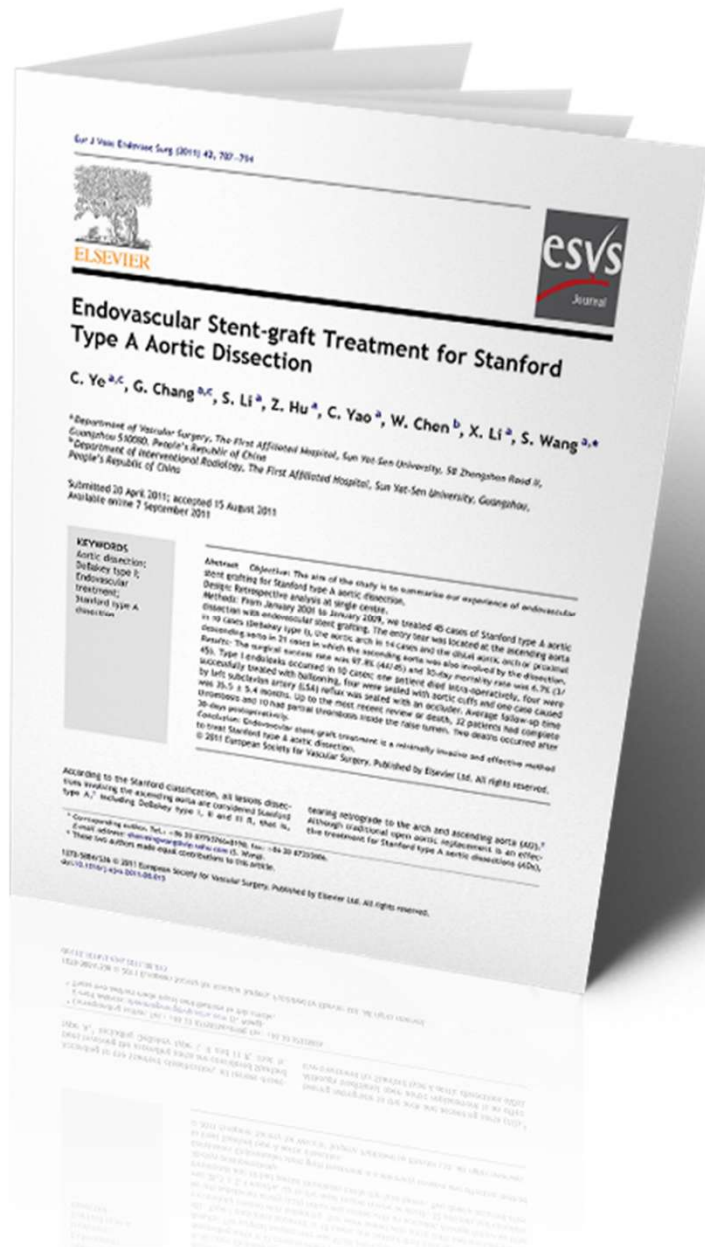
Endovascular Technique

- Trans-apical access

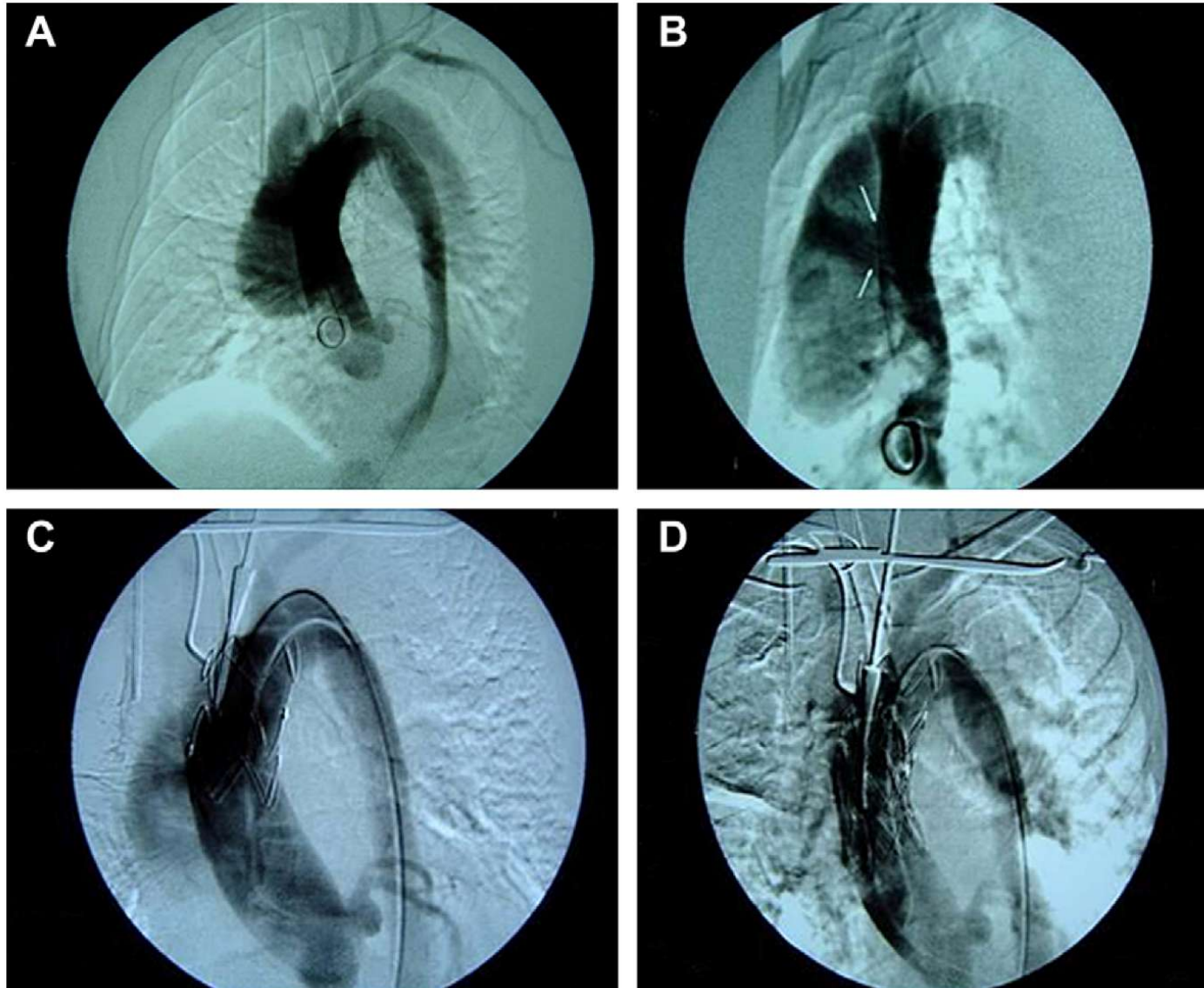


Ye et al. 2011

- 2001-2009; 45 pts
- 10 pts ET in ascending aorta (arch 14, prox desc ao 21 pts)
- Surgical success 97.8% (44/45)
- Type 1 endoleak 22%
- CVA 6.8%
- 30 D mortality 6.8% (3/45)

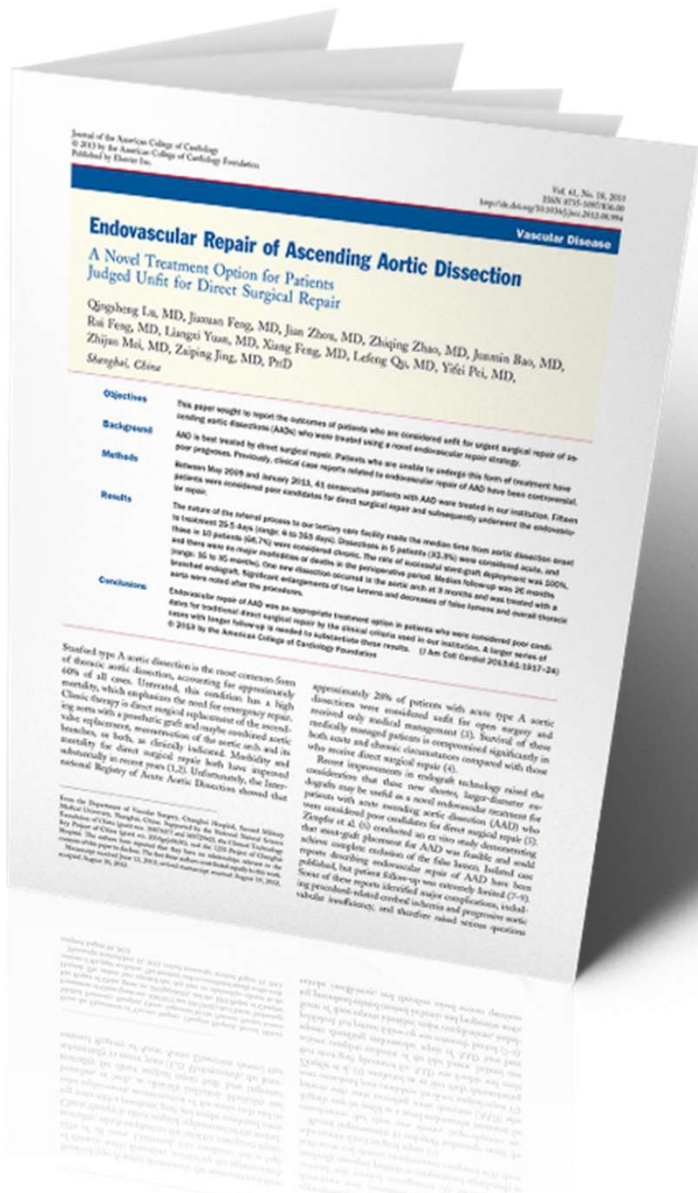

Type A repair from LCCA approach using 2 cuffs

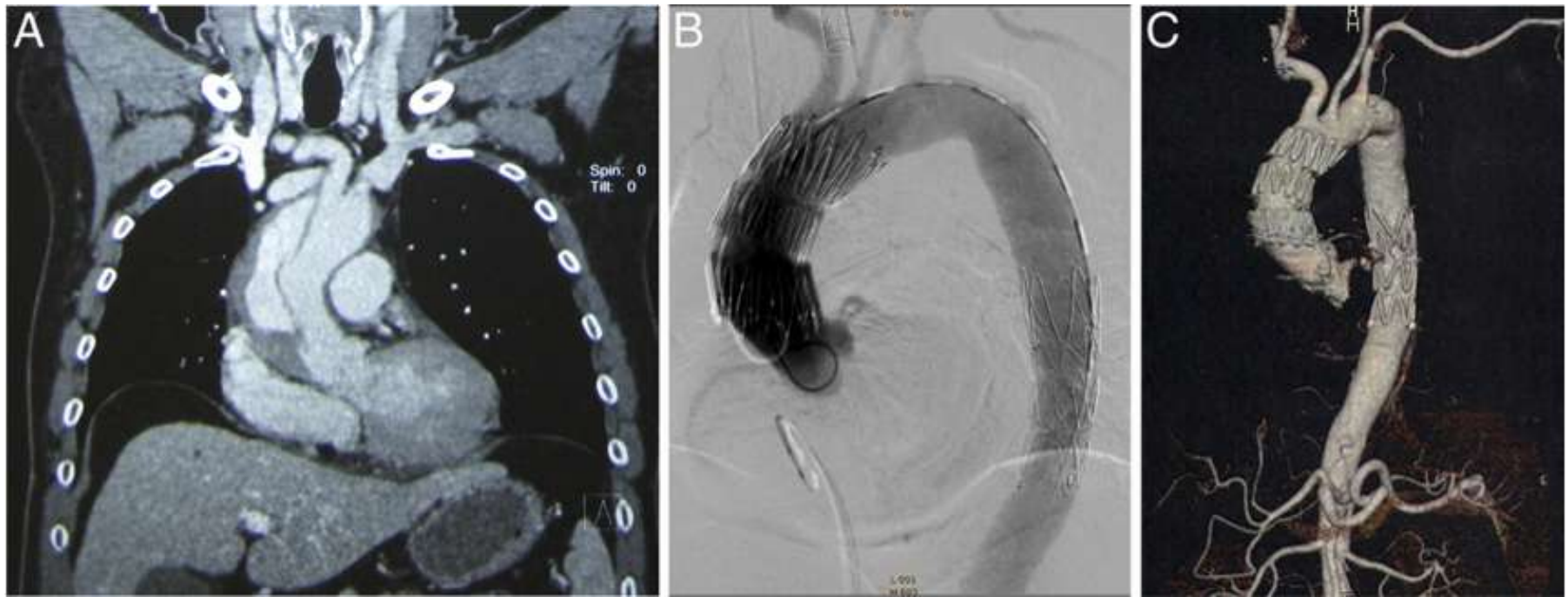


Lu et al. 2013 (Shanghai, China)

- 2009-2011
- 15 pts TAAD high risk medically unfit underwent TEVAR (5 acute, 10 chronic)
- Median time onset to Rx 25.5 days
- Technical success 100%; 0% CVA
- Median FU 26 mos



2 yr f/u pt with chronic dissection treated 36 days after symptom onset

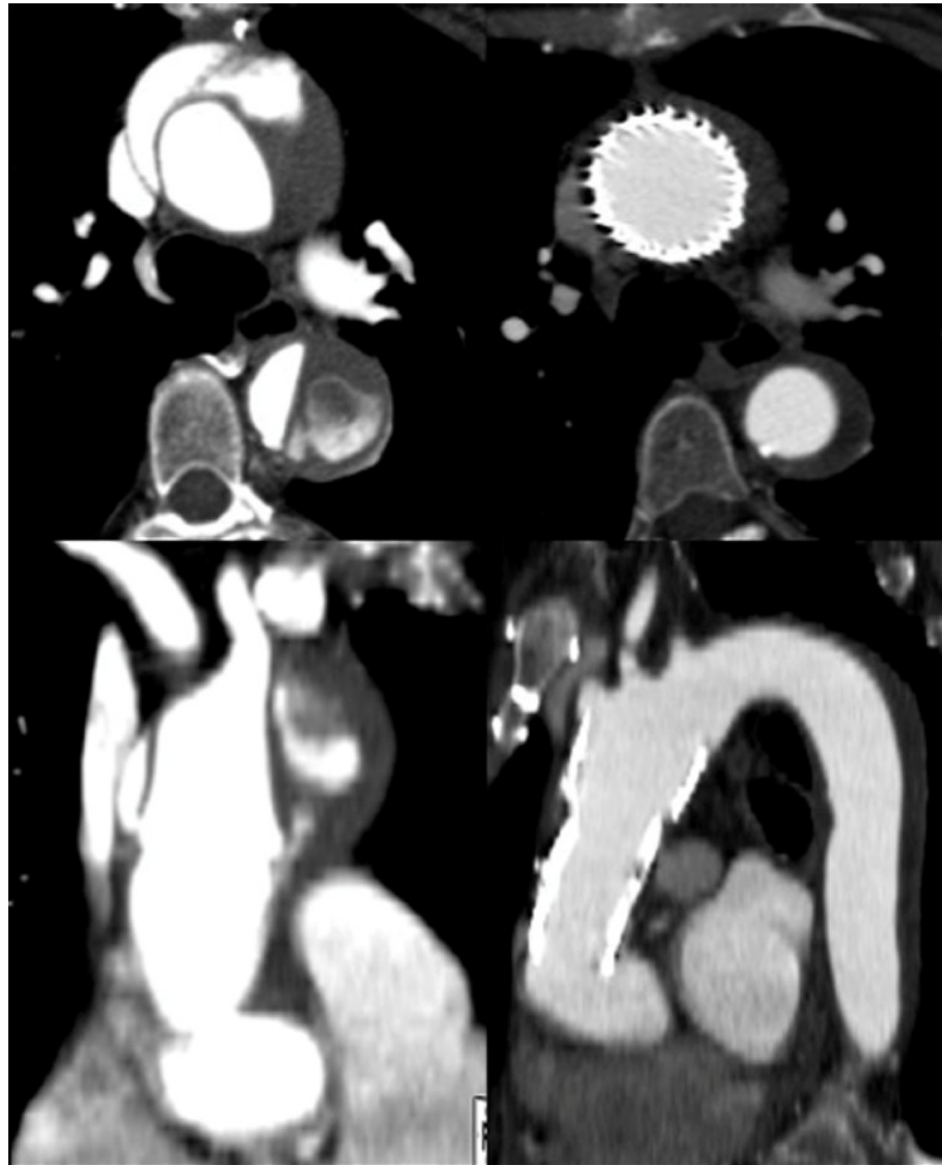


Mangialardi et al

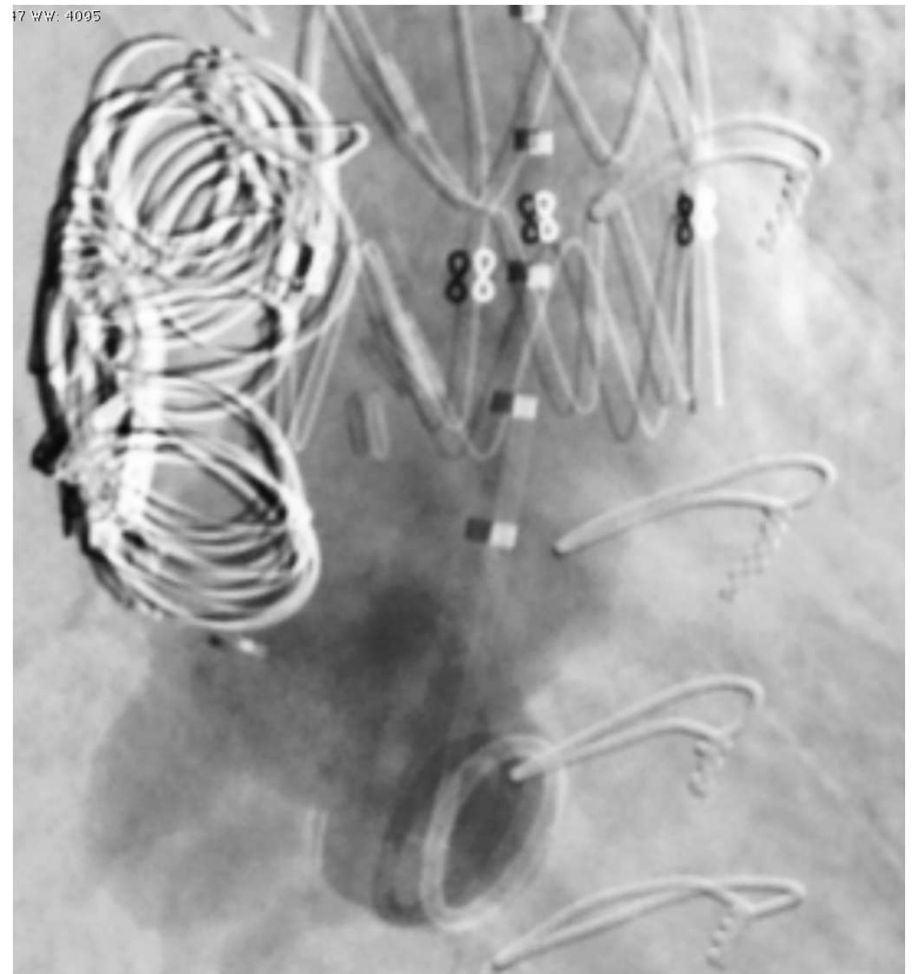
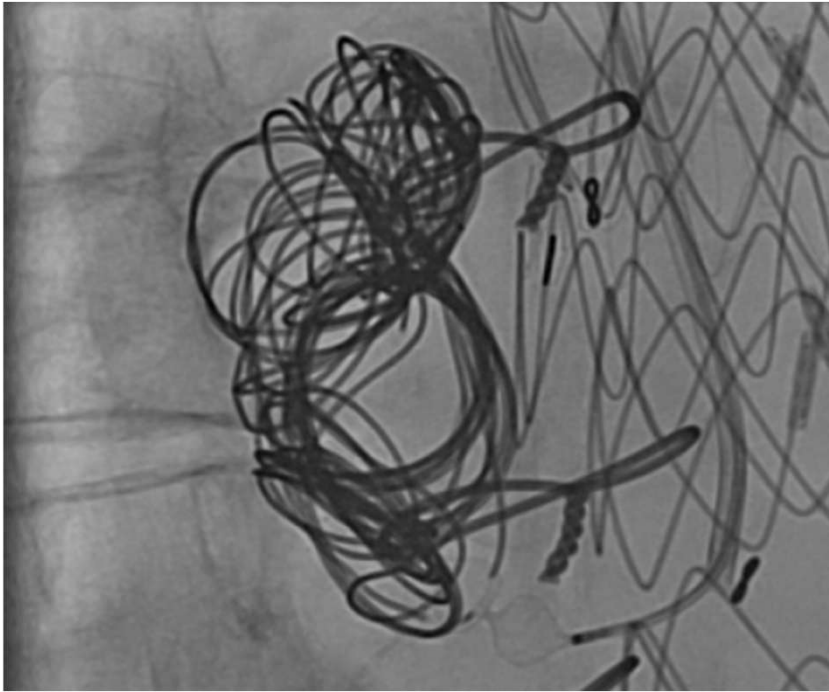

- From 2009-2013, 4 pts with TAAD underwent TEVAR
- Technical success 100%
- Mortality 0%
- Median follow-up 15 mo

3 mos FU CTA on pt with chronic dissection

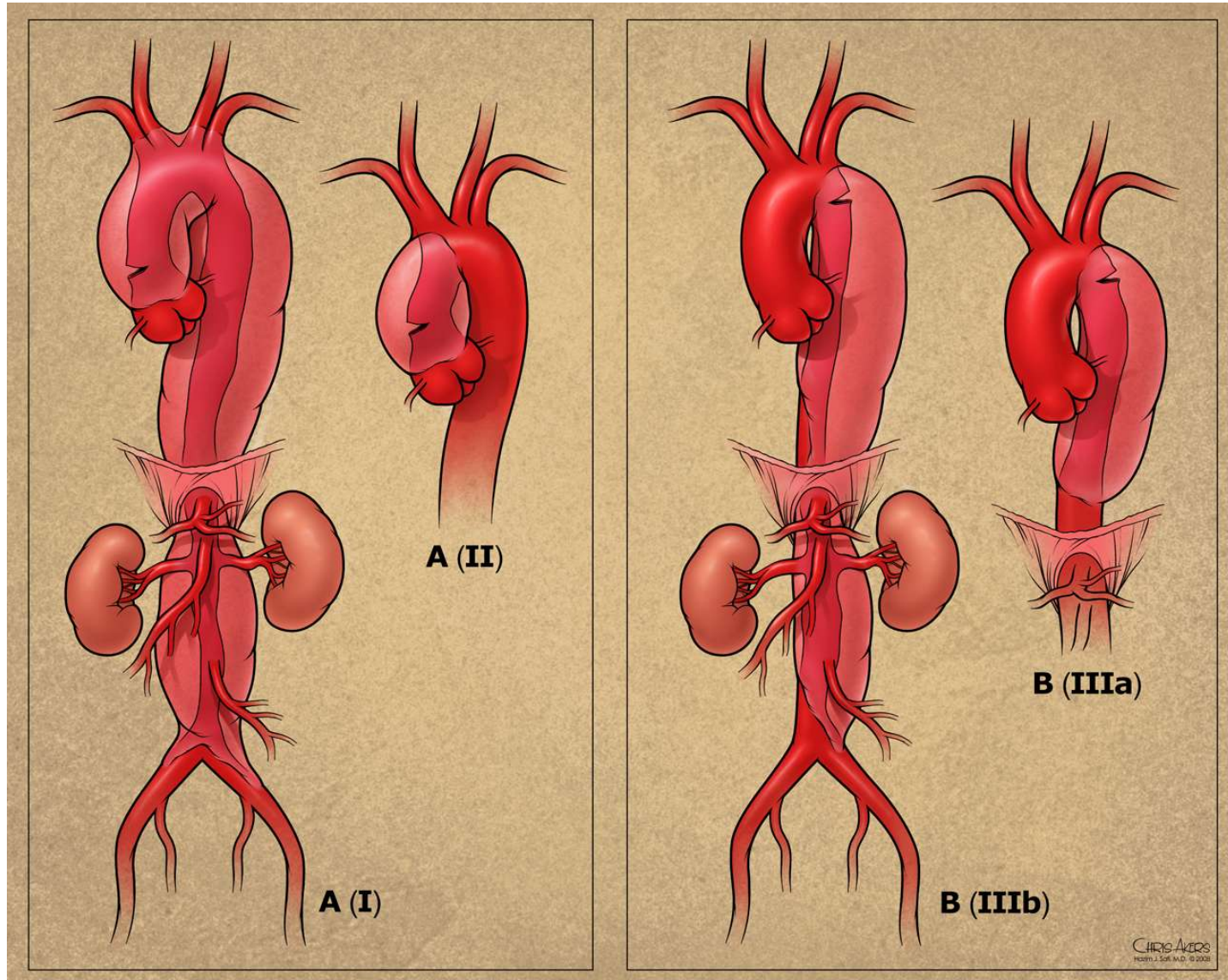


Pseudoaneurysm Embolization

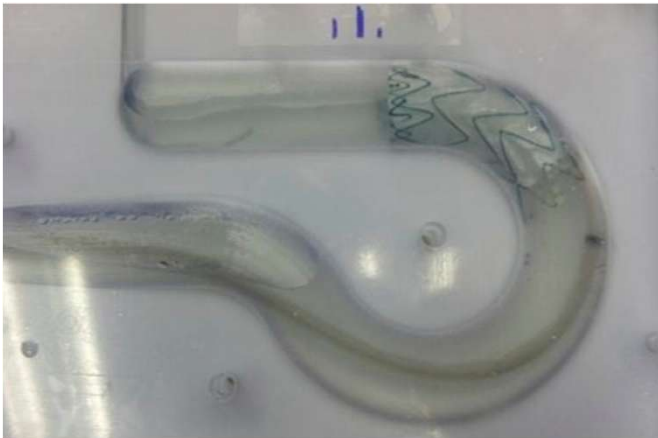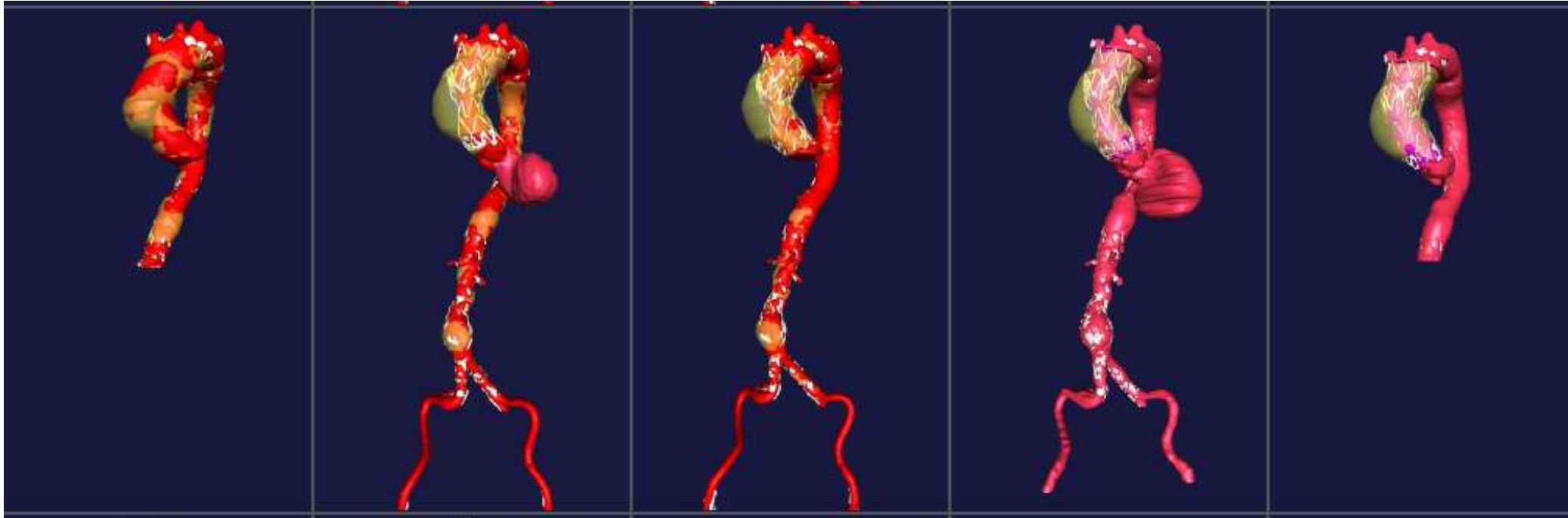


Successful coil embolization and vascular plug

Dissection Classification




Medtronic Valiant IDE

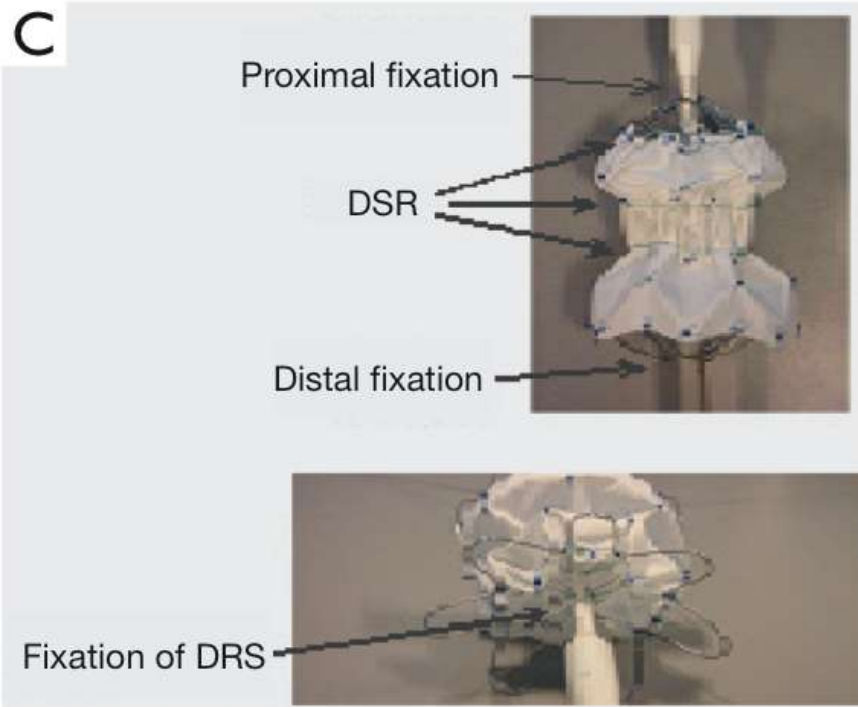



Courtesy of Drs. Rod White and Ali Khoynzhad

Cook Ascend

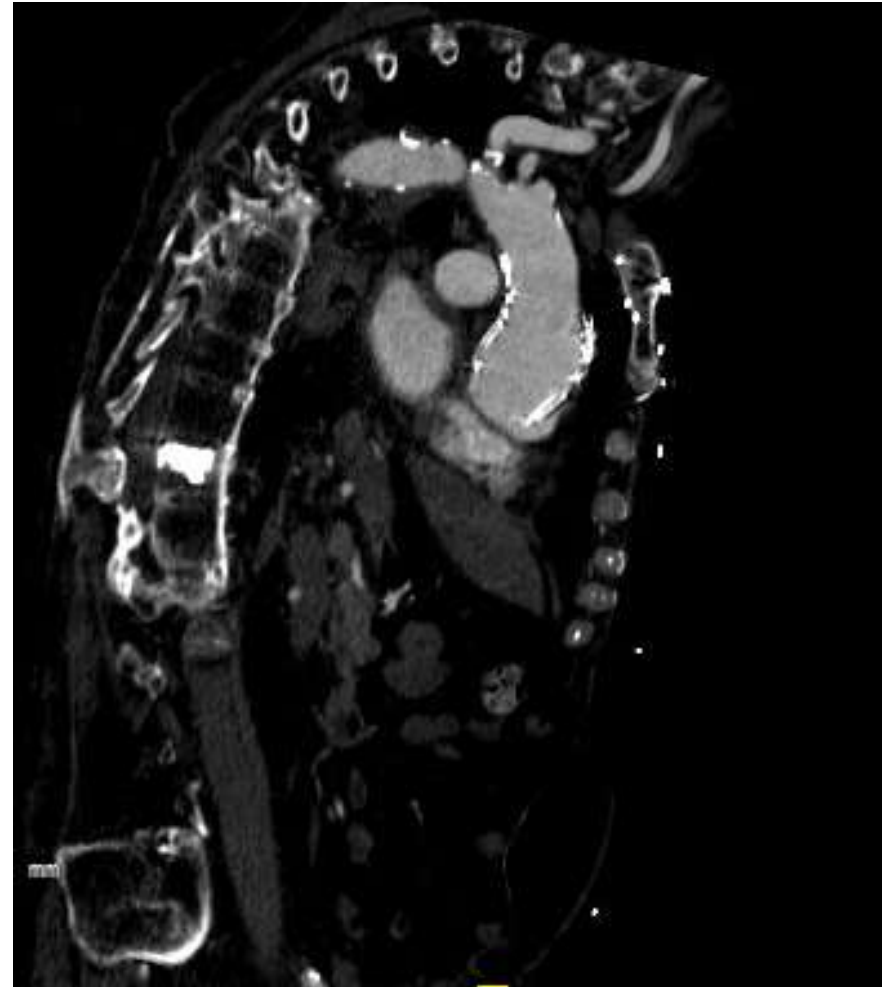
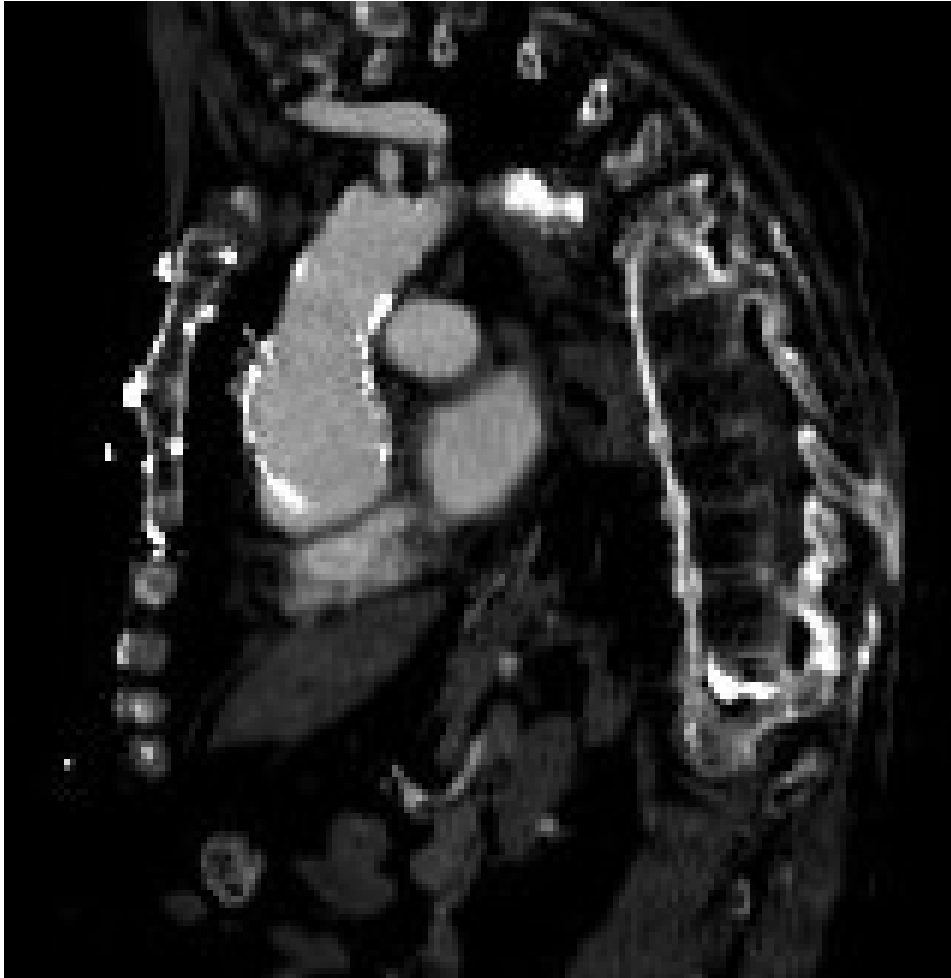
B Deployment sequence



Proximal and distal bare stents to aid
Fixation and conformability

Postop CT



CT after post deployment angio above

Aortic Disease treated by Device type

Device category	No. of patients (%)	Aortic dissection	Pseudoaneurysm	PAU	IMH	Aortic aneurysm	Aortic rupture	Other
Thoracic stent	84 (71.2)	42	20	5	3	6	2	6
Custom-made stent	12 (10.2)	8	3	0	0	0	1	0
Abdominal cuff	13 (11)	2	10	0	0	0	0	1
Unknown stent	8 (6.8)	7	1	0	0	0	0	0
Thoracic cuff	1 (0.9)	0	1	0	0	0	0	0
Total	N = 118	59 (50%)	35 (29.7%)	5 (4.2%)	3 (2.5%)	6 (5.1%)	3 (2.5%)	7 (5.9%)

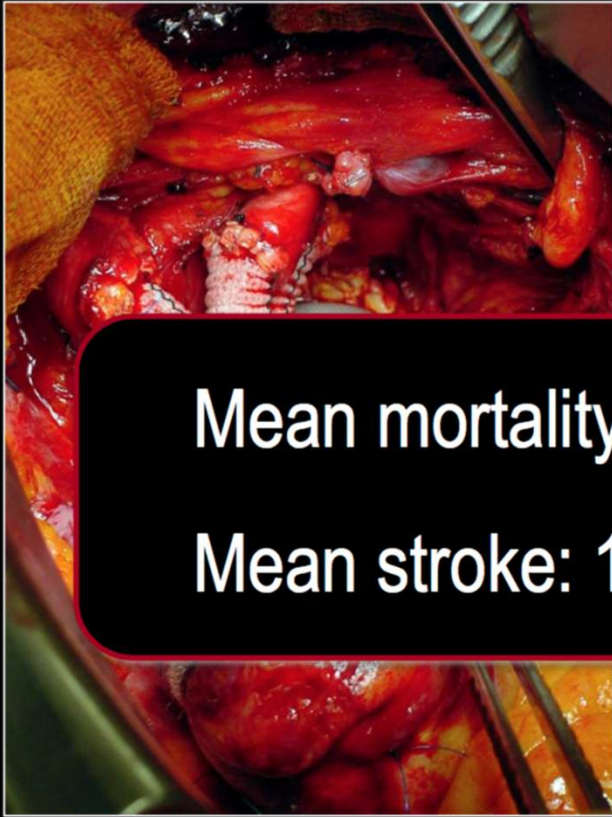
IMH, Intramural hematoma; PAU, penetrating atherosclerotic ulcer.

Vascular Access

Device category	Femoral	Transapical	Carotid	Axillary	Subclavian	Iliac
Thoracic stent	61	16	1	4	0	2
Custom-made stent	7	0	5	0	0	0
Abdominal cuff	1	0	6	4	1	1
Unknown stent	5	1	2	0	0	0
Thoracic cuff	0	0	1	0	0	0
Total	74 (62.7%)	17 (14.4%)	15 (12.7%)	8 (6.8%)	1 (0.9%)	3 (2.5%)

The most commonly used device type were thoracic aortic stent grafts deployed via trans-femoral approach

Current outcomes after open arch repair



Mean mortality: 10.8%
Mean stroke: 10.6%

Author

No Pts.

Perioperative mortality

Stroke rate

Strauch

120

13%

8%

8%

15%

15%

17%

3%

3%

6%

10%

Okita

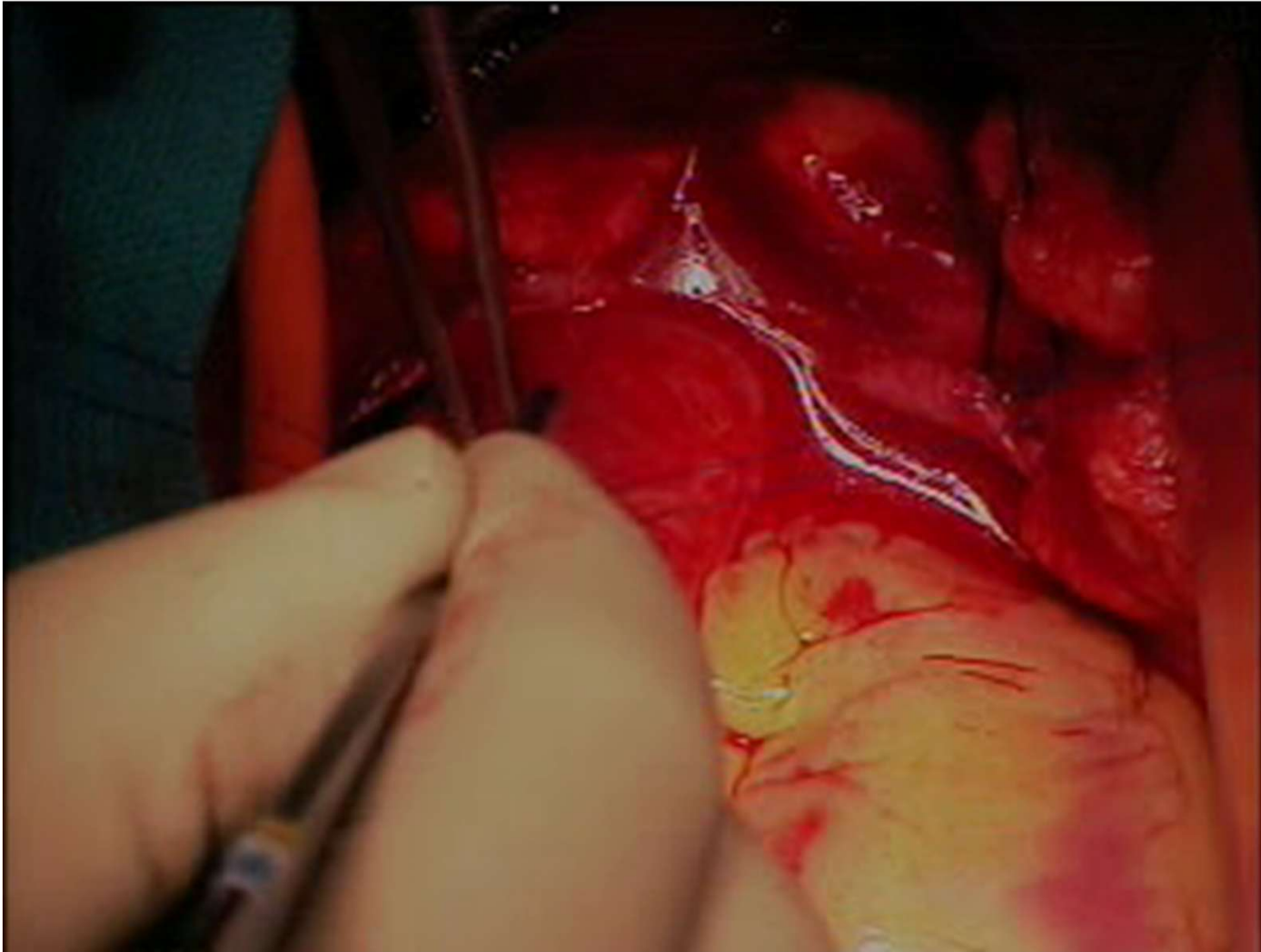
246

20%

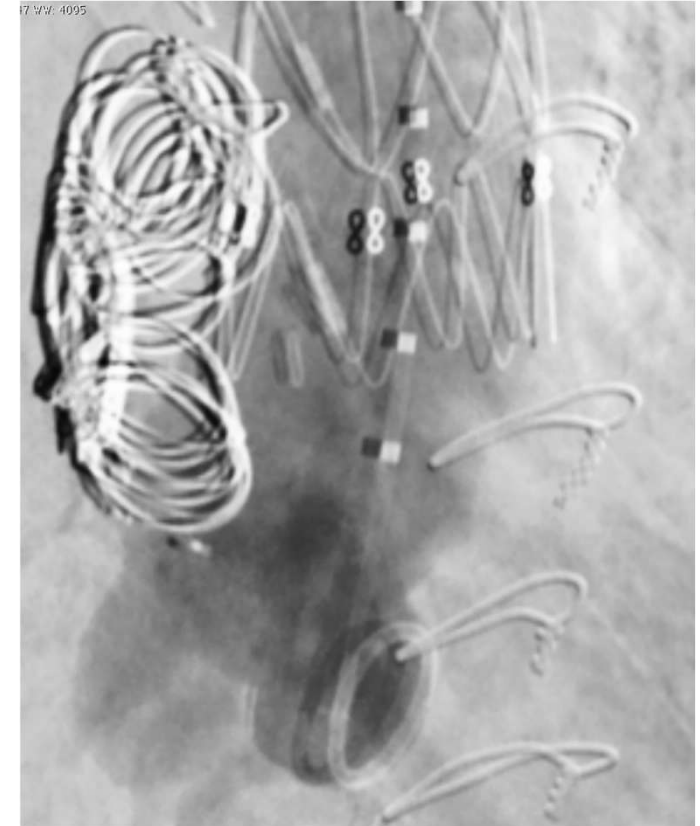
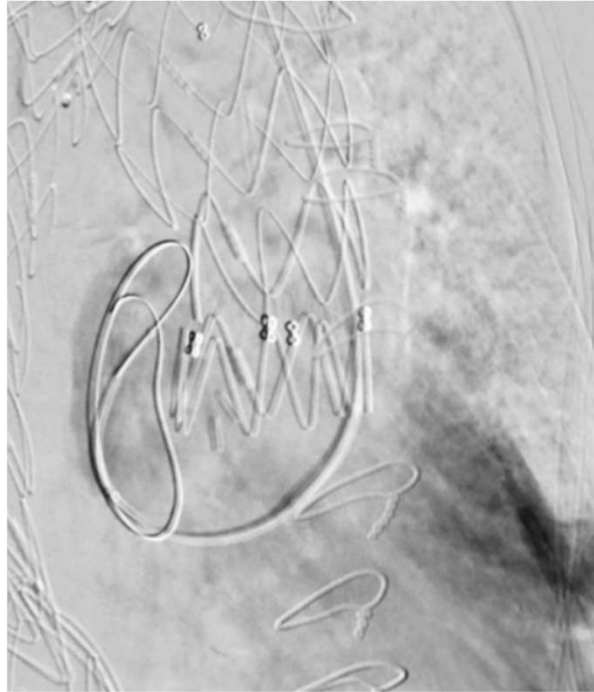
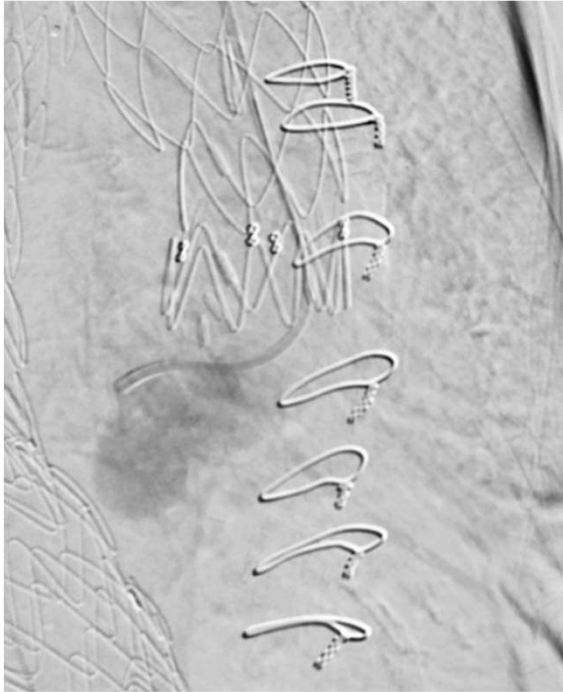11%

Wolfe et al, Eur J Vasc Endovasc Surg 2010

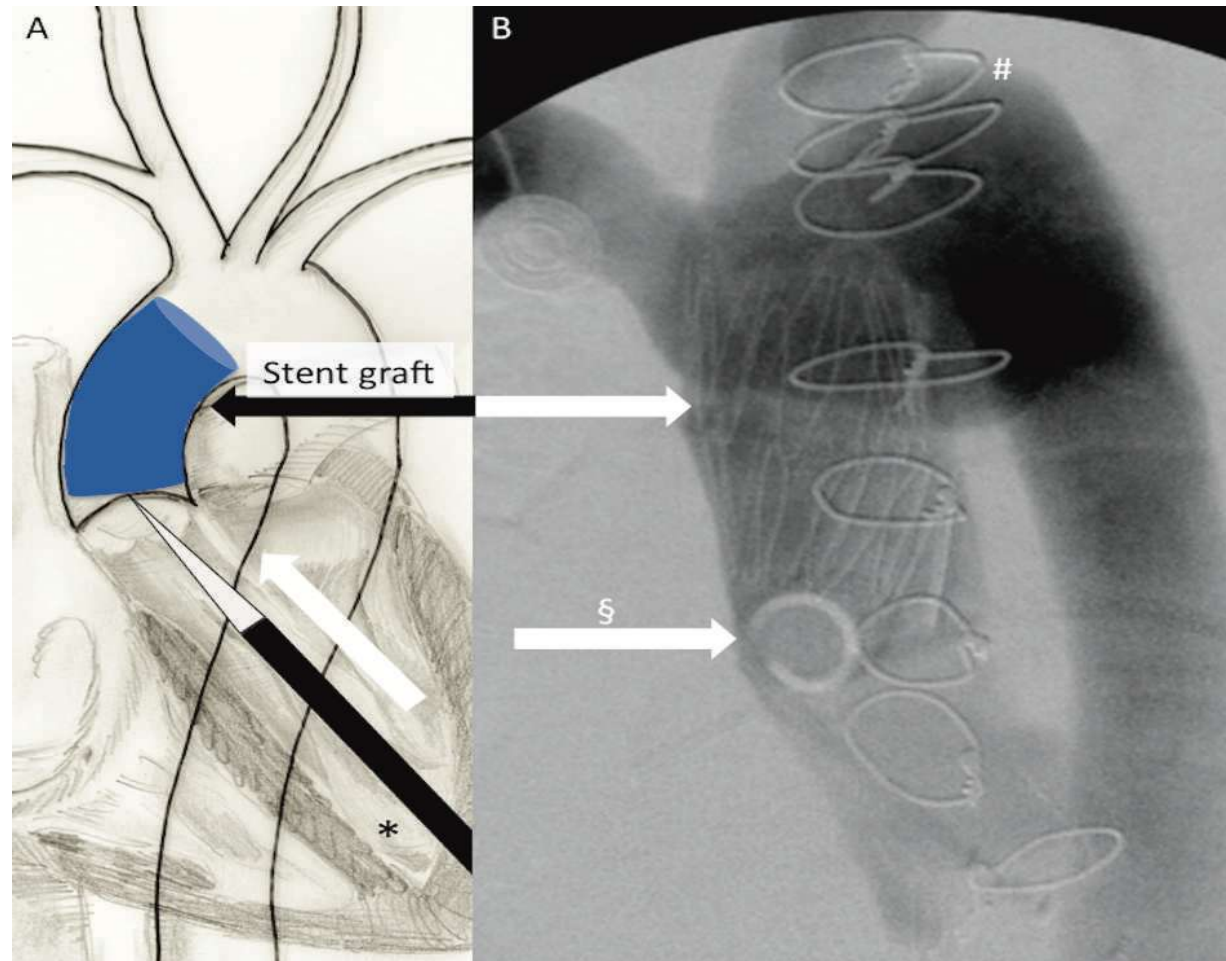
Type A Dissection



Pseudoaneurysm Embolization



Ascending TEVAR



36mm x 5 cm PS IDE Medtronic stent graft via Trans-apical approach

Long-term survival and related outcomes for hybrid versus traditional arch repair – a meta-analysis

Adam Chakos¹, Dean Jbara¹, Tristan D. Yan^{1,2,3}, David H. Tian^{1,4}

¹The Collaborative Research (CORE) Group, ²Faculty of Medicine and Health Sciences, Macquarie University, Sydney, Australia; ³Department of Cardiothoracic Surgery, Royal Prince Alfred Hospital, Sydney, Australia; ⁴Royal North Shore Hospital, Sydney, Australia

Correspondence to: Adam Chakos. The Collaborative Research (CORE) Group, Macquarie University, Sydney, Australia.

Email: adam.chakos@outlook.com.

Evaluated 9 studies with 841 hybrid arch repair, 1182 open total arch repair

Demographics

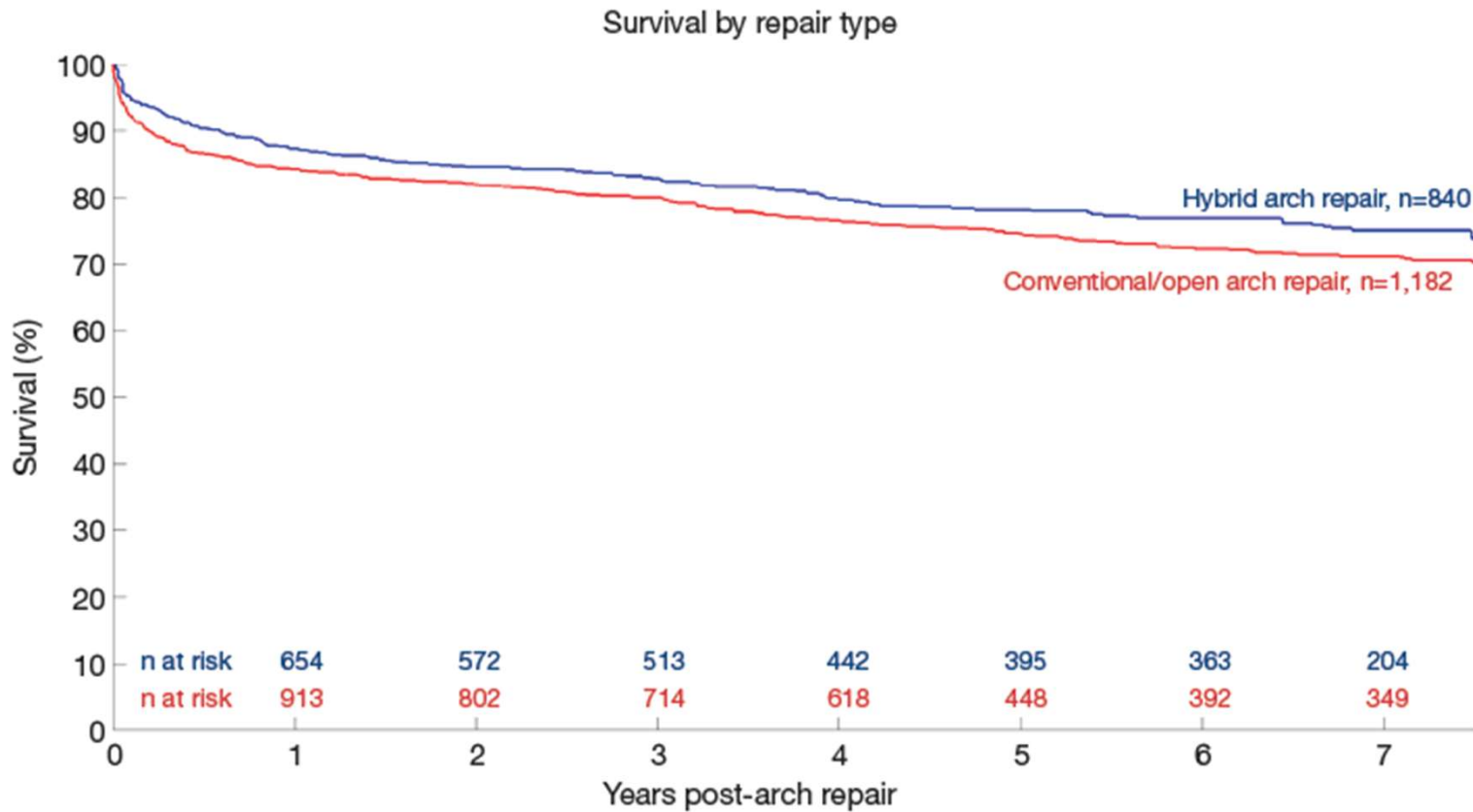
Characteristic	Hybrid repair, n [% (95% CI)]	Conventional repair (CTAR), n [% (95% CI)]
Patients	841	1,182
Males	560	761
Age, mean (95% CI)	63.5 (54.6; 72.3)	59.0 (54.3; 63.7)
Hypertension	378/483 [81.8 (71.1; 89.1)]	425/566 [72.7 (58.9; 83.2)]
Diabetes mellitus	31/483 [7.3 (4.2; 12.4)]	40/566 [6.6 (3.4; 12.6)]
PVD	64/496 [11.4 (4.0; 28.4)]	39/291 [5.8 (1.1; 25.4)]
COPD	95/319 [26.6 (12.7; 47.6)]	157/873 [14.3 (6.1; 30.1)]
Prior CVA	47/564 [9.2 (4.9; 16.5)]	102/868 [12.4 (9.6; 15.9)]
Coronary disease	80/464 [14.9 (4.5; 39.7)]	88/468 [11.7 (5.0; 25.0)]
Renal impairment	69/610 [10.1 (4.8; 19.9)]	69/993 [5.5 (2.8; 10.8)]
Prior sternotomy, cardiac, aortic surgery	166/647 [20.1 (10.2; 35.8)]	258/970 [23.1 (10.5; 43.5)]
Presentation		
Aneurysm (degenerative, atherosclerotic)	212/391 [70.5 (48.2; 85.9)]	350/579 [51.8 (28.5; 74.3)]
Acute dissection	237/476 [60.6 (32.4; 83.2)]	207/348 [60.6 (32.4; 83.2)]
Chronic dissection	238/536 [26.3 (11.4; 49.7)]	170/643 [37.8 (16.1; 65.8)]
Percentage values and their CIs were calculated using meta-analysis of proportions or means as appropriate. CI, confidence interval; CTAR, conventional total arch replacement; PVD, peripheral vascular disease; COPD, chronic obstructive pulmonary disease; CVA, cerebrovascular accident.		

Operative Data

Parameter	Hybrid repair (HAR)		Conventional repair (CTAR)	
	Value	n reported	Value	n reported
Concomitant AVR, n [% (95% CI)]	117/631 [15.6 (9.2; 25.4)]	–	147/937 [18.0 (9.3; 31.8)]	–
Concomitant CABG, n [% (95% CI)]	87/689 [13.0 (9.5; 17.4)]	–	161/1,061 [15.0 (11.7; 19.0)]	–
CPB time (min)	201.1 (187.8; 214.5)	660/841	208.9 (175.6; 242.3)	1,107/1,182
Aortic cross-clamp time (min)	105.3 (95.8; 114.8)	616/841	122.3 (100.0; 144.7)	1,053/1,182
Cerebral perfusion time (min)	51.1 (35.2; 67.1)	559/841	49.6 (22.2; 76.9)	866/1,182

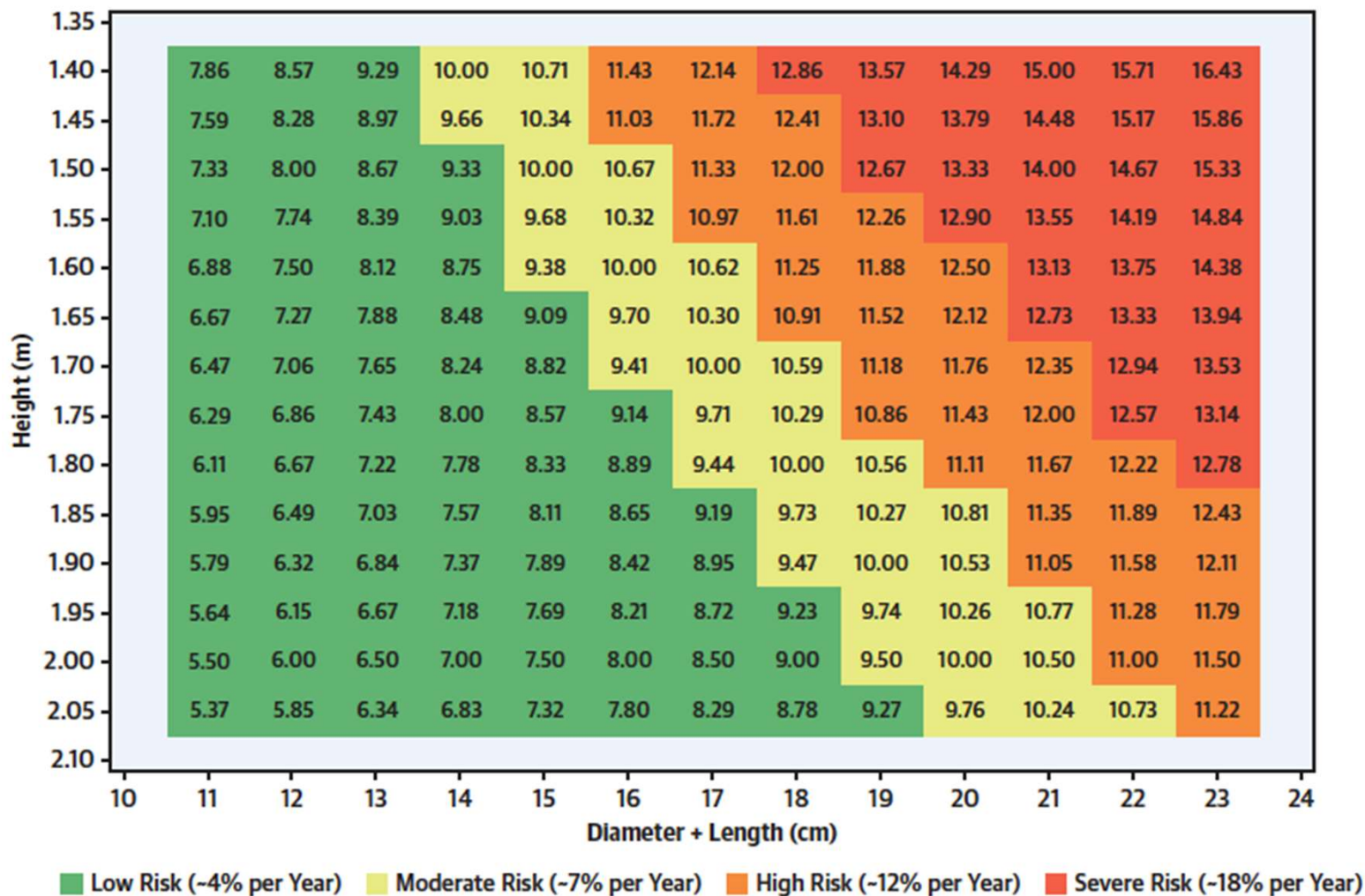
Values are given as pooled mean and 95% CI. The percentage was calculated using meta-analysis of proportions and means. CI, confidence interval; AVR, aortic valve replacement; CABG, coronary artery bypass grafting; CPB, cardiopulmonary bypass.

Survival

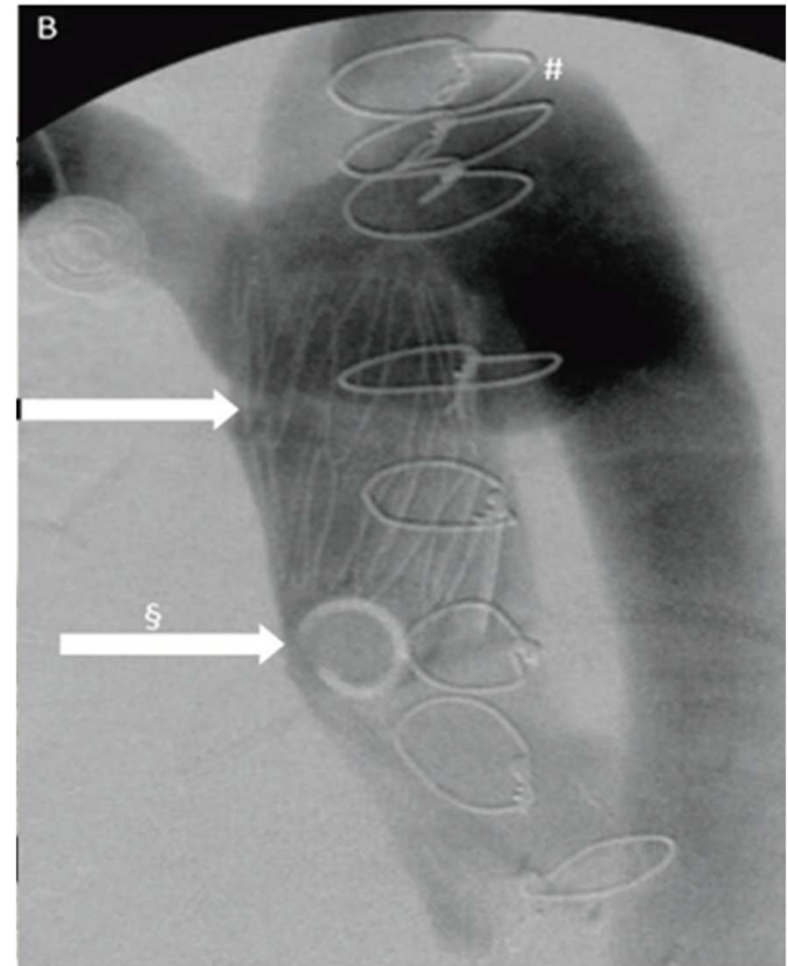
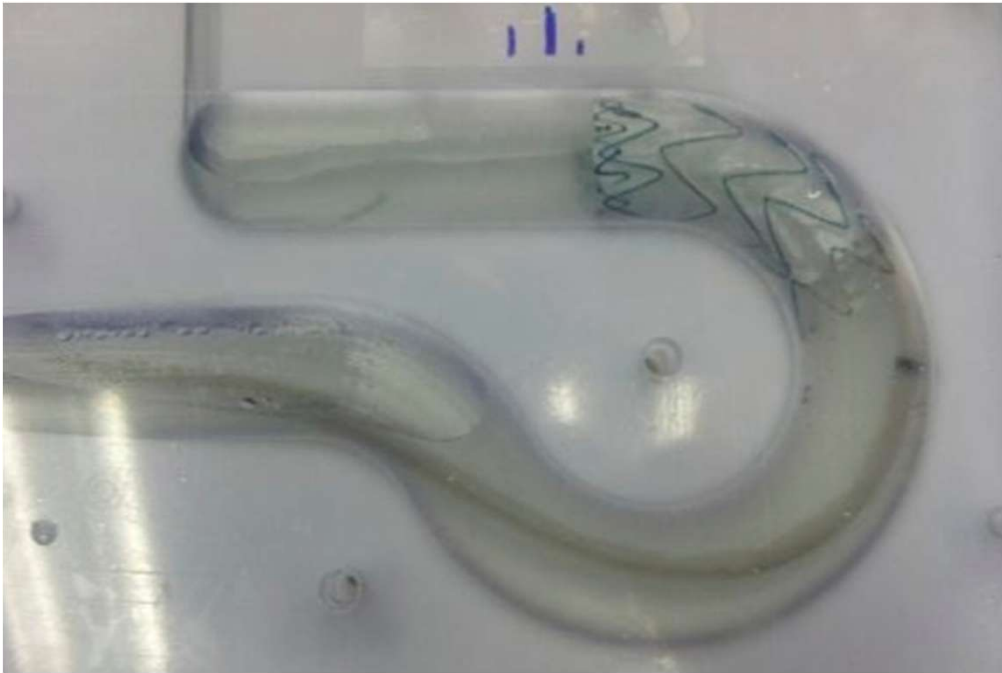

- Hybrid 1 yr survival 87%, 5-yr survival 78%
- Total arch 1 yr survival 84%, 5-yr survival 75%
- Total arch repair increased risk for re-op bleeding, decreased risk SCI

Risk of Aortic Adverse Events by Diameter and Height



Ascending TEVAR



36 mm x 5 cm PS IDE Medtronic Valiant stent graft with short nose cone with closed web captivia for controlled delivery (White, Khoynzhad) via Trans-apical approach