

Early Diagnosis of Syndromic HTAD with AI-Powered Facial Analysis

David R. Murdock, MD
Assistant Professor
McGovern Medical School
University of Texas Health Science Center at Houston





Family of woman who died [redacted] speaks out

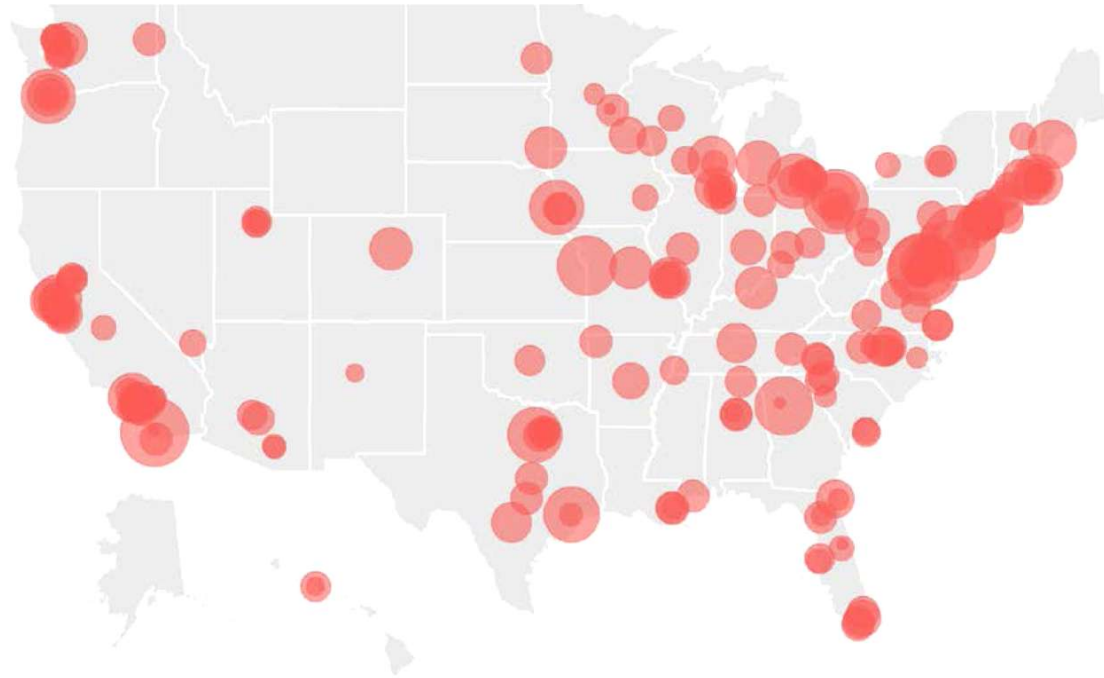
CTV News 
2.25M subscribers

[Subscribe](#)

-  31
- 
-  Share
-  Ask
-  Save
- 



Lack of Geneticists in USA and Globally



Jenkins, B.D., Fischer, C.G., Polito, C.A. *et al. Genet Med* **23**, 1458–1464 (2021).

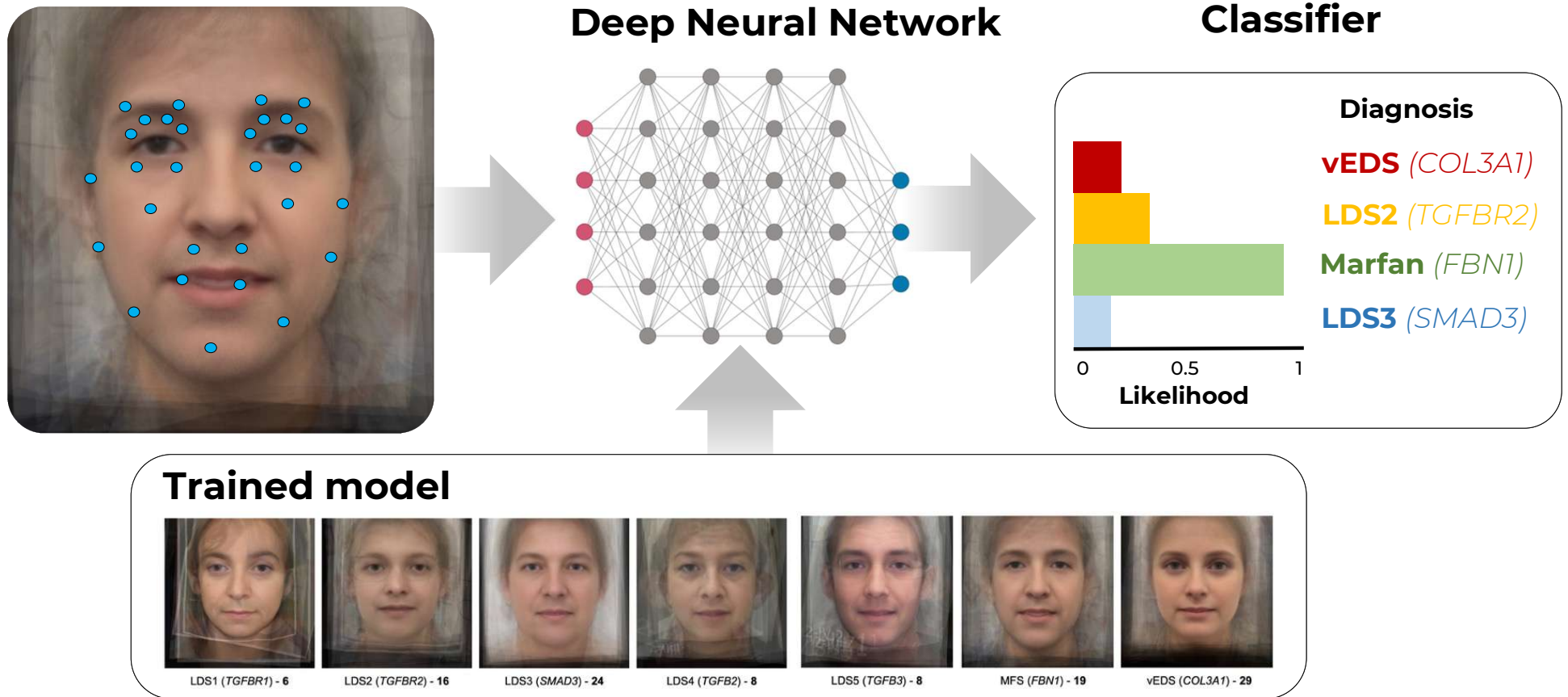


Marfan (*FBN1*)



Vascular EDS (*COL3A1*)


AI-Based Facial Analysis



<https://youtu.be/IGnRqpA55JE>

Goals of AI-Based Facial Analysis

Define **Facial Phenotype Gestalts** for HTAD




<https://youtu.be/IGnRqpA55JE>

Goals of AI-Based Facial Analysis

Define **Facial Phenotype Gestalts** for HTAD

Free accessible platform



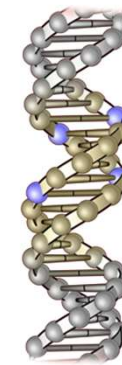
<https://youtu.be/IGnRqpA55JE>

Goals of AI-Based Facial Analysis

Define **Facial Phenotype Gestalts** for HTAD

Free **accessible platform**

Early **diagnosis and management**



Circulation

ACC/AHA CLINICAL PRACTICE GUIDELINE

2022 ACC/ AHA Guideline for the Diagnosis and Management of Aortic Disease: A Report of the American Heart Association/ American College of Cardiology Joint Committee on Clinical Practice Guidelines

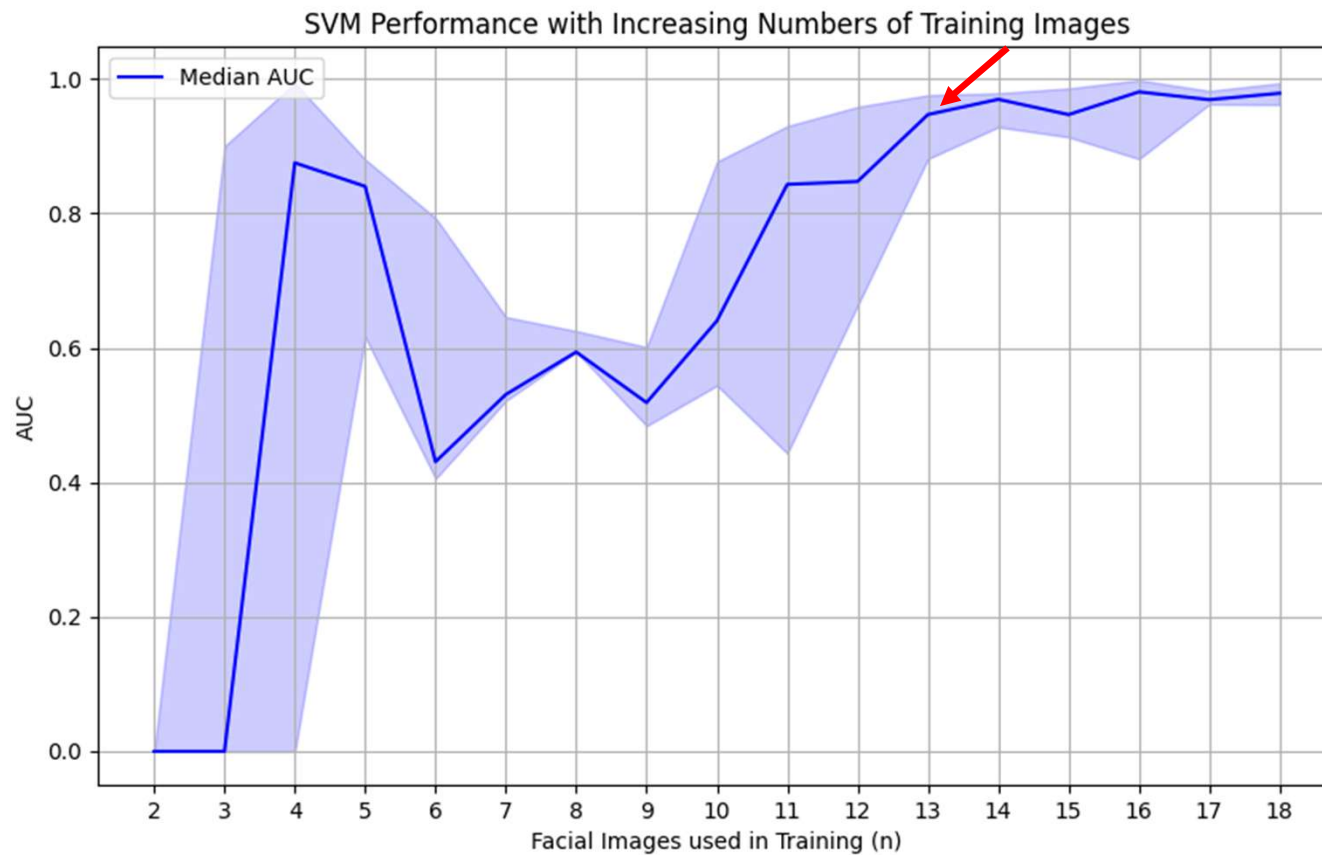
+ **Cardiac Gene Panel: POSITIVE**

Positive result: A heterozygous likely pathogenic variant in FBN1, c.4337A>T (p.Asp1446Val)...

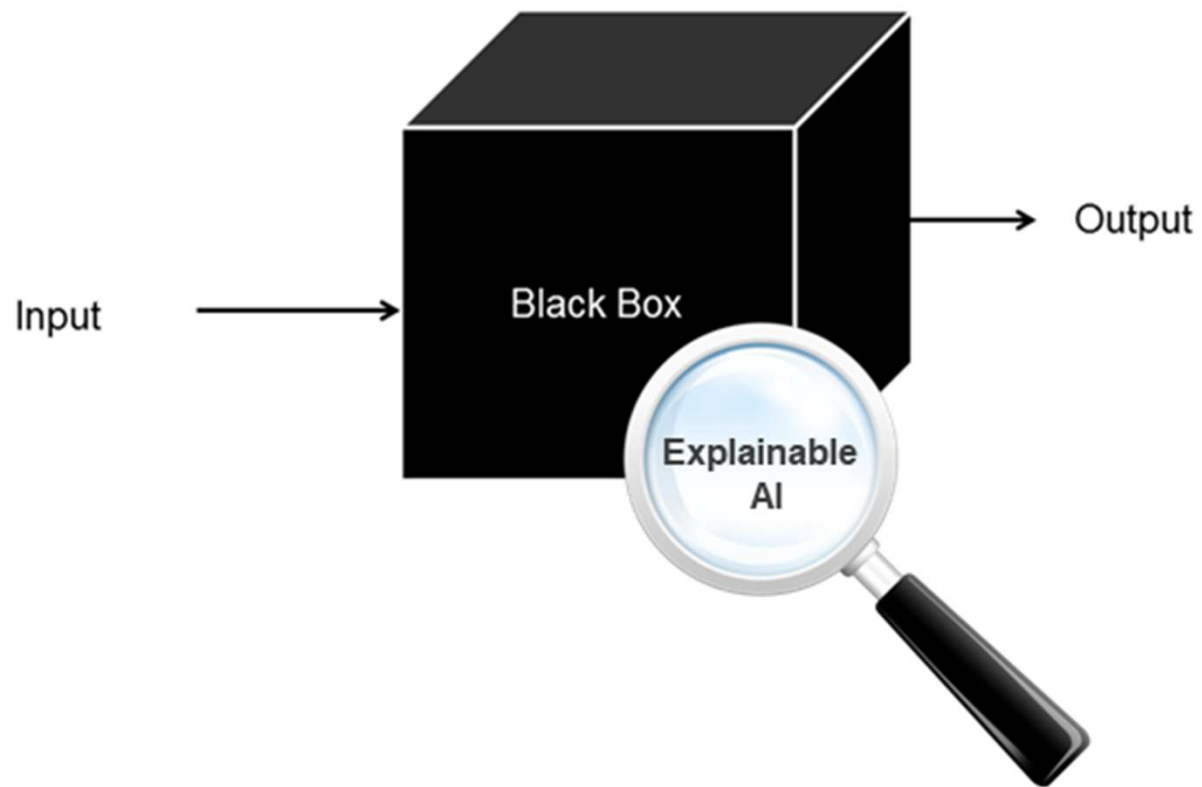
Recommendations: Management of Marfan Syndrome includes medications to reduce hemodynamic stress, surgical interventions of aneurysms and dissections, and surveillance....

<https://youtu.be/IGnRqpA55JE>

How Many Images are Needed?




vEDS: Strong predictive performance (AUC 0.95) with 13 images



Local interpretable model-agnostic explanations (LIME)

- Creates perturbed versions of the input image
- Analyzes how these changes affect the model's predictions
- Highlights which parts of the image most influence the prediction using a heatmap
- **Deep blue areas** = distinguishing features compared to controls



vEDS vs Controls

COL3A1



vEDS vs Controls

Blue areas distinguish vEDS from general population

- Eyes
- Lips
- Nose

vEDS face is distinct from average face

Brier 0.05; **AUC of 0.99**; $P = 2.93 \times 10^{-11}$

vEDS vs hypermobile EDS (hEDS)

COL3A1



vEDS vs hEDS

Blue areas distinguish vEDS from hEDS

- Eyes
- Lips
- Nose

vEDS face is distinct from hEDS face

Brier 0.09; **AUC of 0.97**; $P = 1.12 \times 10^{-19}$



ARTICLE

Early diagnosis of vascular Ehlers-Danlos syndrome through AI-powered facial analysis: Results from the Montalcino Aortic Consortium



David R. Murdock¹ , Adarsh Suresh¹ , Ernesto Calderon Martinez¹ , Isabella Marin¹ , Frances Marin¹, Alan C. Braverman² , Angela T. Yetman³ , Shaine A. Morris⁴ , Dianna M. Milewicz^{1,*}

ARTICLE INFO

Article history:
Received 18 October 2024
Received in revised form
29 April 2025
Accepted 29 April 2025
Available online 9 May 2025

Keywords:
AI-based screening
Facial phenotype analysis
LIME
Machine learning
vEDS

ABSTRACT

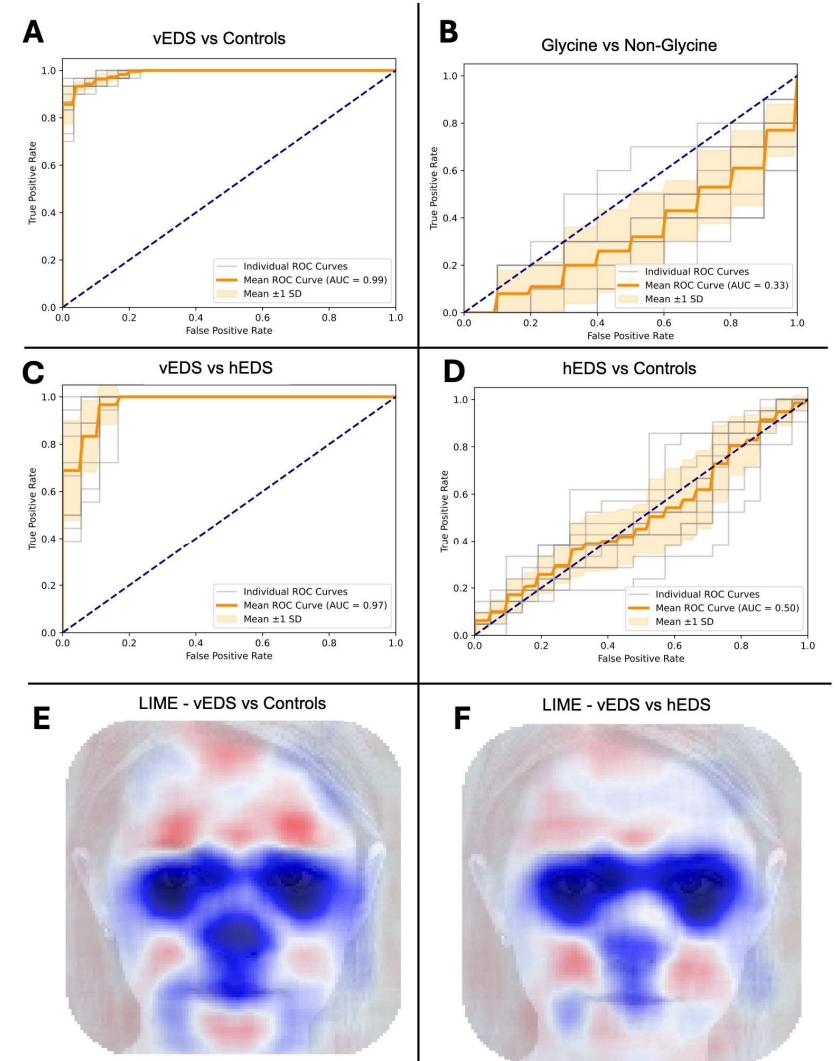
Purpose: Vascular Ehlers-Danlos syndrome (vEDS), which is caused by *COL3A1* pathogenic variants, is a rare heritable aortic and arterial disorder associated with early mortality, mainly due to spontaneous vascular dissections and ruptures. Improved methods for diagnosing vEDS are needed for guideline-based management to be initiated for preventing deadly complications and differentiating vEDS from overlapping conditions, such as hypermobile EDS (hEDS).

Methods: We implemented an artificial intelligence (AI) facial analysis model based on the PhenoScore framework using a support vector machine trained on facial images of 30 individuals, aged 6 to 65 years, with vEDS from the Montalcino Aortic Consortium, control images from the Chicago Face Database, and publicly available images of individuals with hEDS. Cross-validation was used to train the support vector machine, and statistical measures to evaluate the model performance were calculated. Local Interpretable Model-agnostic Explanations was used to generate facial heatmaps highlighting the features driving the model's predictions.

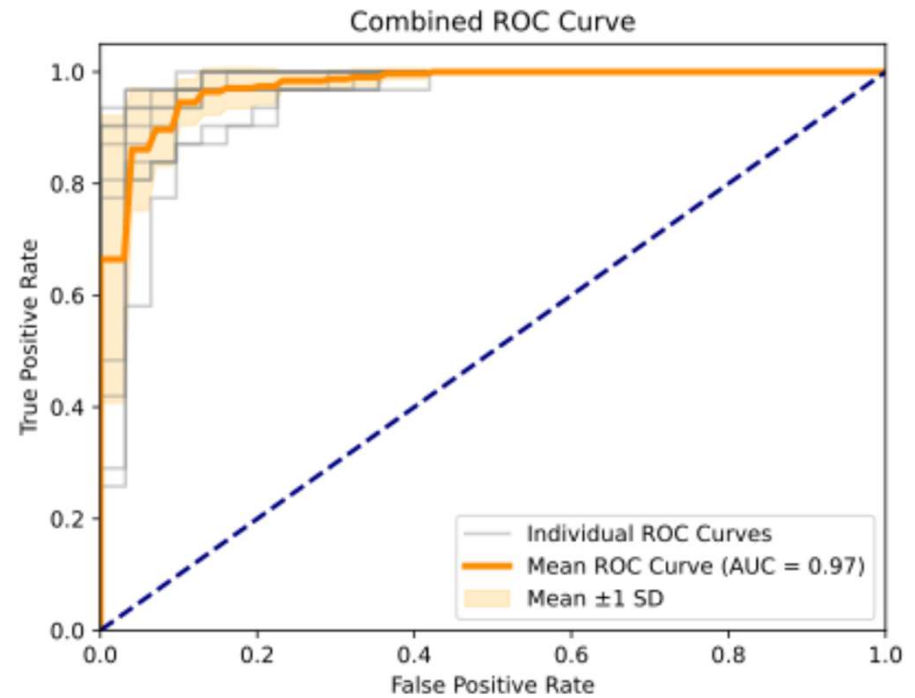
Results: The AI classifier showed excellent performance with as few as 13 vEDS training images and distinguished vEDS from both controls and individuals with hEDS with high accuracy, achieving an area under the receiver operating characteristic curve ≥ 0.97 . Local Interpretable Model-agnostic Explanations highlighted facial regions already established to characterize the facial features of vEDS patients (eg, prominent eyes).

Conclusion: Our results demonstrate the potential of AI-based facial analysis for diagnosing vEDS. This method democratizes the early diagnosis of vEDS by reducing dependence on genetic testing, enabling optimal management and improved outcomes, particularly in resource-limited areas.

© 2025 The Authors. Published by Elsevier Inc. on behalf of American College of Medical Genetics and Genomics. This is an open access article under the CC BY-NC-ND license (<http://creativecommons.org/licenses/by-nc-nd/4.0/>).



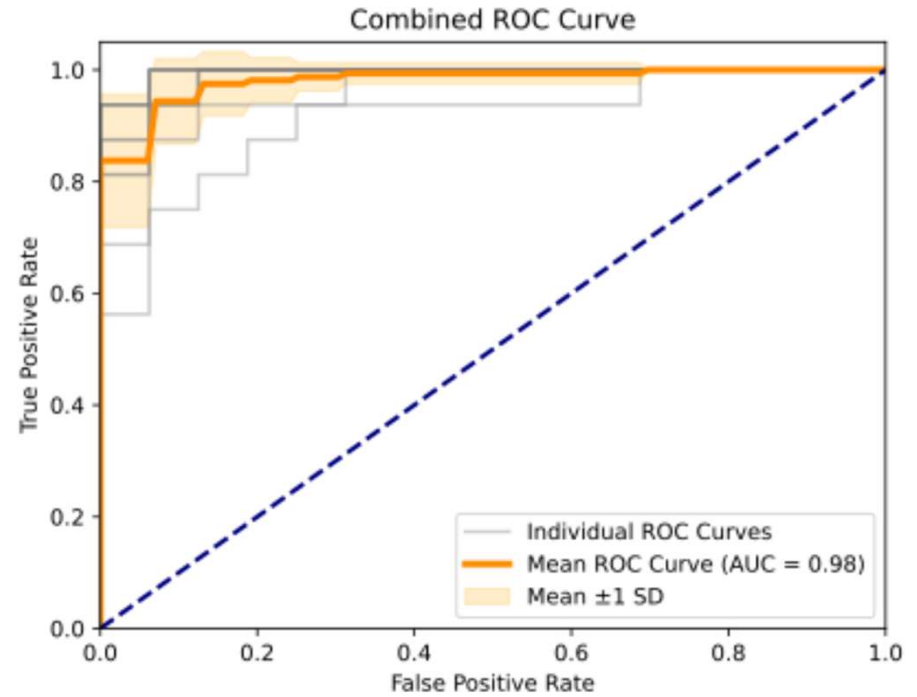

Marfan Syndrome (*FBN1*)



Brier 0.062; **AUC of 0.97**; $P = 6.7 \times 10^{-11}$

Loeys-Dietz Syndrome type 4 (*TGFB2*)

TGFB2



Brier 0.06; **AUC of 0.98**; $P = 6.7 \times 10^{-11}$

Conclusions



- AI-based facial recognition offers a promising approach to early HTAD diagnosis
 - Non-invasive, cost-effective, rapid
 - Useful for non-geneticists and regions with low access to genetic testing
- Limited number of training images needed (13 for vEDS)
- Effectively identifies known HTAD-specific facial features

Pediatrician's Office




158 Cardiac Gene Panel: POSITIVE Details in Section 1

Positive Result: A heterozygous likely pathogenic variant in *FBN1*, c.4337A>T (p.Asp1446Val), was identified in this individual. Defects in *FBN1* are the cause of Marfan syndrome (MFS), an autosomal dominant connective tissue disorder characterized by aortic aneurysms and/or dissections as well as other systemic findings.

Recommendations: Management of Marfan syndrome includes medications to reduce hemodynamic stress, surgical interventions of aneurysms and dissections, and close surveillance of the aorta. Annual ophthalmologic examination is recommended. Avoidance of fluoroquinolone antibiotics is advised. Comprehensive management by a multidisciplinary team including a clinical geneticist, cardiologist, ophthalmologist, orthopedist, and cardiothoracic surgeon is strongly recommended.



Pediatrician's Office



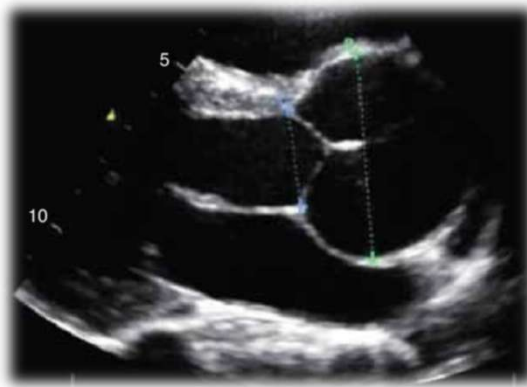Sports Physical



158 Cardiac Gene Panel: POSITIVE Details in Section 1


Positive Result: A heterozygous likely pathogenic variant in FBN1, c.4337A>T (p.Asp1446Val), was identified in this individual. Defects in FBN1 are the cause of Marfan syndrome (MFS), an autosomal dominant connective tissue disorder characterized by aortic aneurysms and/or dissections as well as other systemic findings.

Recommendations: Management of Marfan syndrome includes medications to reduce hemodynamic stress, surgical interventions of aneurysms and dissections, and close surveillance of the aorta. Annual ophthalmologic examination is recommended. Avoidance of fluoroquinolone antibiotics is advised. Comprehensive management by a multidisciplinary team including a clinical geneticist, cardiologist, ophthalmologist, orthopedist, and cardiothoracic surgeon is strongly recommended.



Aortic Aneurysm

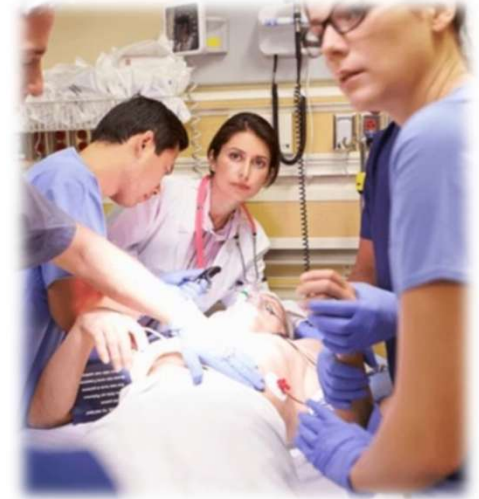Pediatrician's Office



Sports Physical



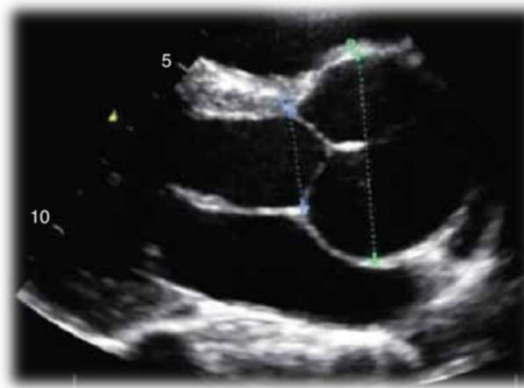
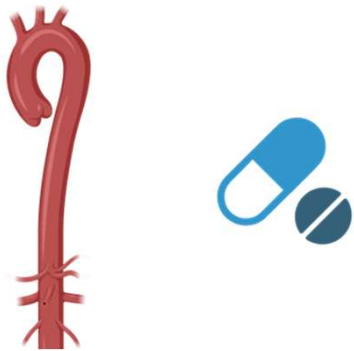
Emergency Room



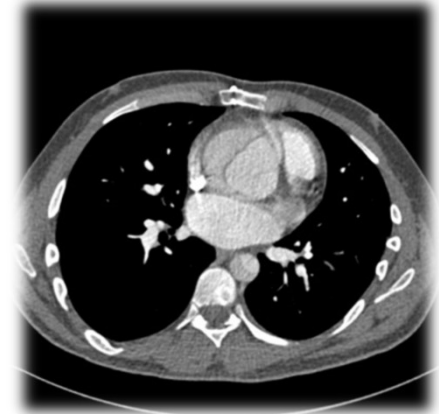158 Cardiac Gene Panel: POSITIVE Details in Section 1

Positive Result: A heterozygous likely pathogenic variant in *FBN1*, c.4337A>T (p.Asp1446Val), was identified in this individual. Defects in *FBN1* are the cause of Marfan syndrome (MFS), an autosomal dominant connective tissue disorder characterized by aortic aneurysms and/or dissections as well as other systemic findings.

Recommendations: Management of Marfan syndrome includes medications to reduce hemodynamic stress, surgical interventions of aneurysms and dissections, and close surveillance of the aorta. Annual ophthalmologic examination is recommended. Avoidance of fluoroquinolone antibiotics is advised. Comprehensive management by a multidisciplinary team including a clinical geneticist, cardiologist, ophthalmologist, orthopedist, and cardiothoracic surgeon is strongly recommended.



Aortic Aneurysm



Aortic Dissection

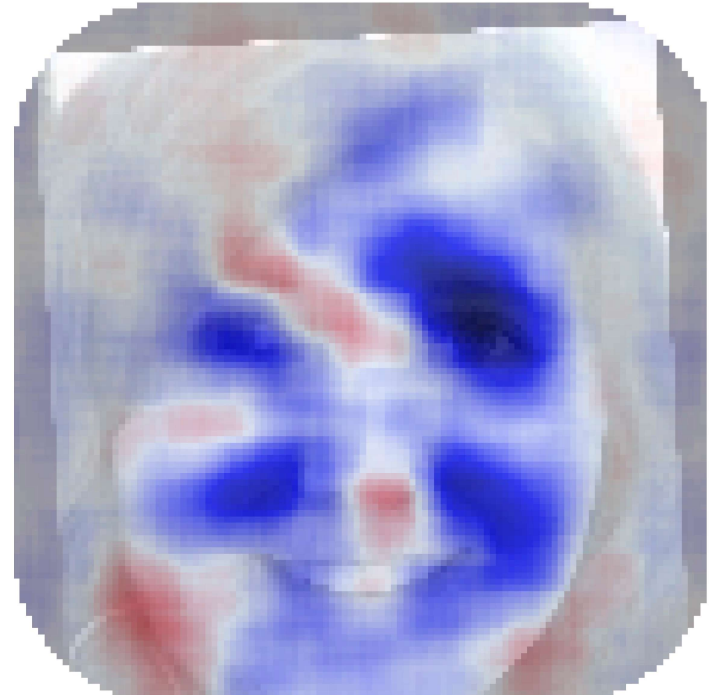


Family of woman who died **speaks out**


CTV News 
2.25M subscribers

[Subscribe](#)

 31   Share  Ask  Save 





93% match for Marfan syndrome



Family of woman who died after undiagnosed Marfan syndrome speaks out

CTV News  2.25M subscribers

Subscribe

 31   Share  Ask  Save 

93% match for Marfan syndrome

Acknowledgements

UT McGovern Medical School

Dianna Milewicz, M.D., Ph.D.
Adarsh Suresh, B.A.
Ernesto Calderon Martinez, M.D.
Siddharth Prakash, M.D., Ph.D.
Alana Cecchi, M.S., C.G.C.
Gopika Rajanikanth, M.S., C.G.C.
Rana Afifi, M.D.
Anthony Estrera, M.D.

MAC Collaborators

Shaine Morris, M.D. (TCH/BCM)
Angela Yetman, M.D. (UNMC)
Alan Braverman, M.D. (WUSTL)

JRF

Isabella Marin
Ellen Hostetler
Meredith O'Neal

Bella's Mission

Francis Marin

Patients and their families for participating in our studies

david.r.murdock@uth.tmc.edu

MAC@uth.tmc.edu

JRRP.research@uth.tmc.edu

Bugher Foundation
Remembrin' Benjamin Fund
Temerty Foundation
Olivia Petrera-Cohen Research Fund

