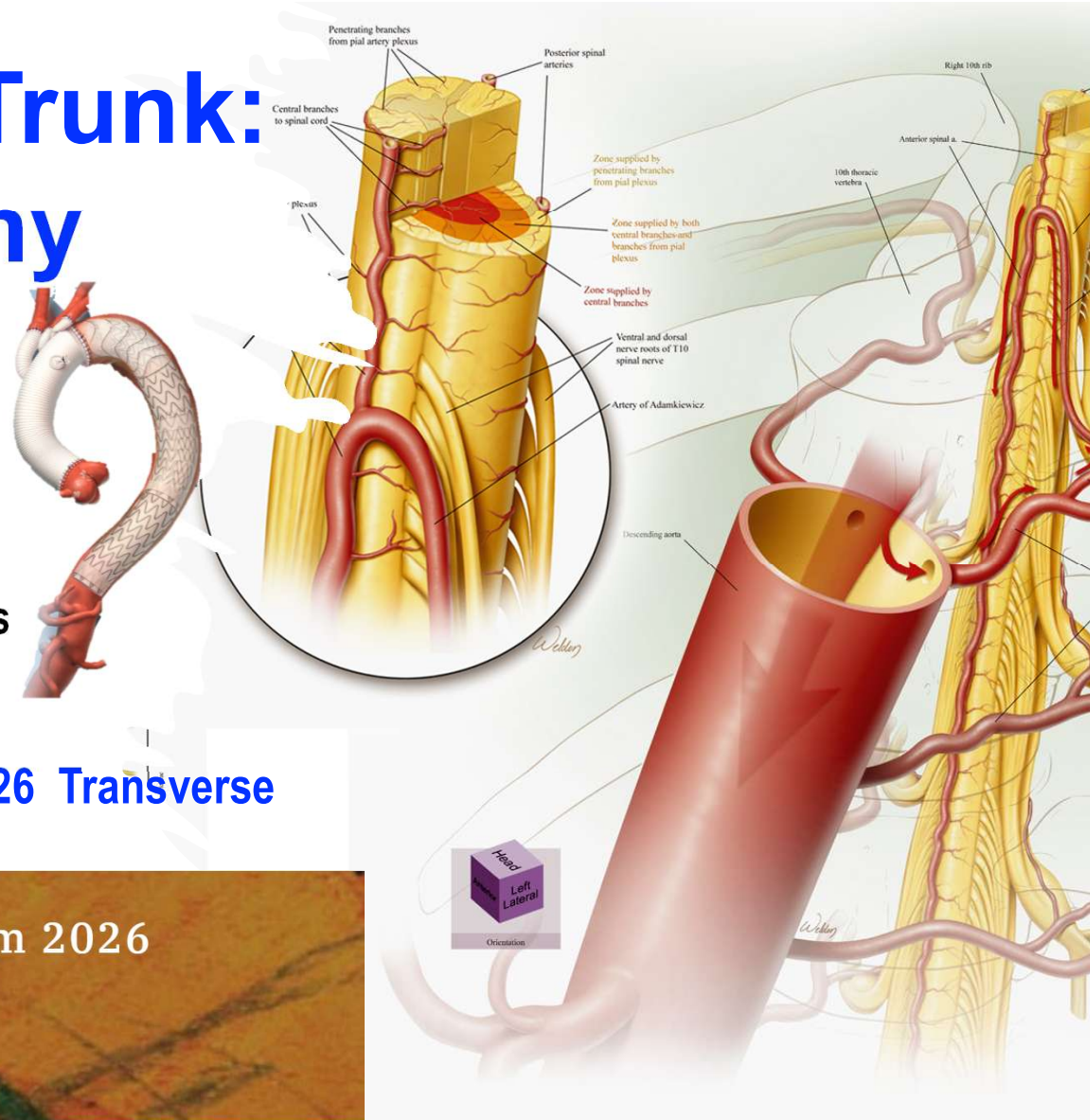


Frozen Elephant Trunk: How Long and Why

Ourania Preventza MD,MBA,FACS, FACC
Professor of Surgery
Heart Surgeons of San Antonio
Past President of
International Society of Endovascular Specialists
(ISEVS) 2021-2023



SESSION III: Aortic Symposium March 5-7 2026 Transverse Arch

The Houston Aortic Symposium 2026

March 5-7, 2026
The Westin Oaks, Houston, Texas



The Houston Aortic Symposium 2026

March 5-7, 2026

The Westin Oaks, Houston, Texas

Frozen Elephant Trunk: How Long and Why

Disclosures

Consultant

W. L. Gore and Associates

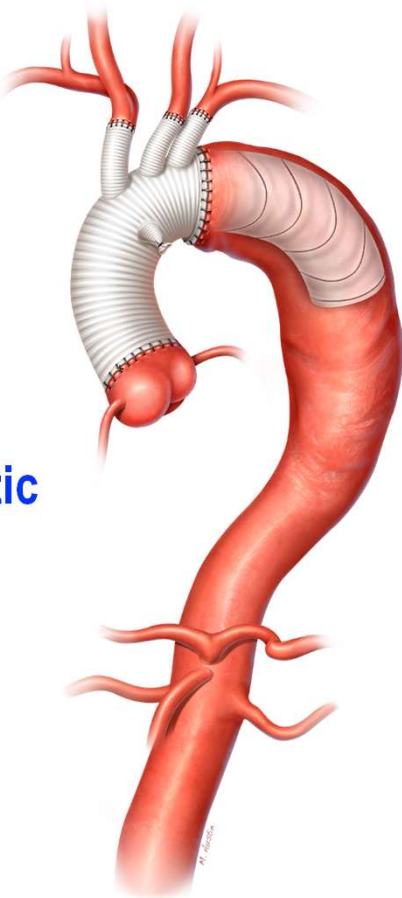
Terumo

Intressa Vascular

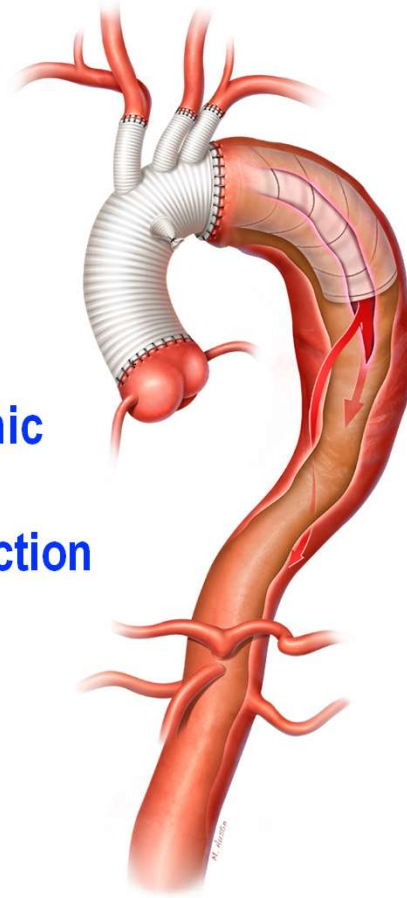
Artivion

Use of FET : Extensive aortic disease

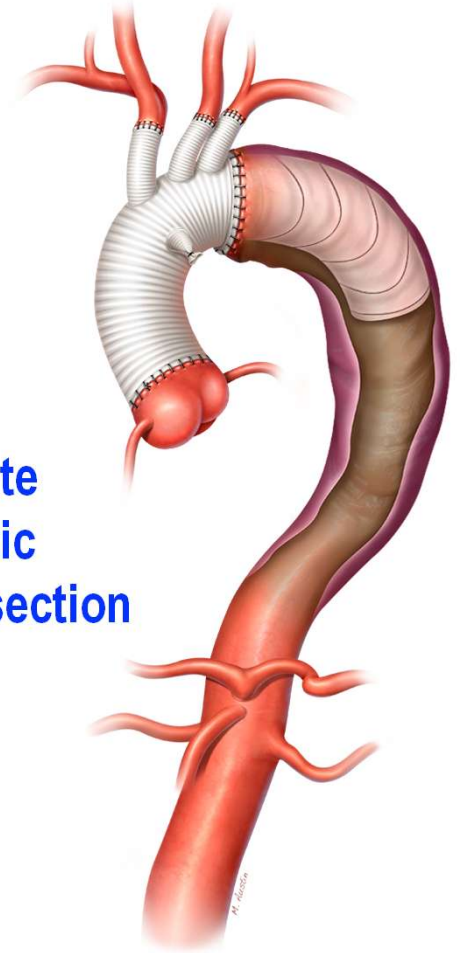
**Aneurysm
without aortic
dissection**



**Chronic
aortic
dissection**



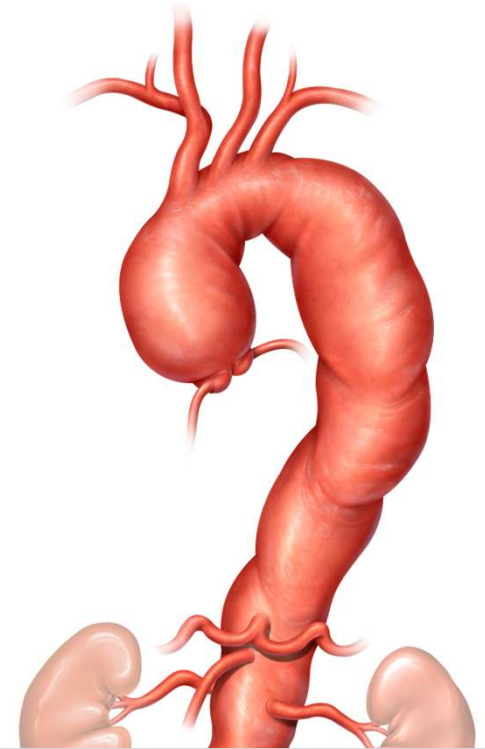
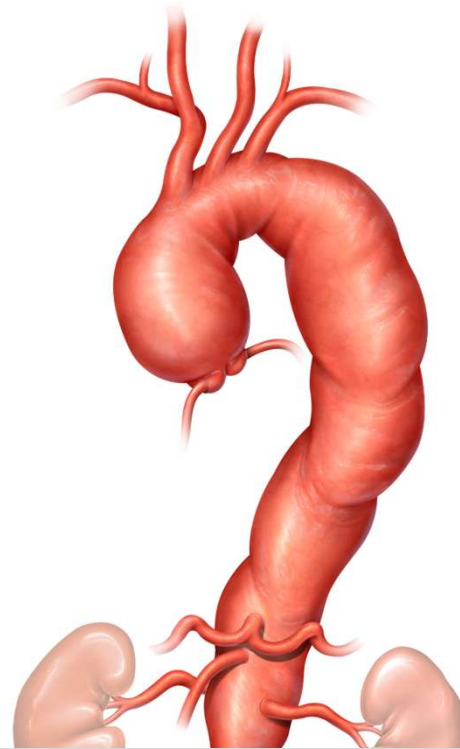
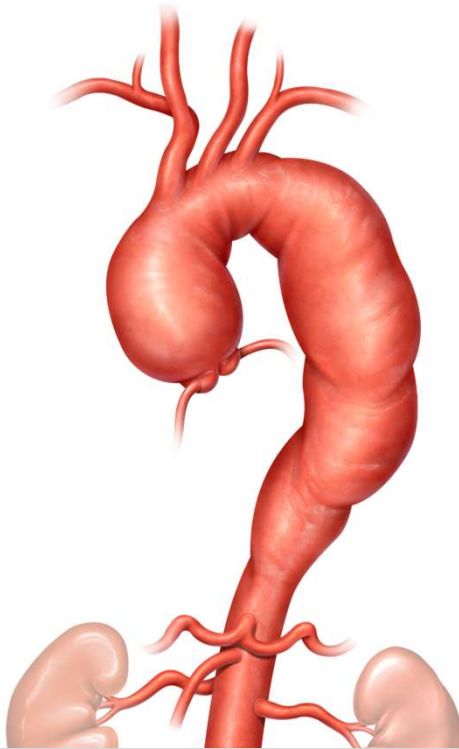
**Acute
aortic
dissection**



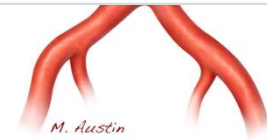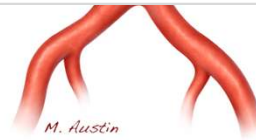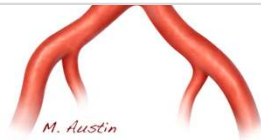Use of FET : Extensive aortic disease

Purpose

- **One-Stage Repair**
- **Stabilization of Aortic Dissections/ expansion of the true lumen/ promoting healing and remodeling and preventing ruptures**
- **Creation of an Ideal Landing Zone (for future endografts) to treat residual disease or de novo disease in the distal aorta**
- **Malperfusion management/ expansion of true lumen**

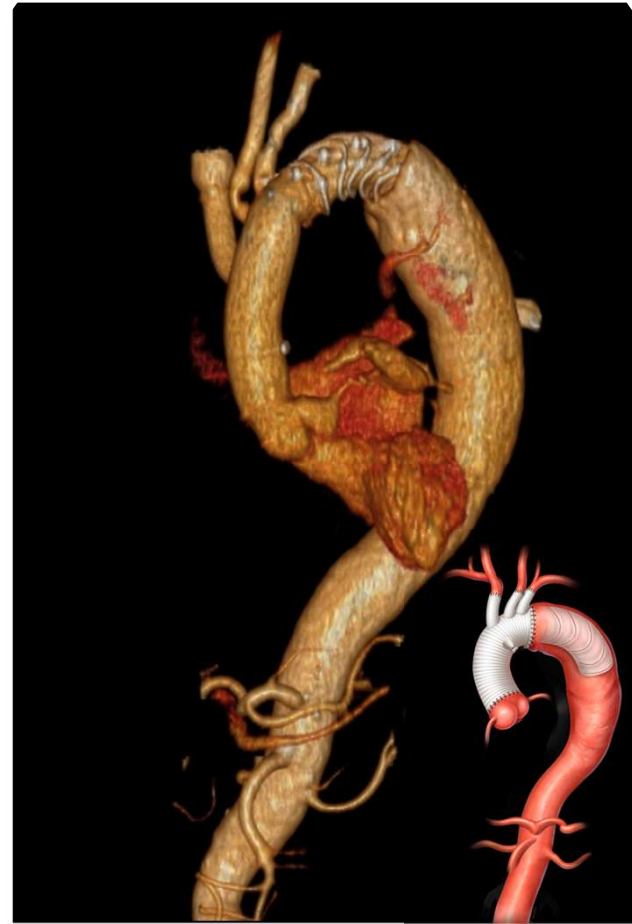


The individual Patient Determines Arch Approach and not the pathology



As we are using these new FET devices / and or procedures associated with these devices

- **It is important to implement innovation by maintaining or lowering the current level of clinical or operational risk**
 - **Safe**
 - **Controlled**
 - **Evidence based**



Neurologic complications after the frozen elephant trunk procedure: A meta-analysis of more than 3000 patients

Ouranía Preventza, MD,^{a,b} Jane L. Liao, MD,^a Jacqueline K. Olive, BA,^a Katherine Simpson, MS,^a Andre C. Critsinelis, MD,^c Matt D. Price, MS,^{a,d} Marianne Galati, MSW, MLS,^e Lorraine D. Cornwell, MD,^{a,d} Vicente Orozco-Sevilla, MD,^{a,b} Shuab Omer, MD,^{a,f} Ernesto Jimenez, MD,^{a,f} Scott A. LeMaire, MD,^{a,b,d} and Joseph S. Coselli, MD^{a,b}

ABSTRACT

Objective: The frozen elephant trunk technique's safety regarding spinal cord ischemia has been questioned. We used a meta-analysis to determine the rates of adverse neurologic events and mortality.

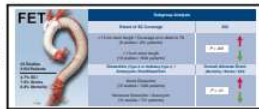Methods: We searched PubMed/Medline, Embase, Scopus, and Cochrane databases (inception to April 2018) to identify studies of neurologic events after the frozen elephant trunk procedure. Separate meta-analyses were conducted with random-effects models to assess frozen elephant trunk associations with spinal cord ischemia, stroke, operative mortality, and all adverse events combined. Subgroup analyses compared outcomes in patients with acute versus nonacute type A dissection and aneurysm and with different extents of coverage.

Results: Thirty-five studies (total N = 3154) met inclusion criteria. The pooled rates of the outcomes of interest were 4.7% (95% confidence interval, 3.5-6.2) for spinal cord ischemia, 7.6% (95% confidence interval, 5.0-11.5) for stroke, and 8.8% (95% confidence interval, 7.0-10.9) for operative mortality. The spinal cord ischemia event rate was higher with stent length 15 cm or greater or coverage to T8 or beyond than with stent length of 10 cm (11.6% vs 2.5%, $P < .001$). Adverse event rates in patients with acute type A aortic dissection versus nonacute dissection or aneurysm were as follows: mortality 9.2% versus 7.6% ($P = .46$), stroke 9.3% versus 6.6% ($P = .51$), and overall adverse events 22.0% versus 16.5% ($P = .41$).

Conclusions: As the frozen elephant trunk procedure becomes more popular, accurate data regarding outcomes are vital. We associated the frozen elephant trunk technique with (nonsignificantly) more adverse events overall in acute type A dissection cases. Stent length of 10 cm was associated with significantly less risk of spinal cord ischemia. Using a stent 15 cm or greater or coverage extending to T8 or farther should be avoided. (*J Thorac Cardiovasc Surg* 2020;160:20-33)

Traditionally, the elephant trunk (ET) procedure involves 2 stages, and the likelihood of death before the second stage is high.¹⁻⁶ The frozen elephant trunk (FET) procedure is a newer approach designed to treat extensive pathology of

the thoracic aorta in a single stage or by facilitating the second stage of a 2-stage procedure.⁷ Single-center institutional experiences and small series comprise most of the existing reports.⁸



Visual summary of our meta-analysis of 35 FET studies, with results and subgroup analyses.

Central Message

In FET, 10-cm stent length is advisable; length 15 cm or greater or coverage to or beyond T8 should be avoided to prevent SCI. FET should be used cautiously for acute type A aortic dissection.

Perspective

This meta-analysis of 35 observational studies examines mortality and neurologic outcomes associated with the FET technique in patients who require total arch replacement. Currently, the results represent the best available evidence regarding the outcomes of FET in such patients. Judicious use of the technique is advisable.

See Commentaries on pages 34 and 35.



AATS

@AATSHQ · Follow



2021 most downloaded #AdultCardiac article from JTCVS:
jtcvs.org/article/S0022-... #AATSFoundersDay
 @AATSJournals @OPreventzaMD
 @scottlemaire

Celebrating AATS Founders Day | June 7, 1917

2021 Top Cited Adult Cardiac Article from JTCVS

*Neurologic complications after the frozen elephant trunk procedure:
 A meta-analysis of more than 3000 patients*

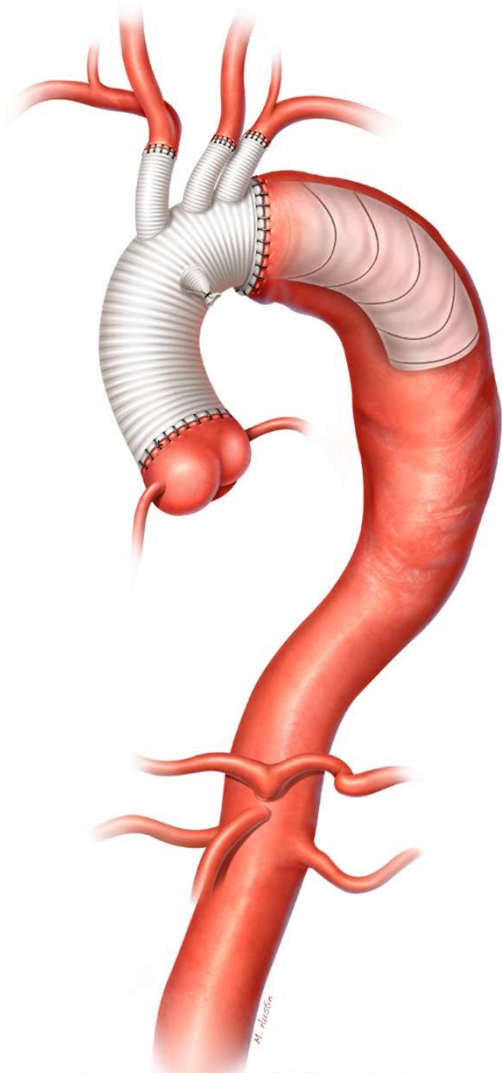
Ouranía Preventza, Jane L. Liao, Jacqueline K. Olive, Katherine Simpson, Andre C. Critsinelis, Matt D. Price, Marianne Galati, Lorraine D. Cornwell, Vicente Orozco-Sevilla, Shuab Omer, Ernesto Jimenez, Scott A. LeMaire, Joseph S. Coselli

CONGRATULATIONS TO OUR AUTHORS



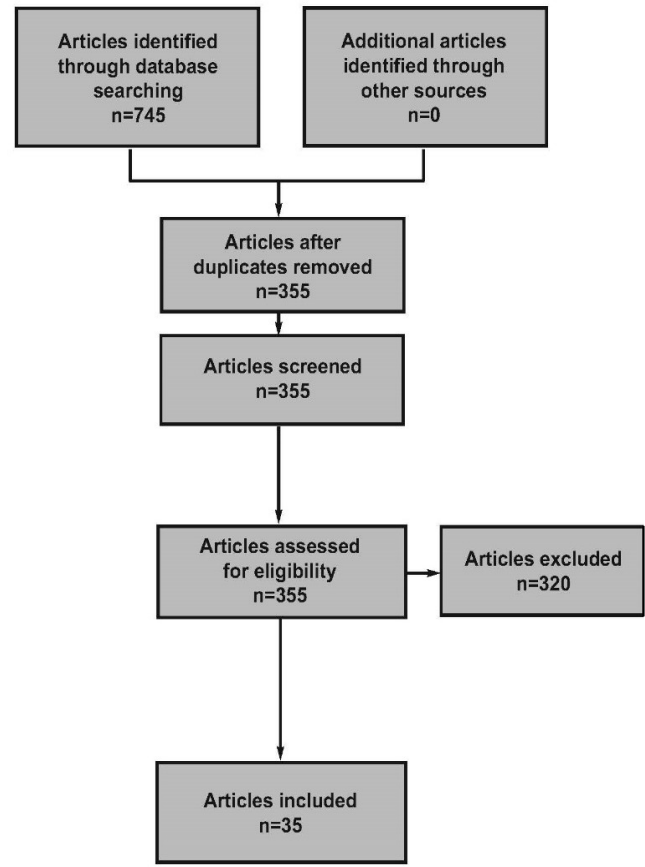
AATS
 Vision. Leadership.
 Scholarship.

Preventza et al : J Thorac Cardiovasc Surg. 2020
 Jul;160(1):20-33



Preventza et al : JTCVS 2020

Identification
Screening
Eligibility
Included

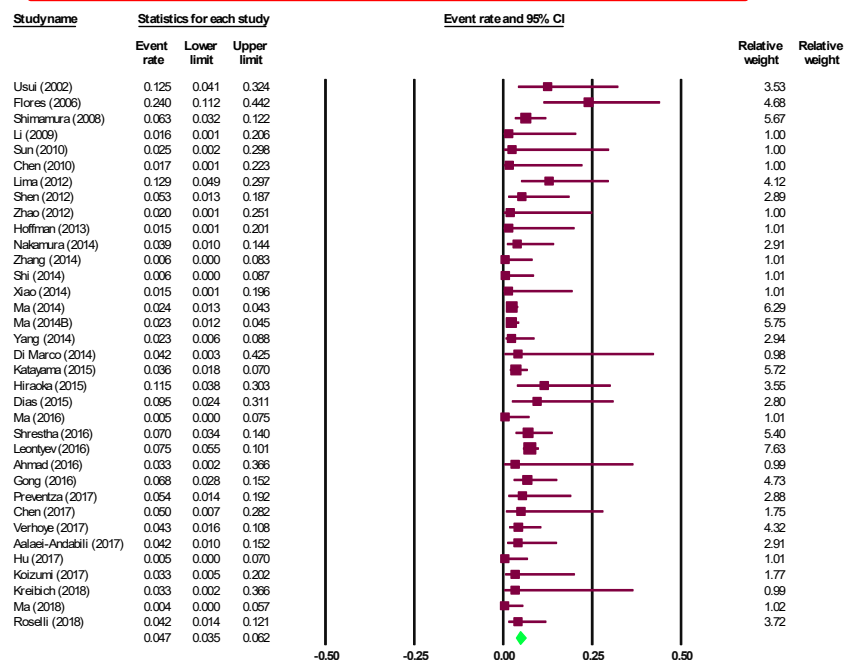


3154 pts

Neurologic complications after the frozen elephant trunk procedure: A meta-analysis of more than 3000 patients

SPINAL CORD ISCHEMIA

OVERALL SCI, PARALYSIS



Neurologic complications after the frozen elephant trunk procedure: A meta-analysis of more than 3000 patients

Preventza et al : JTCVS 2020

Pool rate 4.7% (95% CI, 3.5%-6.2%)

Spinal Cord Ischemia

Moderator variables	Number studies in the analysis	Coefficient	p-value	Goodness of fit I-squared (p-value)	R-squared
Stent >15 cm, coverage more than T8	30	0.92	0.031	34.13 (0.039)	0.38

Neurologic complications after the frozen elephant trunk procedure: A meta-analysis of more than 3000 patients

Analysis of Spinal Cord Infarction Associated with Aortic Stent Graft Placement Using Nationwide Inpatient Sample (2002-2011)

Adnan I Qureshi¹, Morad Chughtai¹, Ahmed A Malik¹

Affiliations: [collapse](#)

305,788 patients who underwent aortic stent graft placement

Patients with spinal cord infarction

had significantly higher odds of in hospital mortality

([odd ratio] OR: 3.0; 95% confidence interval [CI]: 2.4-3.8)

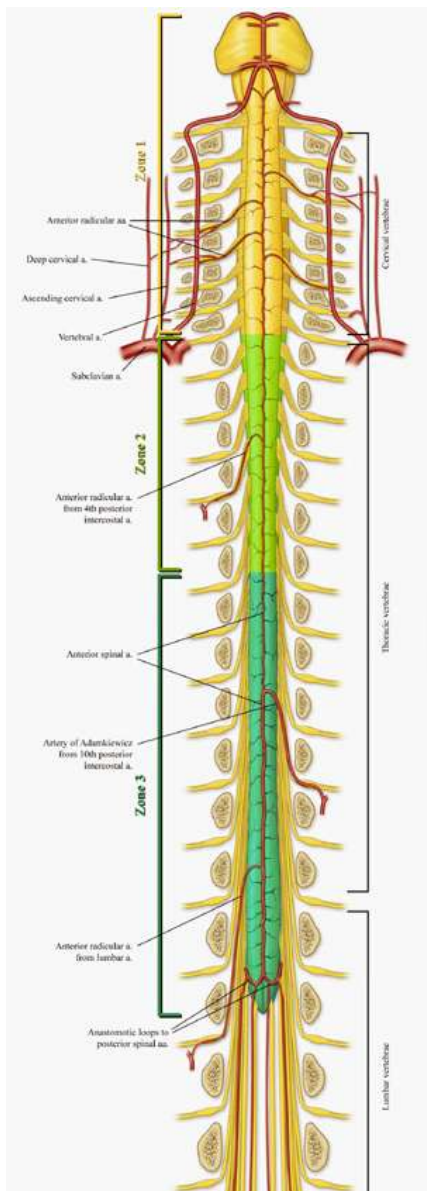
Among those who were discharged alive, patients who developed spinal cord infarction had significantly higher odds of moderate to severe disability

(OR: 2.8; 95% CI: 2.5-3.2)

([odd ratio] OR: 3.0; 95% confidence interval [CI]: 2.4-3.8) after adjusting for age, gender, race/ethnicity, aortic aneurysms, thoracic graft, hypertension, ischemic strokes or transient ischemic attacks, coagulopathy, congestive heart failure, deficiency or chronic blood loss anemia, atrial fibrillation, renal failure, elective admission, and teaching hospital status. Among those who were discharged alive, patients who developed spinal cord infarction had significantly higher odds of moderate to severe disability (OR: 2.8; 95% CI: 2.5-3.2).

Conclusions: The occurrence of spinal cord infarction in patients undergoing aortic stent graft placement appears to be increasing. Spinal cord infarction is associated with prominently higher rates of death and moderate to severe disability.

**J Vasc Interv Neurol 2016
Jan;8(5):9-16.**



JTCVS
 The Journal of Thoracic and Cardiovascular Surgery

Articles Publish Topics Multimedia About Contact

ADULT AORTA | VOLUME 164, ISSUE 6, P1681-1692.E2, DECEMBER 2022

Comparative study of Japanese frozen elephant trunk device for open aortic arch repairs

Hitoshi Ogino, MD, PhD • Yutaka Okita, MD, PhD • Naomichi Uchida, MD, PhD • Masaaki Kato, MD, PhD • Shinji Miyamoto, MD, PhD • Hitoshi Matsuda, MD, PhD • Michikazu Nakai, PhD • J-Open Cardiac Aortic Arch Disease Replacement Surgical Therapy Study Investigators • Show less • Show footnotes

Open Access • Published: March 31, 2021 • DOI: <https://doi.org/10.1016/j.jtcvs.2021.03.079> • Check for updates

Abstract
 Graphical abstract
 Key Words

Abstract

Objective

We performed a multicenter prospective comparative study to determine the impact of a Japanese frozen elephant trunk device on total arch replacement compared with conventional repair without it.

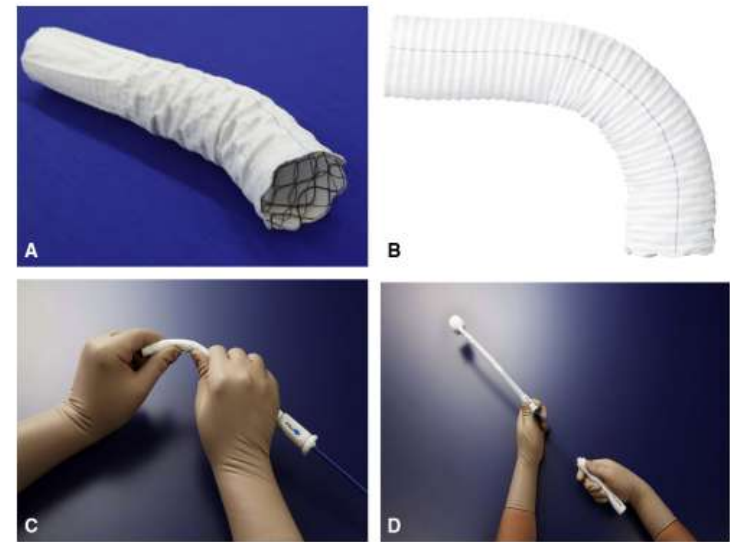
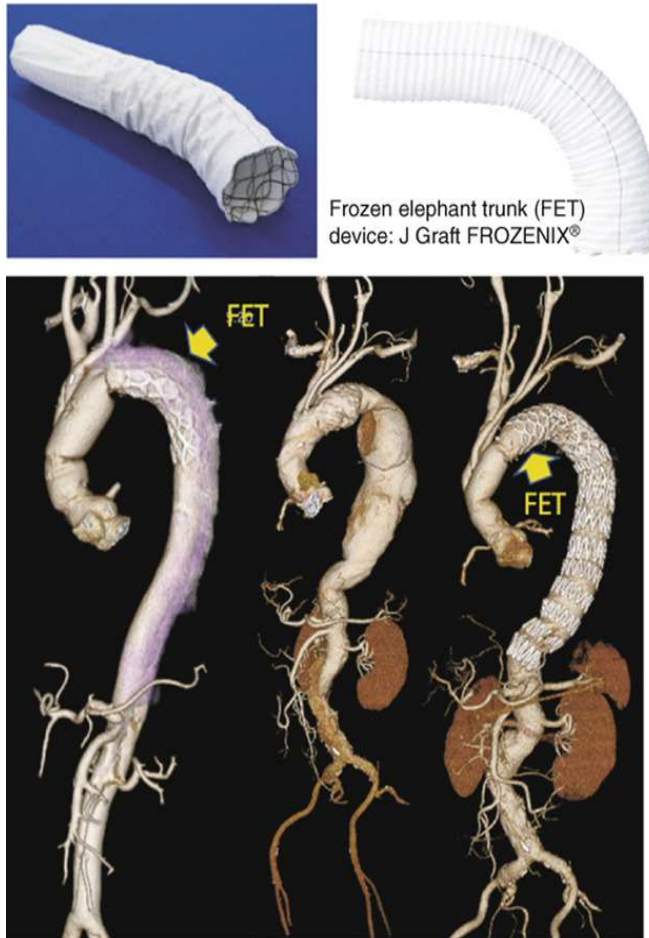


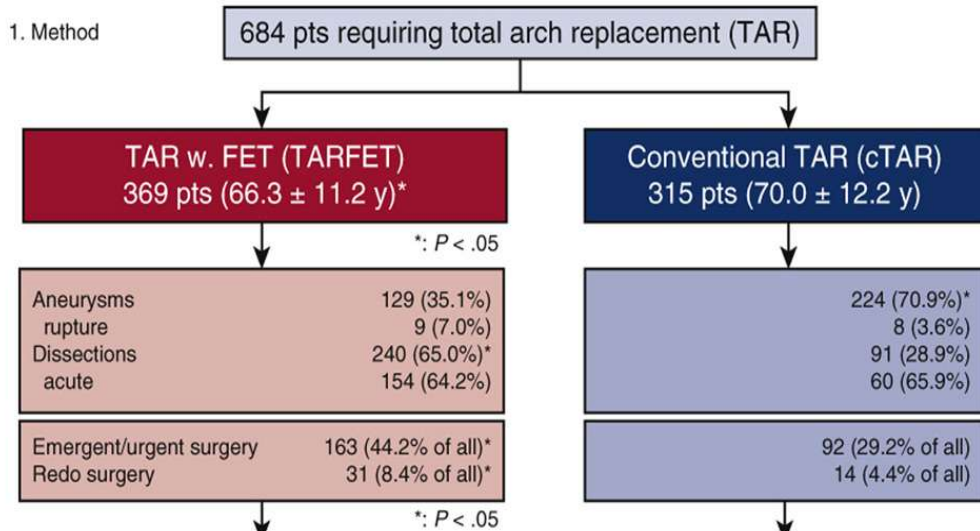
FIGURE 1. J Graft FROZENIX (Japan Lifeline Co, Tokyo, Japan). A and B, The FET consists of 2 parts of the graft part and the stent part. The graft part is a polyester woven Dacron graft with permeability of less than 500 mL/cm²/min (at 120 mm Hg, and in water at 37°C) and a thickness of 450 μm. The stent part has a woven structure made of Nitinol wire, a super-elastic/shape-memory alloy. The stent part is fixed to the inside of the graft to protect the stent part from directly coming in contact with the vessel wall. C and D, The stent part also has a structure such that its wire top hardly protrudes inward when the device is bent. The delivery system consists of 2 elements: the resin shaft and soft sheath.

Ogino et al :
 The Journal of Thoracic and Cardiovascular Surgery 2022 164:1681-1692.e2DOI: (10.1016/j.jtcvs.2021.03.079)

Comparative study of Japanese frozen elephant trunk device for open aortic arch repairs



1. Method



2. Result

Unadjusted analysis : Propensity score matching adjusted one (n = 194, each)

Outcome	TARFET (n, %)	cTAR (n, %)
30-day mortality	3 (0.8%) : 0 (0%)	1 (0.3%) : 0 (0%)
In-hospital mortality	6 (1.6%) : 2 (1.0%)	2 (0.6%) : 0 (0%)
Stroke	21 (5.7%)* : 9 (4.6%)	7 (2.2%) : 3 (1.5%)
Paraplegia	6 (1.6%)* : 1 (0.5%)	0 (0%) : 0 (0%)
Paraparesis	7 (1.9%) : 5 (2.6%)	1 (0.3%) : 1 (0.5%)

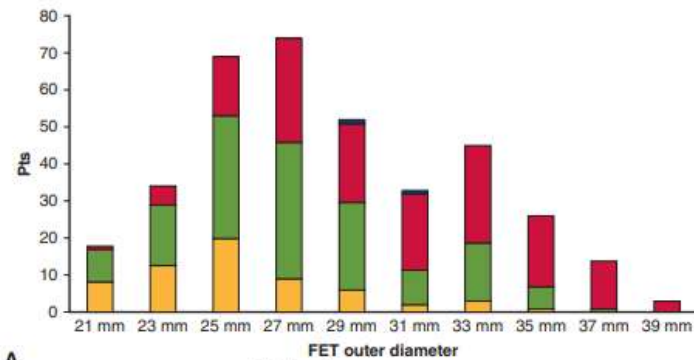
*: P < .05

3. Implications

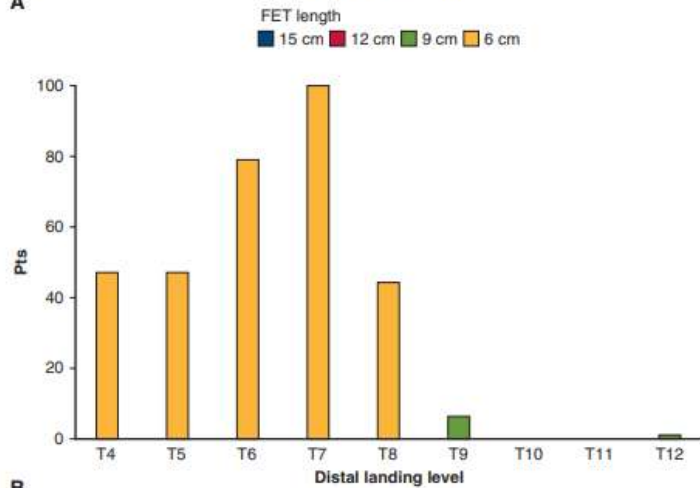
Compared with cTAR, TARFET was applied more to aortic dissection and the outcome was acceptable despite its higher prevalence of emergency or redo surgery. TARFET had higher rates of spinal cord injury, which is a disadvantage of this approach.

Oginio et al :

The Journal of Thoracic and Cardiovascular Surgery 2022 1641681-1692.e2DOI: (10.1016/j.jtcvs.2021.03.079)



A



B

FIGURE 2. A, Size of FET in use. The majorities of FET device in clinical use were 9 and 12 cm in length and 25, 27, 29 mm in diameter. B, Distal landing zone/level of FET. The landing levels of FET distal end were almost above the T8 level, except for 7 patients: T9 in 6 and T12 in 1. *FET*, Frozen elephant trunk; *T*, thoracic vertebra.

Insert 9-12 cm in length

The landing levels of FET distal end were almost above the T8 level, except for 7 patients
 T9 in 6
 T12 in 1

Oginio et al :

The Journal of Thoracic and Cardiovascular Surgery 2022 1641681-1692.e2DOI: (10.1016/j.jtcvs.2021.03.079)

ADULT: AORTA | VOLUME 164, ISSUE 6, P1681-1692.E2, DECEMBER 2022

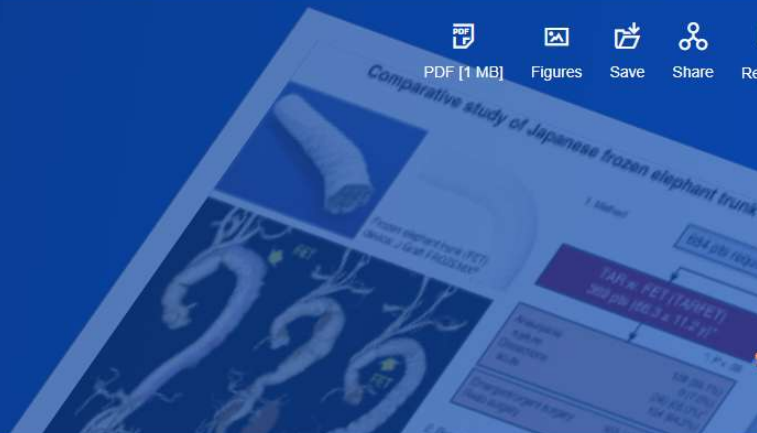Comparative study of Japanese frozen elephant trunk device for open aortic arch repairs

Hitoshi Ogino, MD, PhD • Yutaka Okita, MD, PhD • Naomichi Uchida, MD, PhD • Masaaki Kato, MD, PhD • Shinji Miyamoto, MD, PhD • Hitoshi Matsuda, MD, PhD • Michikazu Nakai, PhD • J-Open Cardiac Aortic Arch Disease Replacement Surgical Therapy Study Investigators • Show less

Show footnotes

Open Access • Published: March 31, 2021 • DOI: <https://doi.org/10.1016/j.jtcvs.2021.03.079>

 Check for updates



Abstract

Graphical abstract

Key Words

Abstract

Objective

We performed a multicenter prospective comparative study to determine the impact of a Japanese frozen elephant trunk device on total arch replacement compared with conventional repair without it.

“This procedure had higher rates of spinal cord injury than the conventional repair, which is a disadvantage of this approach”

Multicenter Study > J Thorac Cardiovasc Surg. 2020 Apr;159(4):1189-1196.e1.
doi: 10.1016/j.jtcvs.2019.03.097. Epub 2019 Apr 14.

Frozen elephant trunk does not increase incidence of paraplegia in patients with acute type A aortic dissection

Shi Sum Poon¹, David H Tian², Tristan Yan³, Deborah Harrington¹, Omar Nawaytou¹, Manoj Kuduvalli¹, Axel Haverich⁴, Marek Ehrlich⁵, Wei-Guo Ma⁶, Li-Zhong Sun⁶, Anthony L Estrera⁷, Mark Field⁸; International Aortic Arch Surgery Study Group

Affiliations + expand

PMID: 31126657 DOI: 10.1016/j.jtcvs.2019.03.097

[Free article](#)

Abstract

Objective: We seek to assess the safety of total arch replacement with frozen elephant trunk for acute type A aortic dissection in respect to the risks of operative mortality, stroke, and paraplegia using an international multicenter registry (ARCH).

Methods: The ARCH Registry database from 37 participating centers was analyzed between 2000 and 2015. Patients who underwent emergency surgery for acute type A aortic dissection treated by total arch replacement with or without frozen elephant trunk were included. Operative mortality, permanent neurologic deficits, and spinal cord injury were primary end points. These end points were analyzed using univariate and hierarchical multivariate regression analyses, as well as conditional logistic regression analysis and post hoc propensity-score stratification.

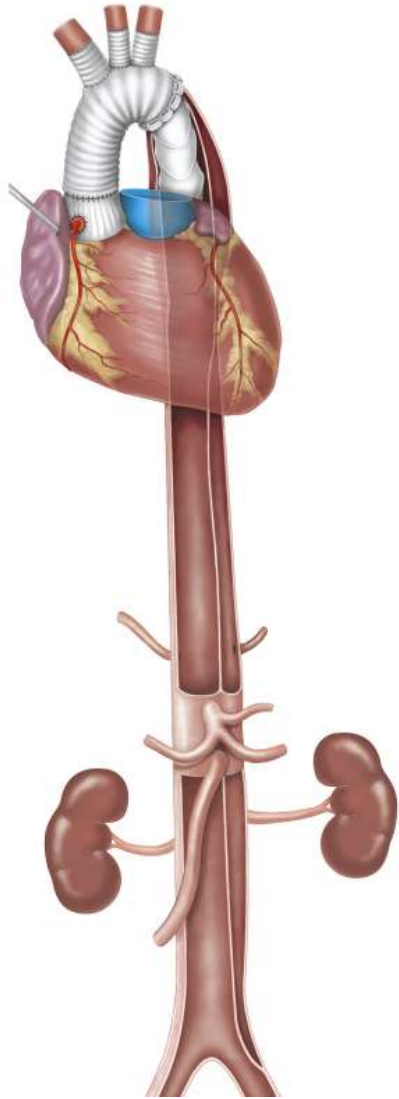Results: A total of 11,928 patients were enrolled in the ARCH database, of which 6180 were managed with total arch replacement. A comprehensive analysis was performed for 978 patients who underwent total aortic arch replacement for acute type A aortic dissection with or without frozen elephant trunk placement. In propensity-score matching, there were no significant differences between total arch replacement and frozen elephant trunk in terms of permanent neurologic deficits (11.9% vs 10.1%, $P = .59$) and spinal cord injury (4.0% vs 6.3%, $P = .52$). For patients included in the post hoc propensity-score stratification, frozen elephant trunk was associated with a statistically

Emergency TAR between 2000 and 2015 for acute type A dissection, either with or without a FET,

**Neuroprotection approaches [hypothermic circulatory arrest \(HCA\) alone](#)
[HCA with antegrade cerebral perfusion \(ACP\)](#)
[HCA with retrograde cerebral perfusion](#)
[HCA with ACP and retrograde cerebral perfusion](#)**

with varying extent of circulatory arrest temperature

Shi Sum Poon et al : (International Arch Surgery Study Group)
The Journal of Thoracic and Cardiovascular Surgery 2020



A total of 11,928 patients were enrolled in the ARCH database, of which 6180 were managed with total arch replacement, **978 for acute Type A aortic dissection with or without FET**

In propensity-score matching, there were no significant differences between total arch replacement and frozen elephant trunk in terms of **permanent neurologic deficits (11.9% vs 10.1%, P = .59)** and **spinal cord injury (4.0% vs 6.3%, P = .52)**

The addition of a FET in TAR is safe and does not increase the incidence of paraplegia



Long-term outcomes of the frozen elephant trunk procedure: a systematic review

2020

David H. Tian^{1,2}, Hakeem Ha¹, Yashutosh Joshi¹, Tristan D. Yan^{1,3}

¹Collaborative Research (CORE) Group, Macquarie University, Sydney, Australia; ²Department of Anaesthesia and Perioperative Medicine, Westmead Hospital, Sydney, Australia; ³Department of Cardiothoracic Surgery, Royal Prince Alfred Hospital, Sydney, Australia
Correspondence to: Dr. David H. Tian, Collaborative Research (CORE) Group, Macquarie University, Balaclava Rd, Macquarie Park, NSW 2109, Australia. Email: drdavidtian@gmail.com.

Background: The frozen elephant trunk (FET) procedure remains an increasingly popular approach to address complex multi-segmental aortic pathologies, owing to their ability to promote false lumen thrombosis and reduce the need for second-stage operations. While the short-term outcomes of such procedures have been shown to be acceptable, much less is known regarding long-term outcomes. This systematic review evaluates long-term outcomes of the FET procedure.

Methods: Studies with at least 12 months follow-up data on FETs were identified in four electronic databases. All studies were reviewed by two independent researchers and relevant data extracted. Long-term outcomes, including overall survival, freedom from reintervention, and freedom from aortic events, were evaluated using patient data recreated from digitized Kaplan-Meier curves.

Results: Thirty-seven studies with 4,178 patients were identified. The majority of the studies focused solely on acute dissections. Average follow-up was 3.2 years. Overall survival at 1-, 3-, and 5-year was 89.6%, 85.2%, and 82.0%, respectively. Freedom from reintervention at the same timepoints were 93.9%, 89.3%, and 86.8%, respectively. Mortality, permanent neurological deficit and spinal cord injury were 10.2%, 7.7%, and 6.5%, respectively.

Conclusions: Survival after the FET procedure is favorable, though ongoing close serial monitoring is essential to assess for the need for further reintervention. Larger multi-institutional registries are required to provide more robust evidence to better elucidate the patient cohort that would most benefit from the FET.

Keywords: Frozen elephant trunk (FET); stent-graft; survival; freedom from reintervention; systematic review



Submitted Feb 03, 2020. Accepted for publication Feb 24, 2020.
doi: 10.21037/acs.2020.03.08

View this article at: <http://dx.doi.org/10.21037/acs.2020.03.08>

Introduction

Combining the advantages of the classical elephant trunk with modern stent technology, the frozen elephant trunk (FET) procedure has been instrumental in treating complex multi-segmental aortic pathologies in a single operation. The secured expansile stent-graft is able to facilitate downstream aortic remodeling by inducing false lumen thrombosis and depressurization of the false lumen, stabilize

profiles of these devices, much less is known regarding long-term outcomes, particularly in terms of overall survival and freedom from reintervention (3-7). The present meta-analysis aimed to determine long-term outcomes following the FET procedure.

Methods

Literature search strategy

Included studies with 12 months follow up

Pooled in-hospital/30-day mortality	10.2%
Permanent neurological deficit	7.7 %
Spinal cord injury	6.5%

David Tian et al : Ann Cardiothoracic Surgery

Review > Eur J Cardiothorac Surg. 2015 May;47(5):759-69. doi: 10.1093/ejcts/ezv085.

Epub 2015 Mar 13.

Current status and recommendations for use of the frozen elephant trunk technique: a position paper by the Vascular Domain of EACTS

Malakh Shrestha¹, Jean Bachet², Joseph Bavaria³, Thierry P Carrel⁴, Ruggero De Paulis⁵, Roberto Di Bartolomeo⁶, Christian D Etz⁷, Martin Grabenwöger⁸, Michael Grimm⁹, Axel Haverich¹, Heinz Jakob¹⁰, Andreas Martens¹, Carlos A Mestres¹¹, Davide Pacini⁶, Tim Resch¹², Marc Schepens¹³, Paul P Urbanski¹⁴, Martin Czerny¹⁵

Affiliations + expand

PMID: 25769463 DOI: 10.1093/ejcts/ezv085

[Free article](#)

Abstract

The implementation of new surgical techniques offers chances but carries risks. Usually, several years pass before a critical appraisal and a balanced opinion of a new treatment method are available and rely on the evidence from the literature and expert's opinion. The frozen elephant trunk (FET) technique has been increasingly used to treat complex pathologies of the aortic arch and the descending aorta, but there still is an ongoing discussion within the surgical community about the optimal indications. This paper represents a common effort of the Vascular Domain of EACTS together with several surgeons with particular expertise in aortic surgery, and summarizes the current knowledge and the state of the art about the FET technique. The majority of the information about the FET technique has been extracted from 97 focused publications already available in the PubMed database (cohort studies, case reports, reviews, small series, meta-analyses and best evidence topics) published in English.

Spinal cord injury at 0–21%
And emphasis on the significantly higher incidence of spinal cord injury in patients undergoing FET compared with CET

Shrestha et al : EJCTS 2015

One-year outcomes of total arch replacement and frozen elephant trunk using the E-vita Open NEO

Chong Hoon Kim¹, Tae-Hoon Kim¹, Ha Lee^{2 3}, Myeong Su Kim^{2 3}, Woon Heo⁴,
Kyung-Jong Yoo⁵, Bum-Koo Cho⁶, Suk-Won Song^{2 3}

Affiliations + expand

PMID: 38238991 DOI: 10.1093/ejcts/ezae017

Abstract

Objectives: In this cohort study, we aimed to assess the 1-year clinical outcomes of using the E-vita Open NEO™ hybrid prosthesis for total arch replacement with frozen elephant trunk (FET) to repair extensive aortic pathologies.

Methods: We reviewed individuals who underwent thoracic aortic surgery between April 2021 and March 2023 from the Gangnam Severance Aortic Registry. Exclusion criteria included ascending aortic replacement, 1 or 2 partial arch replacement, descending aortic replacement and total arch replacement without an FET. Finally, all consecutive patients who underwent total arch replacement and FET with E-vita Open NEO for aortic arch pathologies between April 2021 and March 2023 were included in this cohort study. The patients were divided into 3 groups based on their pathology: acute aortic dissection, chronic aortic dissection and thoracic aortic aneurysm. The primary end point was in-hospital mortality. The secondary end points during the postoperative period comprised stroke, spinal cord injury and redo sternotomy for bleeding. Additionally, the secondary end points during the follow-up period included the 1-year survival rate, 1-year freedom from all aortic procedures and 1-year freedom from unplanned aortic interventions.

Results: The study included 167 patients in total: 92 patients (55.1%) with acute aortic dissection, 20 patients (12.0%) with chronic aortic dissection and 55 patients (32.9%) with thoracic aortic aneurysm. The in-hospital mortality was 1.8% (n = 3). Strokes occurred in 1.8% (n = 3) of the patients, spinal cord injury in 1.8% (n = 3) and redo sternotomy for bleeding was performed in 3.0% (n = 5). There were no significant differences between the pathological groups. The median follow-up period (quartile 1-quartile 3) was 198 (37-373) days, with 1-year survival rates of 95.9%. At 1 year, the freedom from all

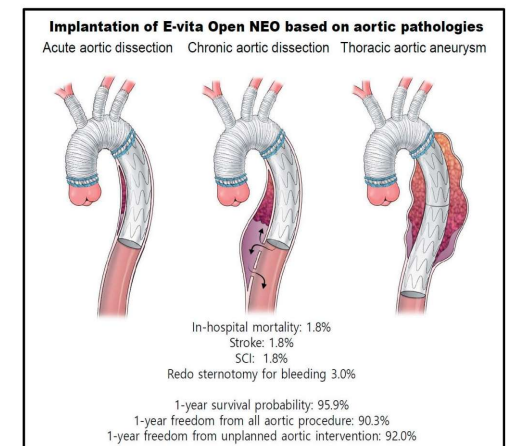
Total 167 patients

3 groups based on their pathology:

acute aortic dissection	92 pts (55.1%)
chronic aortic dissection	20 pts (12.0%)
thoracic aortic aneurysm	55 pts (32.9%)

Strokes 1.8% (3 pts)

SCI 1.8% (3 pts)



Chong Hoon Kim et al:
Eur J Cardiothorac Surg 2024

One-year outcomes of total arch replacement and frozen elephant trunk using the E-vita Open NEO

Chong Hoon Kim¹, Tae-Hoon Kim¹, Ha Lee^{2,3}, Myeong Su Kim^{2,3}, Woon Heo⁴,
Kyung-Iana Yoo⁵, Bum-Koo Cho⁶, Suk-Won Song^{2,3}

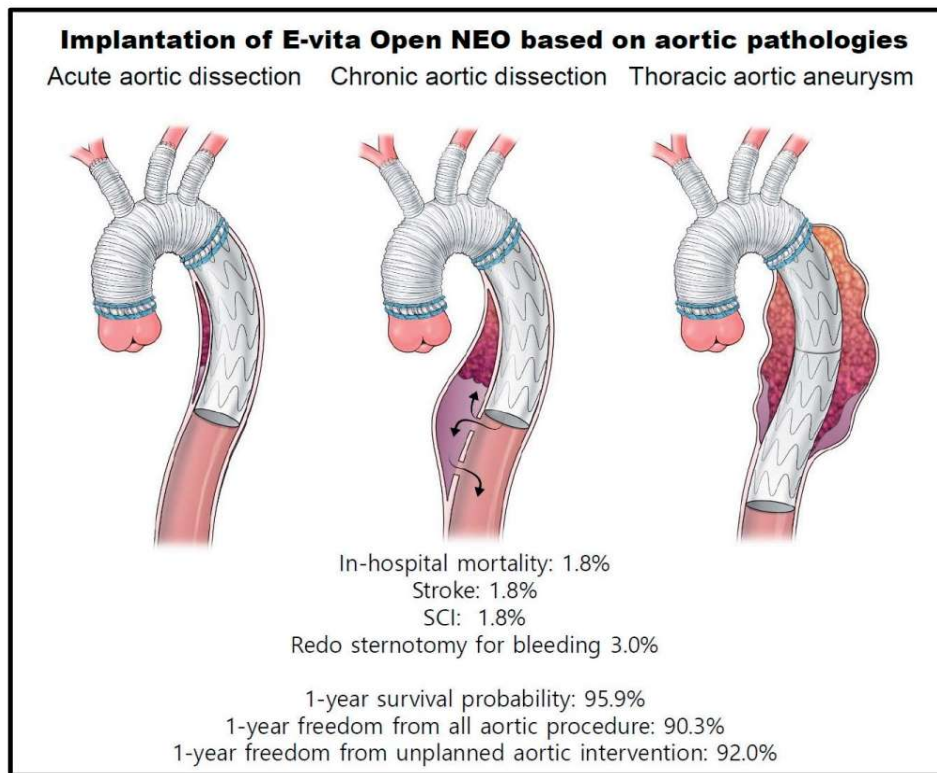
Affilia
PMID

Abs

Objec
Open
exten

Meth
Marcl
repla
repla
and F
includ
aortic
in-ho
spina
the fc
1-yea

Resul
patie
The ir
injury
signif



quartile 3) was 198 (37-373) days, with 1-year survival rates of 95.9%. At 1 year, the freedom from all

Chong Hoon Kim et al:
Eur J Cardiothorac Surg 2024

**Length of the stent graft 120-180 mm
(with slight variations)**

Rect Temp	27.8-30.8
Stent Length	120 (120-130)
Zone of the distal anastomosis	Zone 2 (138) Zone 3 (18) Zone 1 (11)

Stent proximal to T8

**In cases where distal landing
zone was below T 10 ,
a second stage was considered**

CSF was used in 1 pt with aneurysm

One-year outcomes of total arch replacement and frozen elephant trunk using the E-vita Open NEO

Chong Hoon Kim¹, Tae-Hoon Kim¹, Ha Lee^{2,3}, Myeong Su Kim^{2,3}, Woon Heo⁴,
Kyung-Iana Yoo⁵, Bum-Koo Cho⁶, Suk-Won Song^{2,3}

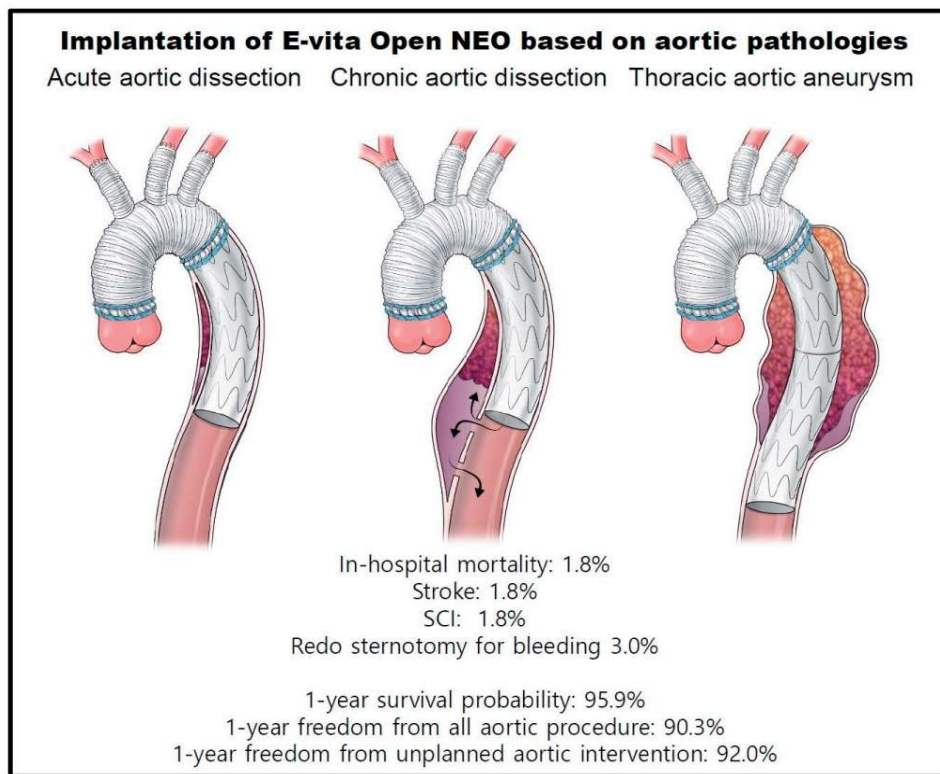
Affilia
PMID

Abs

Obj
Open
exten

Meth
Marcl
repla
repla
and F
includ
aortic
in-ho
spina
the fc
1-yea

Resul
patie
The ir
injury
signif



quartile 3) was 198 (37-373) days, with 1-year survival rates of 95.9%. At 1 year, the freedom from all

Chong Hoon Kim et al:
Eur J Cardiothorac Surg 2024

Risk factors for SCI

- Intraoperative transfusion of PRBC's
1.58 (1.02-2.44) p= 0.04
- Shaggy aorta (embolization)
(prevent : adequate de-airing and distal perfusion)
- Origination of the segmental arteries from the FL rapid FL thrombosis and obstruction of the segm. arteries

CSF was used in 1 pt with aneurysm

ORIGINAL ARTICLE | ADULT CARDIAC | VOLUME 111, ISSUE 6, P1876-1882, JUNE 2021 [Download Full Issue](#)

First-in-Human Use of the Cook Hybrid Frozen Elephant Trunk Graft: The Canadian Experience

Vincent Chauvette, MD • Philippe Demers, MD, MSc • Kevin Lachapelle, MD • Michael W.A. Chu, MD, MSc • François Dagenais, MD [✉](#)

Published: October 11, 2020 • DOI: <https://doi.org/10.1016/j.athoracsur.2020.08.011> • [Check for updates](#)

Patients and
Methods

Results

Comment

Supplementary
Data

References

Background

Advancements in technology have changed the treatment of aortic arch pathologies. Specifically, the introduction of the frozen elephant trunk technique has allowed one-stage treatment of pathologies that would have otherwise required a two-stage procedure. We present the early outcomes of a novel frozen elephant hybrid stent graft.

Methods

Between August 2015 and July 2019, 39 patients (56% male; mean age 67 ± 11 years) underwent an arch reconstruction with a novel hybrid stent graft in four different Canadian centers. The most common indication for surgery was arch aneurysm (31%) followed by acute dissection (28%). All patients were prospectively followed with clinical and imaging assessments.

August 2015- July 2019 (4 centers)
39 patients (56% male) mean age 67 ± 11 years
Arch aneurysm 31%
Acute dissection 28%

ORIGINAL ARTICLE | ADULT CARDIAC | VOLUME 111, ISSUE 6, P1876-1882, JUNE 2021 [Download Full Issue](#)

First-in-Human Use of the Cook Hybrid Frozen Elephant Trunk Graft: The Canadian Experience

Vincent Chauvette, MD • Philippe Demers, MD, MSc • Kevin Lachapelle, MD • Michael W.A. Chu, MD, MSc •

Francçois

Publ

Patients and Methods

Results

Comment

Supplementary

Data

References


Whenever devices used for Type A Median Range

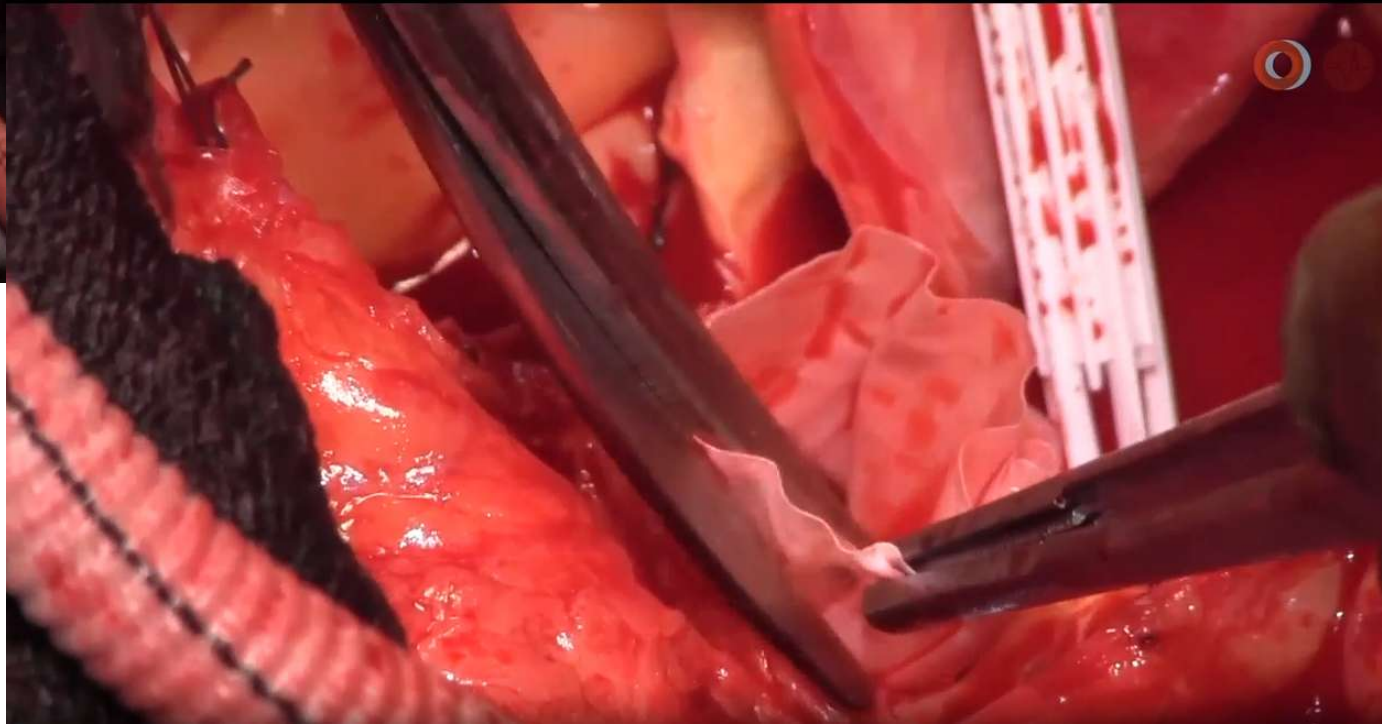
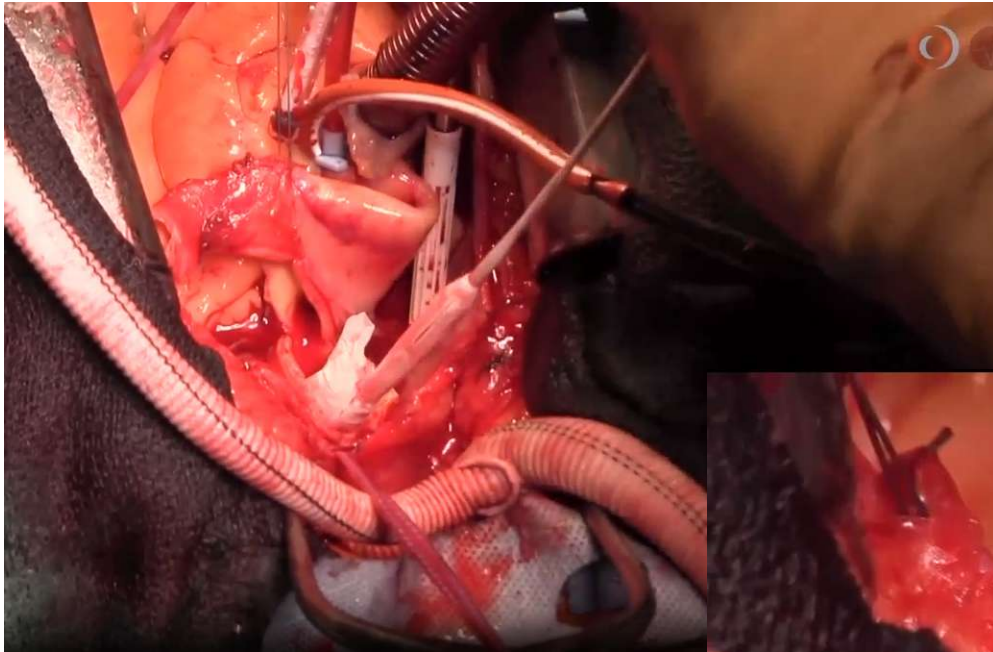
Length 10 cm
150 cm (130-150)
100 cm-180 cm

Methods

Between August 2015 and July 2019, 39 patients (56% male; with a novel hybrid stent graft in four different Canadian centers: aneurysm (31%) followed by acute dissection (28%). All patients underwent postoperative assessments.

The hybrid graft is crimped inside a clear sheath
The end of the unstented polyester graft is visualized during deployment






Perioperative deaths	3 pts	8%
SCI recovery)	5 pts	15% (all complete
Stroke	6 pts	15%

- Patients and Methods
- Results
- Comment
- Supplementary Data
- References





4 of these pts 15 cm

Between August 2018 and July 2019, 66 patients (66% male, mean age 68 years) were treated with a novel hybrid stent graft in four different Canadian centers. The most common complication was aneurysm (31%) followed by acute dissection (28%). All patients were followed up with regular assessments.



ORIGINAL ARTICLE | ADULT CARDIAC | VOLUME 111, ISSUE 6, P1876-1882, JUNE 2021 [Download Full Issue](#)

First-in-Human Use of the Cook Hybrid Frozen Elephant Trunk Graft: The Canadian Experience

Vincent Chauvette, MD • Philippe Demers, MD, MSc • Kevin Lachapelle, MD • Michael W.A. Chu, MD, MSc • François Dagenais, MD  

Published: October 11, 2020 • DOI: <https://doi.org/10.1016/j.athoracsur.2020.08.011> • [Check for updates](#)


- Patients and Methods
- Results
- Comment
- Supplementary Data
- References

Perioperative deaths	3 pts	8%
SCI recovery)	5 pts	15% (all complete
Stroke	6 pts	15%

Strategies :

- minimizing length graft
- optimizing SCPP (maintaining high perfusion pressure during CPB , HTN postop
- minimizing distal CA time (20 min in the series)
- Preop carotid subc bypass

Between August 2018 and July 2019, 66 patients (66% male, mean age 68 years) were treated with a novel hybrid stent graft in four different Canadian centers. The most common indication was aneurysm (31%) followed by acute dissection (28%). All patients were followed up with regular assessments.



THE ANNALS OF THORACIC SURGERY

Articles Publish Topics Multimedia CME About Contact

ORIGINAL ARTICLE | ADULT CARDIAC | VOLUME 111, ISSUE 6, P1876-1882, JUNE 2021 [Download Full Issue](#)

First-in-Human Use of the Cook Hybrid Frozen Elephant Trunk Graft: The Canadian Experience

Vincent Chauvette, MD • Philippe Demers, MD, MSc • Kevin Lachapelle, MD • Michael W.A. Chu, MD, MSc • François Dagenais, MD

Published: October 11, 2020 • DOI: <https://doi.org/10.1016/j.athoracsur.2020.08.011> [Check for updates](#)


Perioperative deaths	3 pts	8%
SCI recovery)	5 pts	15% (all complete
Stroke	6 pts	15%

- Patients and Methods
- Results
- Comment
- Supplementary Data
- References

Strategies :

?? Ideal hypothermia
?? CSF

Between August 2018 and July 2019, 66 patients (66% male, mean age 68 years) were treated with a novel hybrid stent graft in four different Canadian centers. The most common indication was aneurysm (31%) followed by acute dissection (28%). All patients were followed up with regular assessments.



Recommendations for TAAA Spinal Cord Protection		
Referenced studies that support the recommendations are summarized in the Online Data Supplement .		
COR	LOE	Recommendations
1	A	1. In patients undergoing open TAAA repair who are at high risk for SCI, cerebrospinal fluid drainage is recommended to reduce the incidence of temporary SCI, permanent SCI, or both. ¹⁻⁷

Isselbacher, Preventza, Black et al :
2022 ACC/AHA guidelines/ Circulation

*CSF class I for open repair of TAAA
Not for FET*

Circulation

AHA Journals Journal Information All Issues Subjects Features Resources & Educ

Home > Circulation > Vol. 146, No. 24 > 2022 ACC/AHA Guideline for the Diagnosis and Management of Aortic Disease: A Report of the American Heart Association/...

FREE ACCESS
REVIEW ARTICLE

PDF/E/PUB

Tools Share

Jump to

Abstract
Contents

Top 10 Take-Home Messages for the Diagnosis and Management of Aortic Disease

Preamble

1. Introduction
2. Normal Anatomy, Abnormal Anatomy, and Definitions
3. Imaging and Measurements
4. Multidisciplinary Aortic Teams
5. Shared Decision-Making
6. Aneurysms
7. Acute Aortic Syndromes

Abstract

Aim:
The '2022 ACC/AHA Guideline for the Diagnosis and Management of Aortic Disease' provides recommendations to guide clinicians in the diagnosis, genetic evaluation and family screening, medical therapy, endovascular and surgical treatment, and long-term surveillance of patients with aortic disease across its multiple clinical presentation subsets (ie, asymptomatic, stable symptomatic, and acute aortic syndromes).

Methods:
A comprehensive literature search was conducted from January 2021 to April 2021, encompassing studies, reviews, and other evidence conducted on human subjects that were published in English from PubMed, EMBASE, the Cochrane Library, CINAHL, Complete, and other selected databases relevant to this guideline. Additional relevant studies, published through June 2022 during the guideline writing process, were also considered by the writing committee, where appropriate.

Structure:
Recommendations from previously published AHA/ACC guidelines on thoracic aortic disease, peripheral artery disease, and bicuspid aortic valve disease have been updated with new evidence to guide clinicians. In addition, new recommendations addressing comprehensive care for patients with aortic disease have been developed. There is added emphasis on the role of shared decision making, especially in the management of patients with aortic disease both before and during pregnancy. The is also an increased emphasis on the importance of institutional interventional volume and multidisciplinary aortic team expertise in the care of patients with aortic disease.

> J Neurotrauma. 2015 Dec 15;32(24):1958-67. doi: 10.1089/neu.2014.3778. Epub 2015 Aug 17.

Mean Arterial Blood Pressure Correlates with Neurological Recovery after Human Spinal Cord Injury: Analysis of High Frequency Physiologic Data

Gregory Hawryluk^{1 2 3}, William Whetstone⁴, Rajiv Saigal^{2 3}, Adam Ferguson^{2 3}, Jason Talbott⁵, Jacqueline Bresnahan^{2 3}, Sanjay Dhall^{2 3}, Jonathan Pan⁶, Michael Beattie^{2 3}, Geoffrey Manley^{2 3}

Affiliations + expand

PMID: 25669633 PMCID: PMC4677564 DOI: 10.1089/neu.2014.3778

[Free PMC article](#)

J Neurotrauma 2015

Abstract

Current guidelines for the care of patients with acute spinal cord injuries (SCIs) recommend maintaining mean arterial pressure (MAP) values of 85-90 mm Hg for 7 days after an acute SCI; however, little evidence supports this recommendation. We sought to better inform the relationship between MAP values and neurological recovery. A computer system automatically collected and stored q1 min physiological data from intensive care during the first 7 days after SCI. Data for 100 patients with acute SCI were collected. Injury Association Impairment Scale (AIS) grades determined at time of hospital discharge. Average MAP values and MAP thresholds were explored for values from 120 mm Hg. The relationship between these measures and outcome was explored from the time of injury. A total of 994,875 q1 min arterial pressures were recorded for the included patients amid 1,688,194 mm Hg. A large proportion of measures were below 85 mm Hg despite generally acceptable average MAP values. Higher average MAP values correlated with improved recovery in the first 2-3 days after SCI while the proportion of MAP values below the accepted threshold of 85 mm Hg seemed a stronger correlate, decreasing in strength over the first 5-7 days after injury. This study provides strong evidence supporting a correlation between MAP values and neurological recovery. It does not, however, provide evidence of a causal relationship. Duration of hypotension may be more important than average MAP. It provides support for the notion of MAP thresholds in SCI recovery, and the highest MAP values correlated with the greatest degree of neurological recovery. The results are concordant with current guidelines in suggesting that MAP thresholds >85 mm Hg may be

There is evidence supporting the concept that improving hemodynamics can enhance neurological outcomes

> J Spinal Cord Med. 2021 May;44(3):350-356. doi: 10.1080/10790268.2019.1660840. Epub 2019 Sep 16.

Current practices and goals for mean arterial pressure and spinal cord perfusion pressure in acute traumatic spinal cord injury: Defining the gaps in knowledge

J Spinal Cord Med 2021

Sarah T Menacho¹, Candace Floyd²

Affiliations + expand

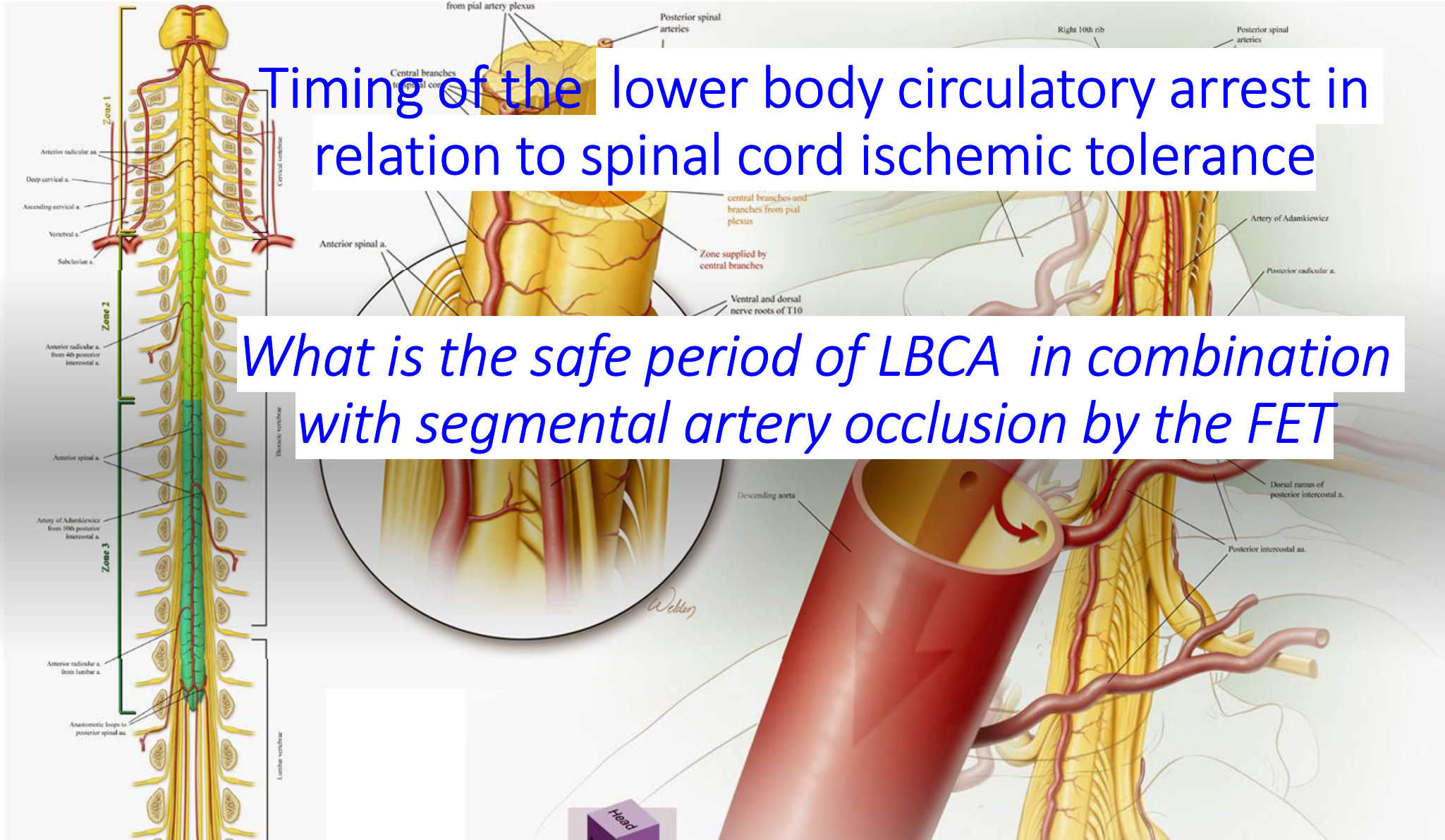
PMID: 31525138 PMCID: PMC8081322 DOI: 10.1080/10790268.2019.1660840

[Free PMC article](#)

Abstract

Spinal cord injury (SCI) is to artificially elevate mean arterial pressure (MAP) to the injured spinal cord. Current evidence is only Class III evidence. The optimal vasopressor to use is not clear and this leads to variability in practice. This review aims to improve neurological outcomes and identify gaps in knowledge surrounding the care of patients with traumatic SCI. **Methods:** we undertook a systematic review of the current literature identified from PubMed on MAP elevation and spinal cord perfusion pressure in acute SCI. **Results:** The 8 articles (6 human; 2 porcine) that met our inclusion criteria were all published within the last 6 years. Four were prospective, 1 was retrospective, and 3 were review articles. Only one study was randomized. All of these studies involved small sample sizes and varying lengths of MAP elevation. Choice of vasopressor was variable as well. **Conclusions:** From our literature review, we posit that norepinephrine may be the vasopressor of choice, that spinal cord perfusion pressure monitors can be safely placed at the injury site, and that the combination of MAP elevation and cerebrospinal fluid drainage may improve neurologic outcome more than either intervention alone.

Keywords: Mean arterial pressure; Spinal cord injury; Spinal cord perfusion pressure; Vasopressor.



Timing of the lower body circulatory arrest in relation to spinal cord ischemic tolerance

What is the safe period of LBCA in combination with segmental artery occlusion by the FET



[Interact Cardiovasc Thorac Surg](#). 2022 Jan; 34(1): 145–152.

PMCID: PMC8923407

Published online 2021 Aug 3. doi: [10.1093/icvts/ivab219](https://doi.org/10.1093/icvts/ivab219)

PMID: [34999799](https://pubmed.ncbi.nlm.nih.gov/34999799/)

Spinal cord injury during selective cerebral perfusion and segmental artery occlusion: an experimental study

[Hannu-Pekka Honkanen](#)^{✉1}, [Caius Mustonen](#)¹, [Hannu Tuominen](#)², [Kai Kiviluoma](#)¹, [Vesa Anttila](#)³ and [Tatu Juvonen](#)^{1,4}

▼ [Author information](#) ▶ [Article notes](#) ▶ [Copyright and License information](#) [PMC Disclaimer](#)

¹ Department of Surgery, Research Unit of Surgery, Anaesthesia and Intensive Care, University of Oulu, Medical Research Center, Oulu, Finland

² Department of Pathology, Oulu University Hospital, Oulu, Finland

³ Department of Surgery, Heart Center, University of Turku and Turku University Hospital, Turku, Finland

⁴ Department of Cardiac Surgery, Heart and Lung Center, Helsinki University Central Hospital, Helsinki, Finland

✉Corresponding author.

†Hannu-Pekka Honkanen and Caius Mustonen contributed equally to this work.

Corresponding author. Research Unit of Surgery, Anaesthesia and Intensive Care, University of Oulu, Medical Research Center Oulu, PO Box 21, 90029 OYS, Oulu, Finland. Tel: +358-40-7052844; e-mail:

hannu-pekka.honkanen@student.oulu.fi (H.-P. Honkanen).



[Interact Cardiovasc Thorac Surg](#). 2022 Jan; 34(1): 145–152.

PMCID: PMC8923407

Published online 2021 Aug 3. doi: [10.1093/icvts/ivab219](https://doi.org/10.1093/icvts/ivab219)

PMID: [34999799](https://pubmed.ncbi.nlm.nih.gov/34999799/)

Spinal cord injury during selective cerebral perfusion and segmental artery occlusion: an experimental study

[Hannu-Pekka Honkanen](#),¹ [Caius Mustonen](#),¹ [Hannu Tuominen](#),² [Kai Kiviluoma](#),¹ [Vesa Anttila](#),³ and [Tatu Juvonen](#)^{1,4}

[Author information](#) ▶ [Article notes](#) ▶ [Copyright and License information](#) [PMC Disclaimer](#)

¹ Department of Surgery, Research Unit of Surgery, Anaesthesia and Intensive Care, University of Oulu, Medical

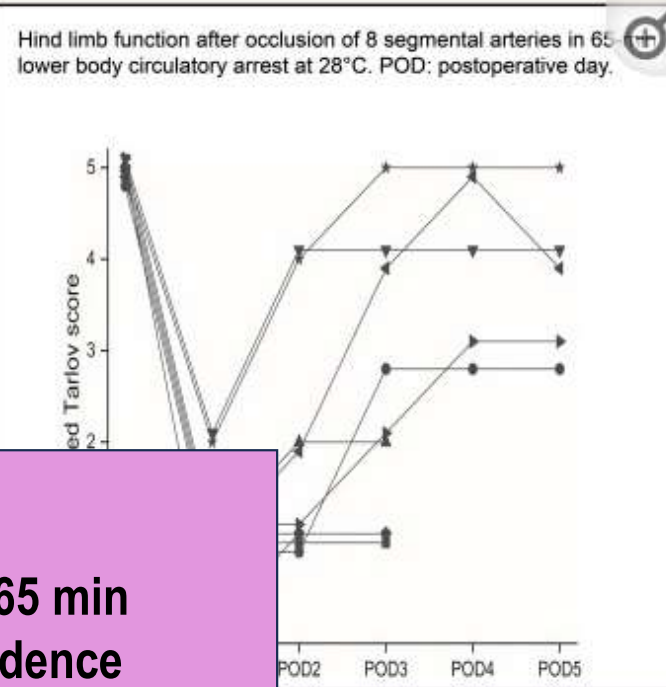
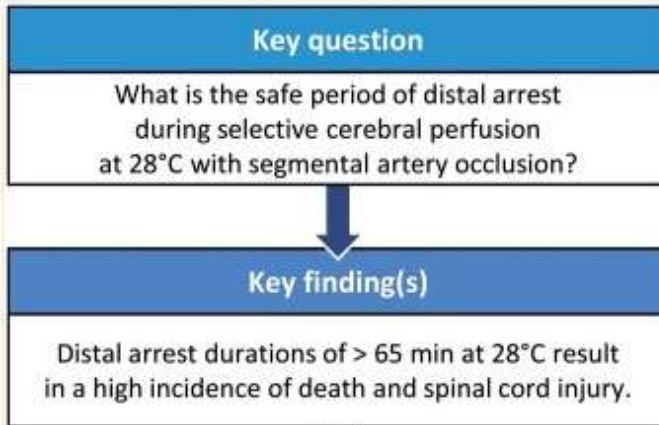
16 pigs

**65 min or 90 min of SCP at 28 ° C of LBCA
with occlusion of the 8 uppermost segmental
arteries (15-20 cm T8) (simulation procedure
of FET)**

Turku, Finland

hospital, Helsinki, Finland

University of Oulu, Medical Research



Distal arrest durations of >65 min at 28° C results in high incidence of death and SCI

*The safety of SCP
False sense of security regarding
protection of distal organs ??*

› Eur J Cardiothorac Surg. 2009 Dec;36(6):946-55. doi: 10.1016/j.ejcts.2009.05.046. Epub 2009 Jul 28.

Selective cerebral perfusion at 28 degrees C--is the spinal cord safe?

Christian D Etz ¹, Maximilian Luehr, Fabian A Kari, Hung Mo Lin, George Kleinman, Stefano Zoli, Konstadinos A Plestis, Randall B Griep

Affiliations + expand

PMID: 19640727 DOI: 10.1016/j.ejcts.2009.05.046

Abstract

Objective: To shorten cooling/rewarming associated with hypothermic neuroprotection strategies during complex aortic arch surgery, selective cerebral perfusion (SCP) at 28 degrees C has recently been advocated, although its safe limits - especially with regard to the ischaemic tolerance of the spinal cord - have not been systematically examined.

Methods: Twenty juvenile Yorkshire pigs (30.3+/-2.8kg) were randomly allocated to undergo circulatory arrest and SCP at 28 degrees C for 90 min (group A; N=12) or 120 min (group B; N=8) at 50 mmHg using alpha-stat pH management. Spinal cord blood flow (SCBF) was assessed using fluorescent microspheres at baseline (prior to SCP); at 5 and 80 min during SCP, and at 1, 5 and 48 h after cardiopulmonary bypass (CPB). A modified Tarlov score was used to evaluate neurobehavioural recovery in all survivors blindly from videotapes for 5 days postoperatively. Histological ischaemic spinal cord injury was scored after sacrifice.

Results: All pigs could be weaned from CPB and ventilation, but seven pigs (58%) in group A and five (63%) in group B developed multi-organ failure and died within 24h. SCBF diminished immediately after initiation of SCP and was absent throughout SCP in all segments below T8/9, recovering to baseline 1h after SCP at all cord levels. All survivors suffered moderate-to-severe histological lumbar spinal cord damage, more severe in group B (p< or =0.049). Three of five group A pigs recovered normal function, but two suffered paraparesis. Group B survivors had a worse neurologic outcome (p<0.0001): all suffered paraplegia (one immediate, and two on day 2, after initial recovery).

Conclusion: SCP provides insufficient SCBF below T8/9 to sustain cord viability. At 28 degrees C, the ischaemic tolerance of the cord may be exceeded enough by 90 min to impair function; by 120 min, SCP at 28 degrees C invariably results in paraplegia.

At 28 degrees C, the ischaemic tolerance of the cord may be exceeded enough by 90 min to impair function; by 120 min, SCP at 28 degrees C invariably results in paraplegia

“Selective cerebral perfusion provides insufficient spinal cord blood flow below T8/9 to sustain spinal cord viability”

Etz C et al: Eur J Cardiothorac Surgery 2009

► Eur J Cardiothorac Surg. 2016 Nov;50(5):963-970. doi: 10.1093/ejcts/ezw146. Epub 2016 May 12.

Low-flow lower body perfusion for spinal protection in a frozen elephant trunk simulation model

Peter Lukas Haldenwang¹, Lorine Häuser², Nora Prochnow³, Damian Ziebur³, Andreas Baumann⁴, Magdalena Sikole², Marcus Schlömmicher², Inge Schmitz⁵, Hildegard Christ⁶, Justus Thomas Strauch²

Affiliations + expand

PMID: 27174550 DOI: 10.1093/ejcts/ezw146

Abstract

Objectives: The frozen elephant trunk (FET) procedure using isolated selective cerebral perfusion (SCP) at moderate hypothermia is associated with an increased risk for spinal cord ischaemia. The aim of this study was to evaluate the benefit of a combined selective cerebral and low-flow lower body perfusion (CLBP) in a porcine model.

Methods: Twenty pigs (46 ± 5 kg) were cooled on cardiopulmonary bypass (CPB) to 28°C. After aortic clamping and occlusion of the thoracic segmental arteries (TSA_{T4-T13}), a pressure-controlled SCP (50 mmHg) was established for 90 min. Randomly, in n = 10 animals, an additional lower body perfusion (LBP) was performed with 15 ml/kg/min (CLBP). Regional spinal cord blood flow (SCBF), cerebrospinal fluid pressure (CSFP) and motor-evoked potentials (MEPs) were registered at six time points. The animals were sacrificed after 120 min of weaning from CPB, and the spinal cord was analysed histologically using a schematic scoring system (0 = normal, 8 = total necrosis).

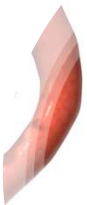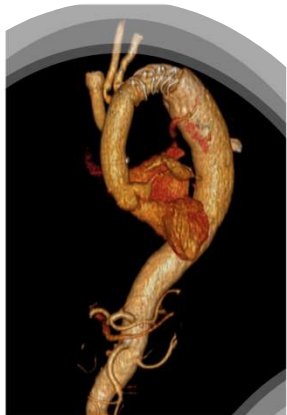
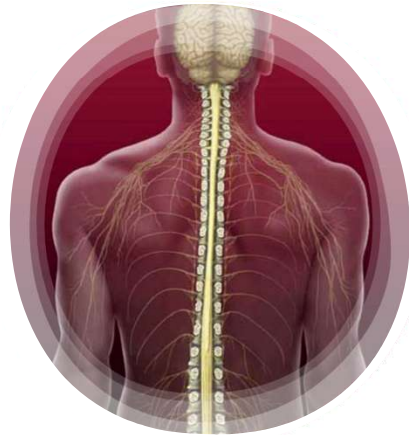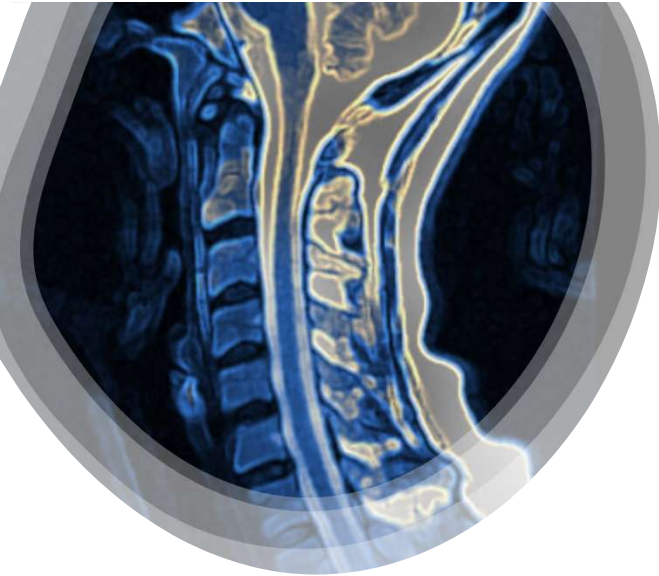
Results: Isolated SCP led to an SCBF decrease from 18.5 ± 9.4 to 0.9 ± 1.4 ml/min/100 g in the L1-L5 region (P = 0.005). CLBP preserved an almost physiological lumbar SCBF of 11.3 ± 5.3 ml/min/100 g. CSFP decreased in both groups during cooling and SCP/CLBP to 70-80% and increased during reperfusion to 150%, without showing significant differences between groups. The MEP amplitude decreased in both groups, with certain regional differences: T7-T11. MEP recording revealed a more pronounced amplitude decrease in the CLBP group (52.5 ± 2.0 vs 71.3 ± 0.9%), but MEP amplitudes recovered in both groups (SCP: 73.7 ± 0.5 vs CLBP: 82.6 ± 0.1%). During selective hypothermic perfusion, SCP-treated animals showed significant lower MEP amplitudes, when compared with CLBP-treated animals: 60 ± 9 vs 90 ± 3% (P < 0.001). After weaning, CLBP animals showed a better MEP

- The prolonged SCP provides an insufficient lumbar spinal cord protection during the FET procedure at 28°C
- *The use of a low-flow LBP in addition to SCP may reduce functional and structural spinal damage*

P L Haldenwang et al : Eur J Cardiothorac Surgery 2016

Frozen Elephant Trunk: How Long and Why

- Extensive stenting of the descending aorta during FET below T8 or stent length more than 10 cm could result in excessive occlusion and thromboembolism of the intercostal arterial supplying the spinal cord leading to paraplegia
- Neurologic injury during FET can be multifactorial
- Selective cerebral perfusion (with hypothermia) but will not sustain viability of spinal cord below T8 (optimal temperature ??) / add low flow LBP ?
- Optimizing hemodynamics is key



Thank you

preventzar@gmail.com

@OPreventzaMD



SESSION III: Aortic Symposium March 5-7 2026 Transverse Arch

The Houston Aortic Symposium 2026

March 5-7, 2026

The Westin Oaks, Houston, Texas