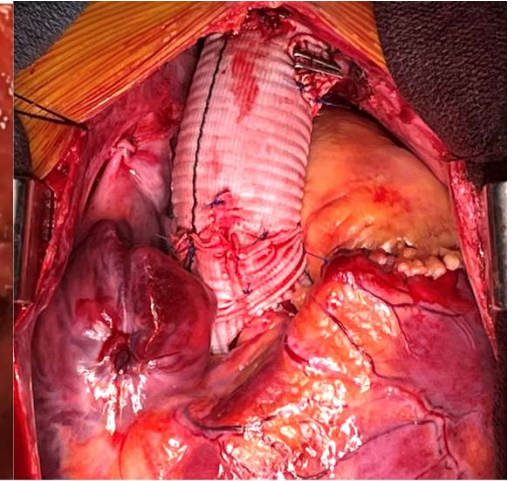
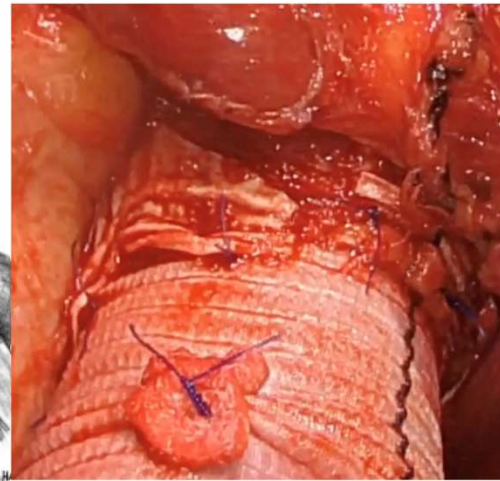
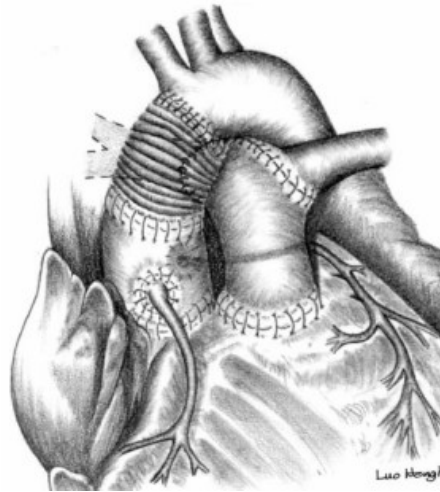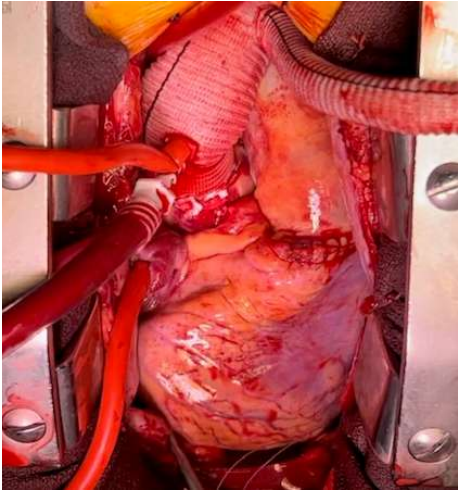Expanded Criteria Ross Procedure: *The good, the bad, and the ugly*

Houston Aortic Symposium
Houston, TX
March 5, 2026

Christopher R. Burke, MD
Associate Professor of Cardiac Surgery
Co-Director, Multidisciplinary Thoracic Aortic Program (MTAP)
University of Washington



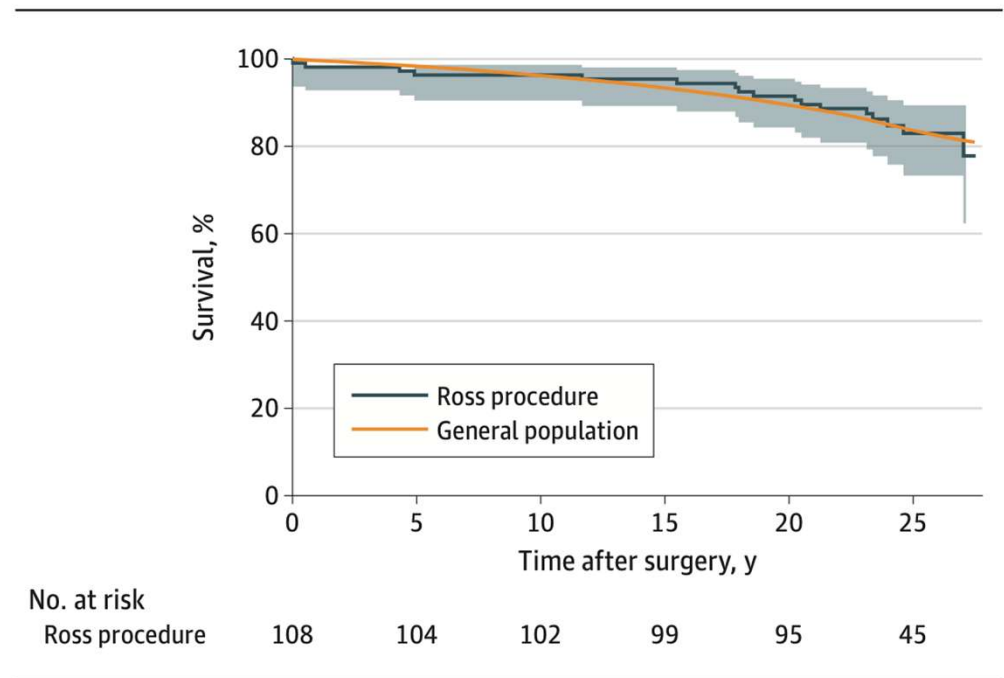
Disclosures

- ▶ None




- Ross procedure is an excellent operation in **appropriately selected** patients.
- The only AVR option that *may* provide equivalent survival to the general population.

Figure 1. Long-Term Survival After the Ross Procedure Compared With the Age-, Country of Origin-, and Sex-Matched General Population



Ideal Ross Candidate



Many (most?) patients evaluated for AVR will not be “ideal” candidates.

Critically important to evaluate who will actually derive benefit from a Ross.

Expanded Criteria Ross

Anatomic

- AR predominant
- Annular mismatch
- Root aneurysm
- PV fenestrations
- Bi/Quadricuspid PV
- Redo/hostile chest

Patient

- Older age
- Depressed EF
- Previous radiation (mantle)
- Severe inflammatory disease
- Genetic aortopathy
- Endocarditis

Expanded Criteria Ross

Anatomic

- AR predominant
- Annular mismatch
- Root aneurysm
- PV fenestrations
- Bi/Quadricuspid PV
- Redo/hostile chest

Patient

- Older age
- Depressed EF
- Previous radiation (mantle)
- Severe inflammatory disease
- Genetic aortopathy
- Endocarditis

Ross Procedure for Aortic Regurgitation versus Stenosis in Adults With and Without Autograft Support

Karen B. Abeln ^{a,*}, Lennart Froede^a, Tristan Ehrlich ^a, Idriss Souko^a and Hans-Joachim Schäfers ^{b,c}

^aDepartment of Cardiovascular Surgery, Saarland University Medical Center, Homburg, Germany

^bDepartment of Cardiac Surgery, University Hospital Quironsalud Madrid, Madrid, Spain

^cProf. Emeritus, Department of Cardiovascular Surgery, Saarland University, Homburg, Germany

All Comers

Autograft Support

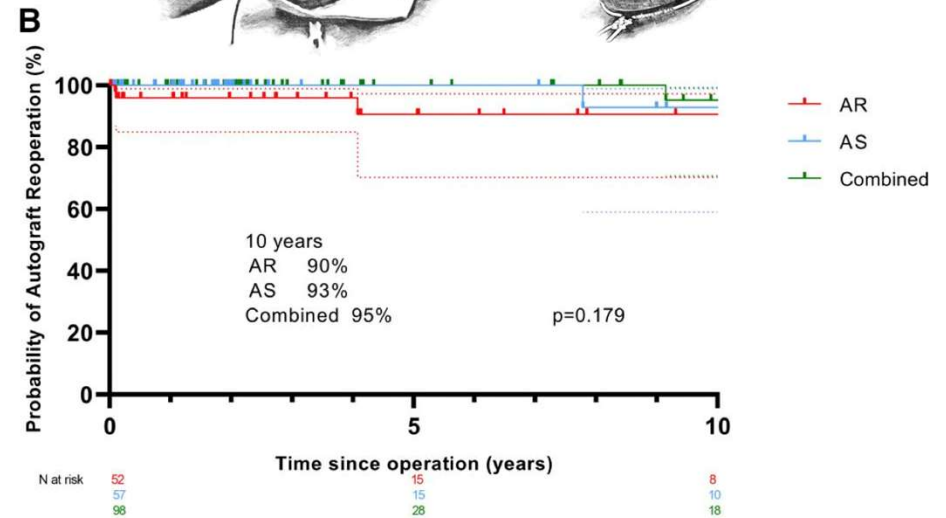
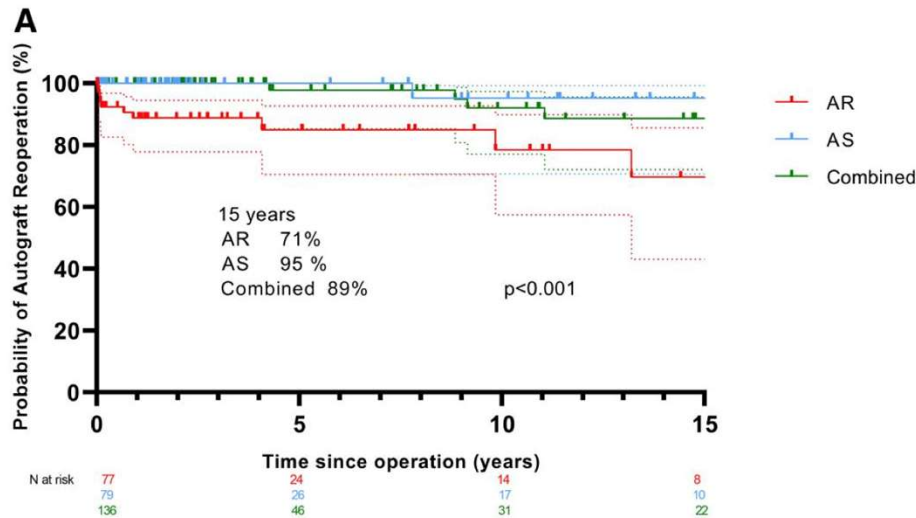
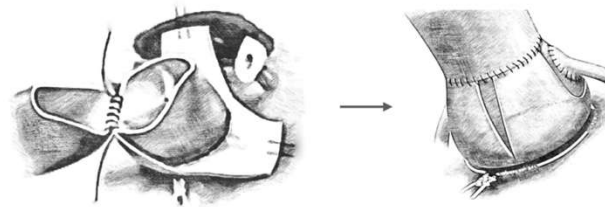
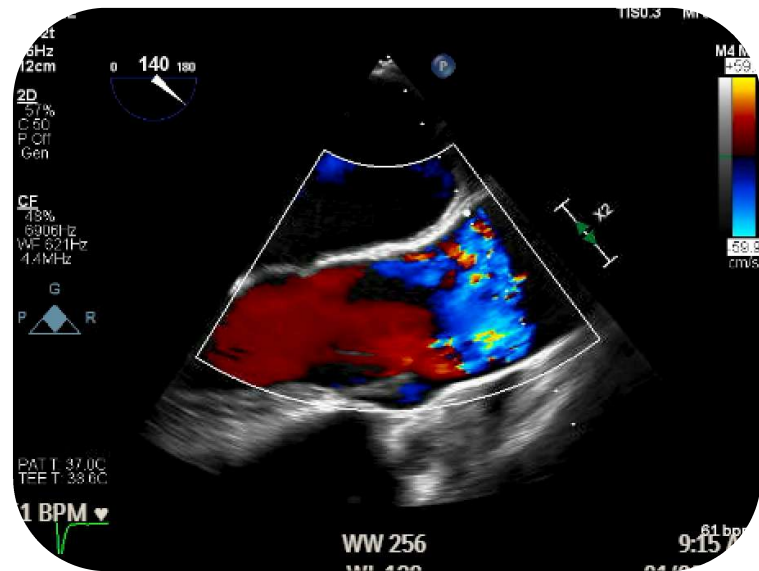
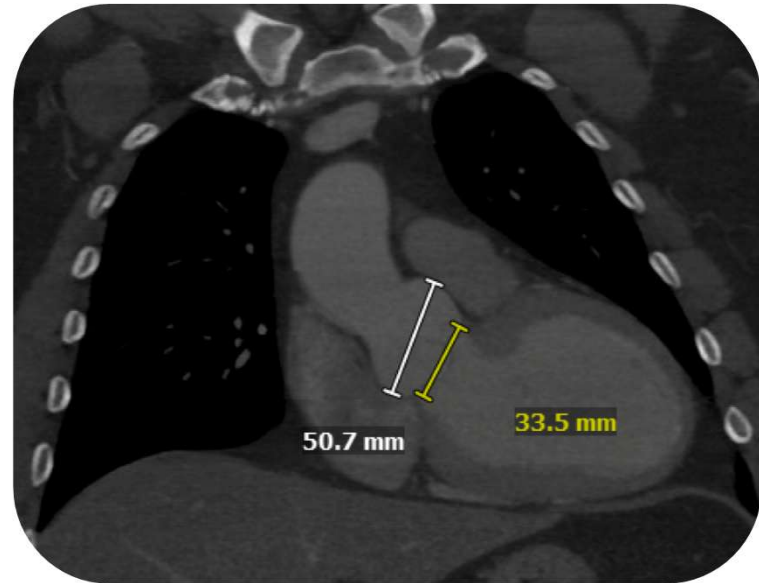


Figure 4: (A) Freedom from autograft reoperation according to haemodynamic lesion. (B) Freedom from autograft reoperation in patients with autograft support (according to haemodynamic lesion). AR: aortic regurgitation; AS: aortic stenosis; N: number.

AR Predominant

Case

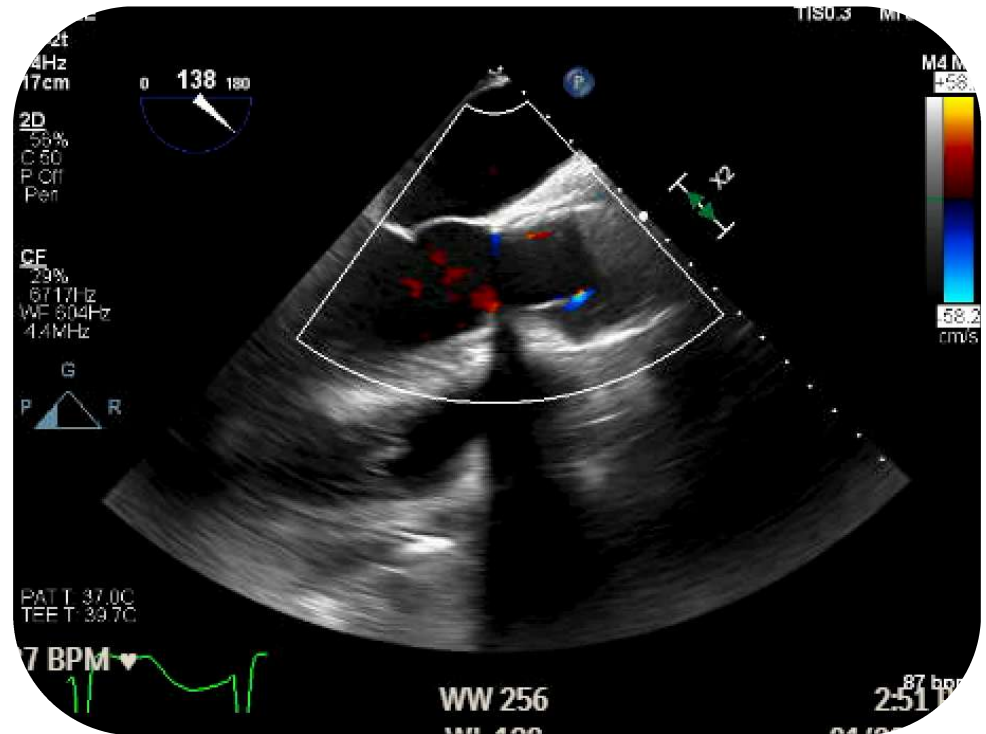
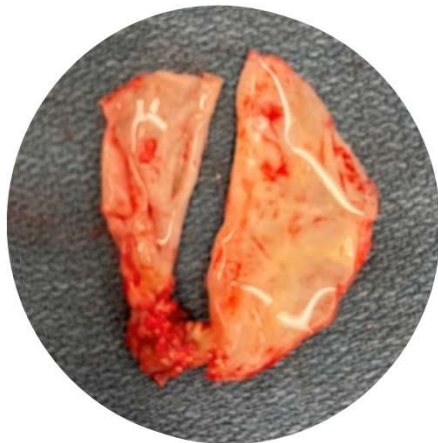
- 36 yo M, severe BAV AR
- Root 5.0 cm
- Annulus 33 mm



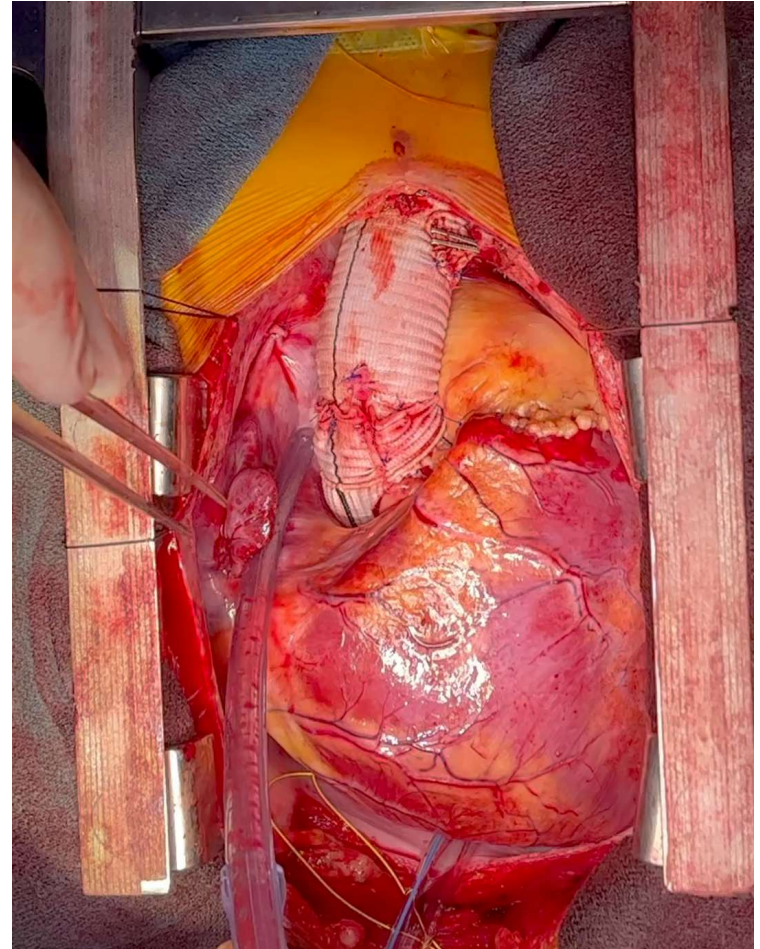
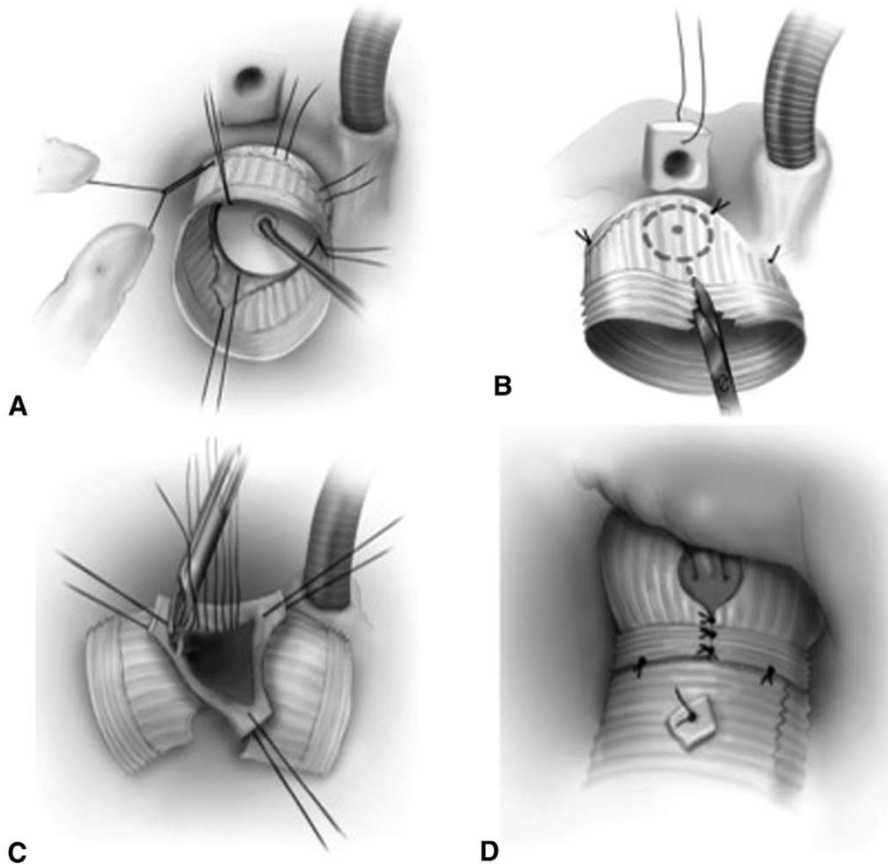
AR Predominant

OR

- Sievers 2 BAV with Ca
- Aortic annulus 33mm
- PV annulus 27 mm
- Seattle Shawl with annuloplasty to 27 mm



Seattle Shawl



Ross for AR/Annular Dilation/Root Dilation



- Can be done with excellent results
- ***Annular modification typically needed**
- Further autograft “protection” can help mitigate long-term autograft dilation
- Use caution with dilated LV/depressed EF

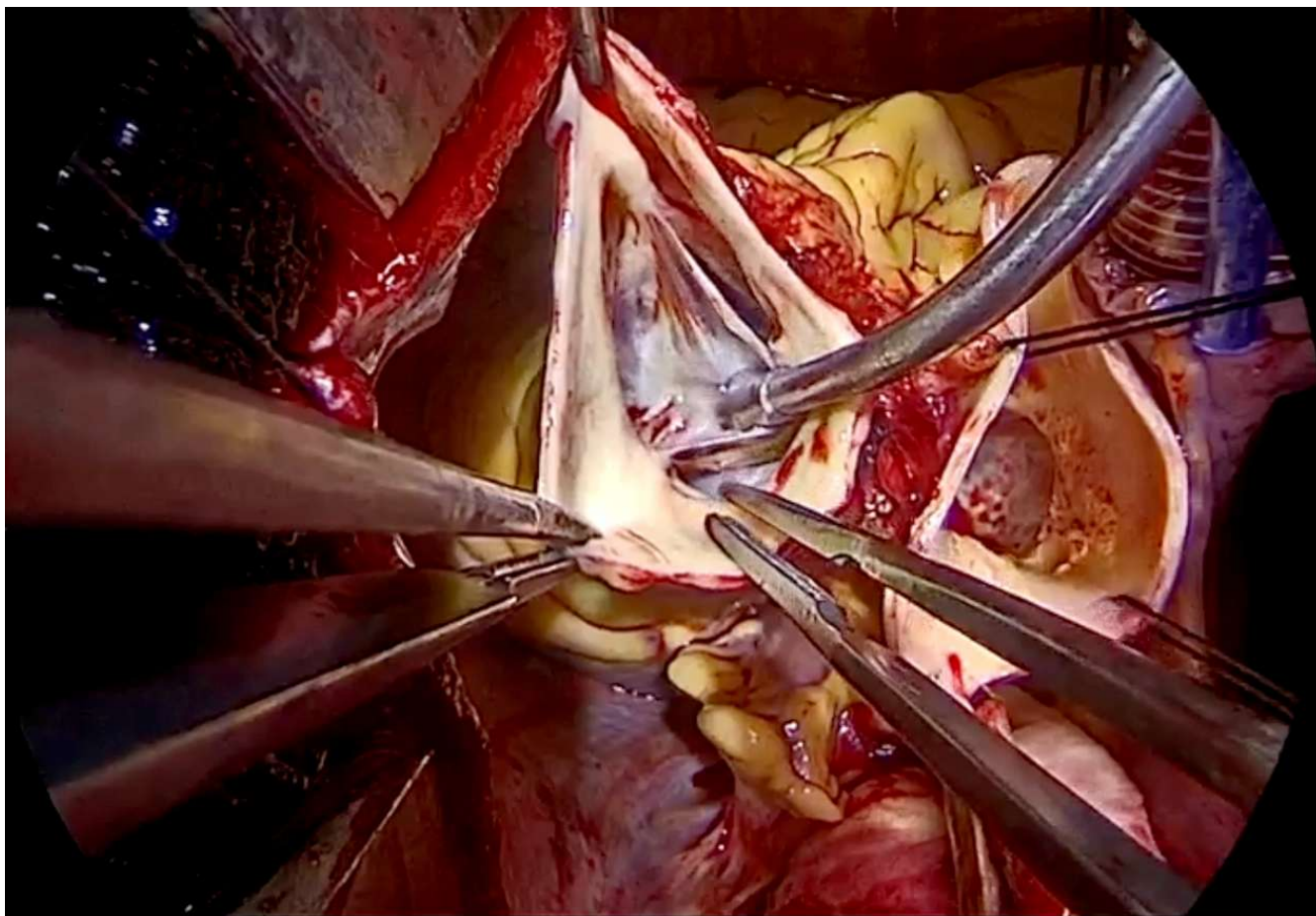
Expanded Criteria Ross

Anatomic

- AR predominant
- Annular mismatch
- Root aneurysm
- PV fenestrations
- Bi/Quadricuspid PV
- Redo/hostile chest

Patient

- Older age
- Depressed EF
- Previous radiation (mantle)
- Severe inflammatory disease
- Genetic aortopathy
- Endocarditis



Video courtesy of Dr. Jordan Bloom

Expanded Criteria Ross

Anatomic

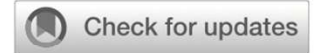- AR predominant
- Annular mismatch
- Root aneurysm
- PV fenestrations
- Bi/Quadricuspid PV
- Redo/hostile chest

Patient

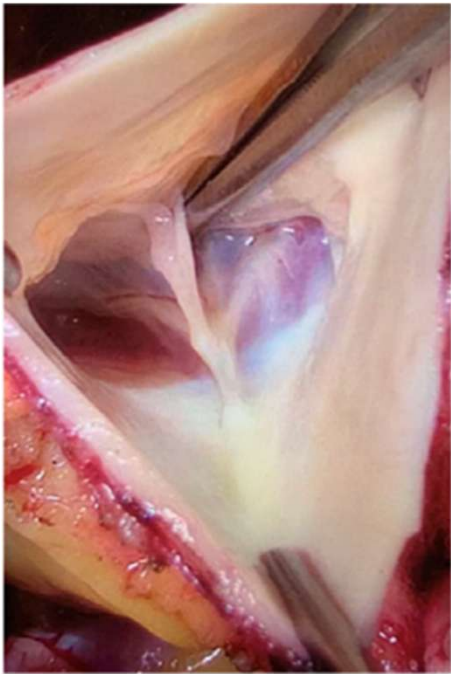- Older age
- Depressed EF
- Previous radiation (mantle)
- Severe inflammatory disease
- Genetic aortopathy
- Endocarditis

ADULT: AORTIC VALVE: SURGICAL TECHNIQUES

The Ross procedure using bicuspid and quadricuspid pulmonary valves



Pablo Filippa, MD,^a Vincent Chauvette, MD,^a Walid Ben Ali, MD, PhD,^a Raymond Cartier, MD,^a Nancy Poirier, MD,^a Ismail El-Hamamsy, MD, PhD,^b and Philippe Demers, MD, MSc,^a Montreal, Québec, Canada, and New York, NY



650 Ross

11 patients (1.7%) with PV abnormality (8 Bicuspid, 3 Quadricuspid)

Ross done in 7

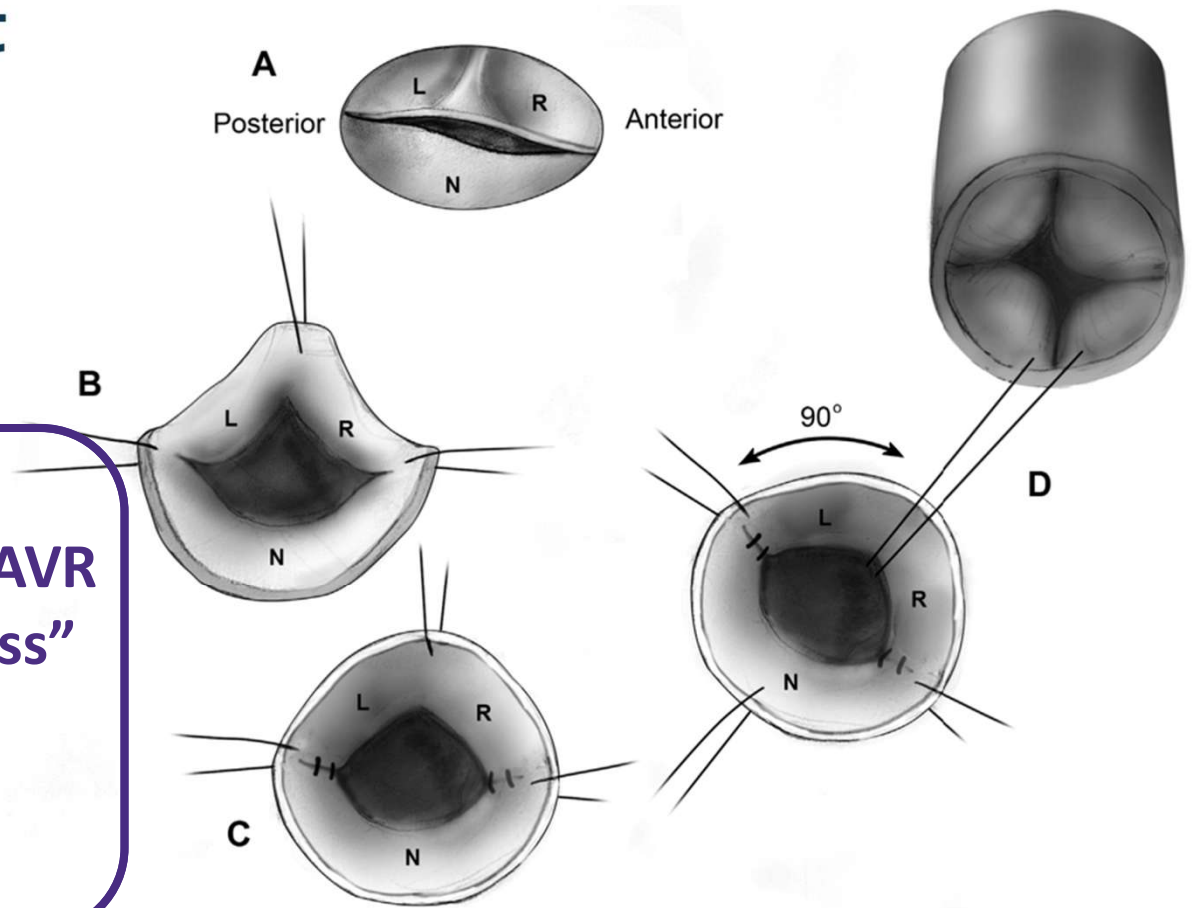
One early valve repair; all with trace-mild AI at 7 mo-8.2 yrs

Ross Procedure With a Symmetric Quadricuspid Pulmonary Autograft

Scott DeRoo, MD,¹ and
Christopher Burke, MD¹



Must weigh alternative AVR options and Ross “fitness” when using these autografts!!



Expanded Criteria Ross

Anatomic

- AR predominant
- Annular mismatch
- Root aneurysm
- PV fenestrations
- Bi/Quadricuspid PV
- Redo/hostile chest

Patient

- Older age
- Depressed EF
- Previous radiation (mantle)
- Severe inflammatory disease
- Genetic aortopathy
- Endocarditis

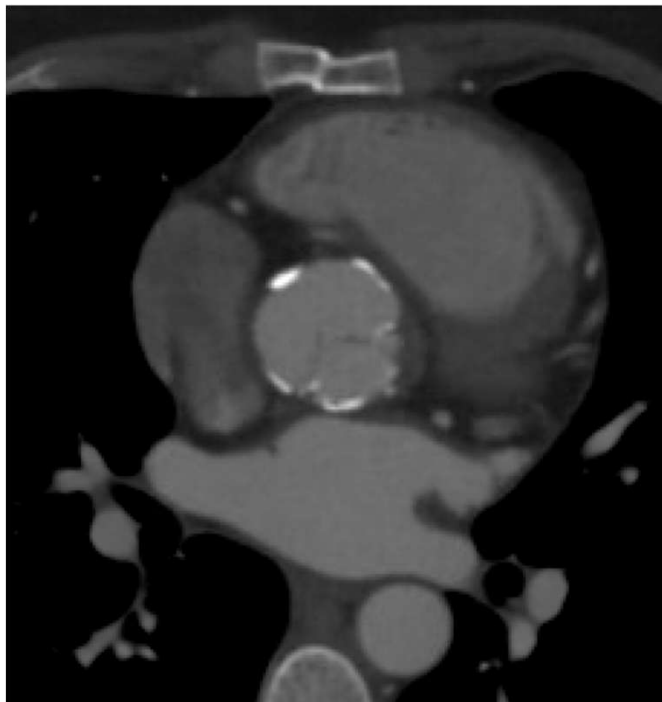Ross after previous AVR



**Ross after previous Bentall/root
replacement**



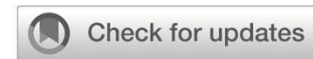Ross after previous Bentall/root replacement



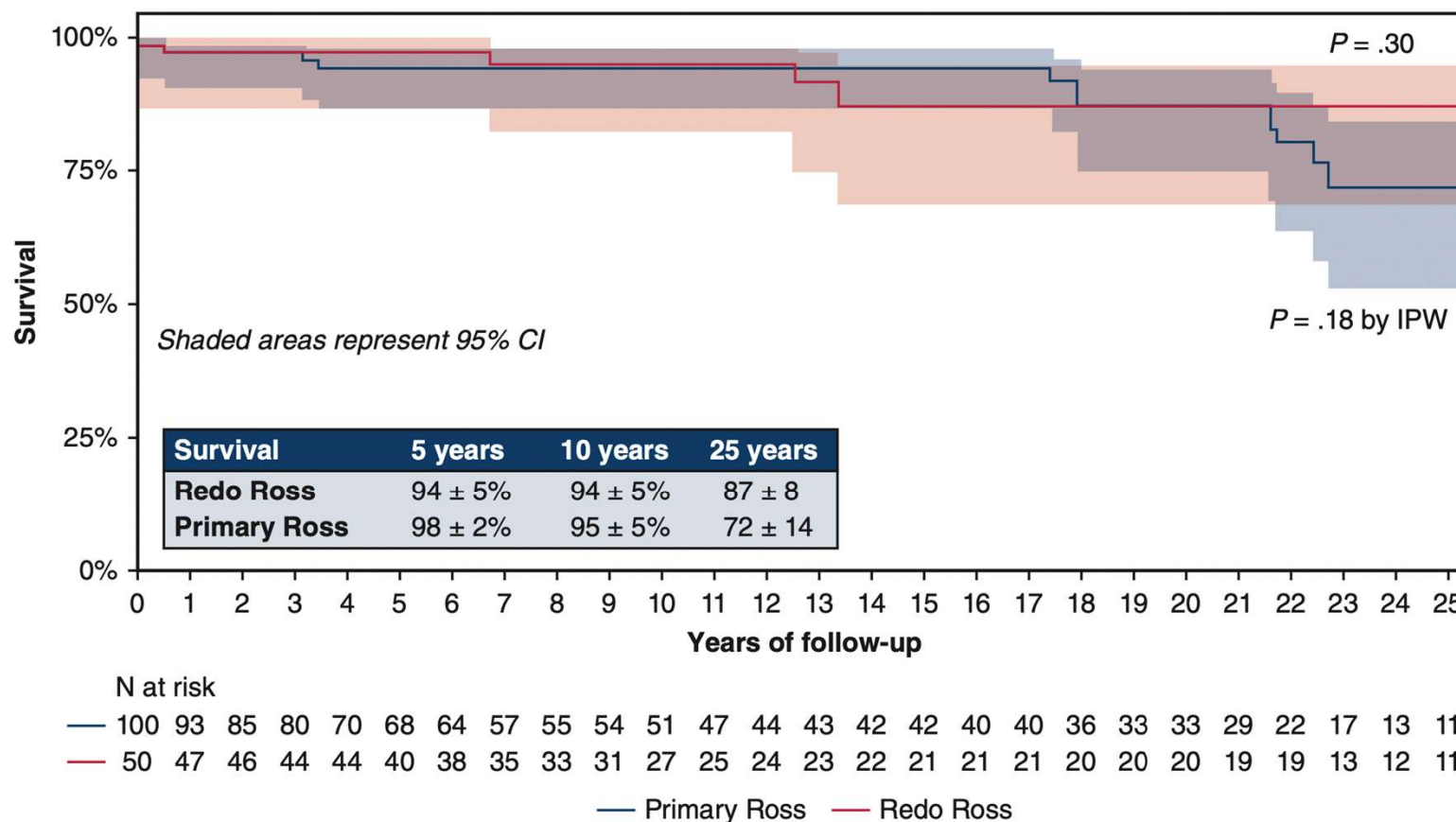
- 46 yo F, previous 25mm Freestyle 12 years prior
- Strongly desires a Ross

Caution when mobilizing coronary buttons as well as PA/autograft from previous root replacement!!!

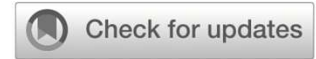Long-term results of patients undergoing the Ross procedure after a previous aortic valve surgery



Vincent Chauvette, MD, PhD,^a German J. Chaud, MD,^b Charles Laurin, MD,^b Mohamed Marzouk, MD,^b Dimitri Kalavrouziotis, MD,^b Siamak Mohammadi, MD,^b Philippe Pibarot, PhD, DVM,^c and Jean Perron, MD^b

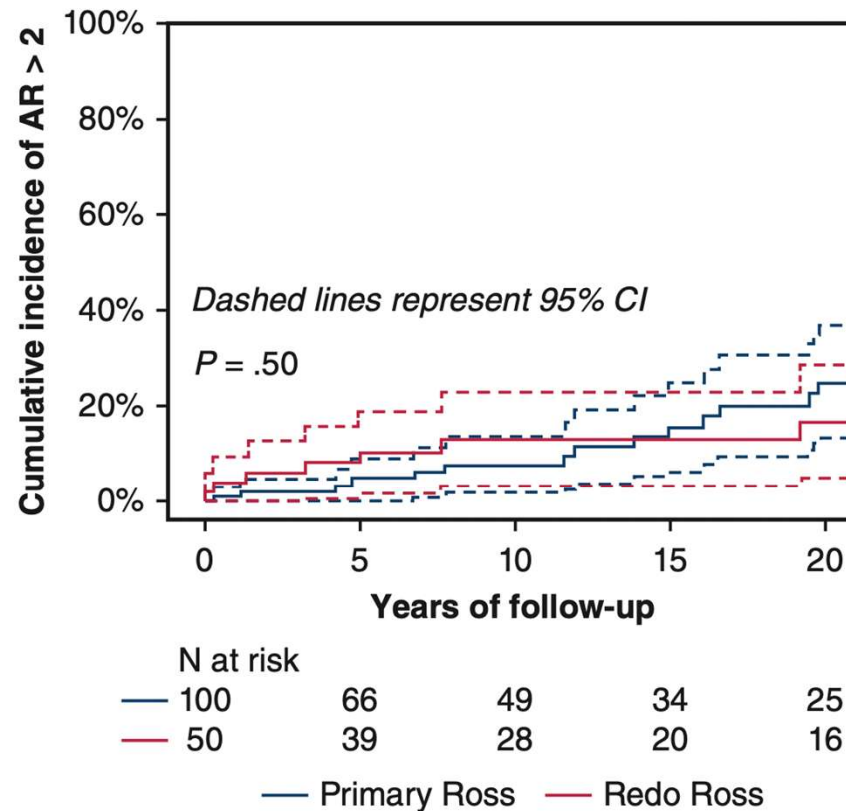


Long-term results of patients undergoing the Ross procedure after a previous aortic valve surgery



Vincent Chauvette, MD, PhD,^a German J. Chaud, MD,^b Charles Laurin, MD,^b Mohamed Marzouk, MD,^b Dimitri Kalavrouziotis, MD,^b Siamak Mohammadi, MD,^b Philippe Pibarot, PhD, DVM,^c and Jean Perron, MD^b

Only 10% (5/50) patients had previous Bentall



Expanded Criteria Ross

Anatomic

- AR predominant
- Annular mismatch
- Root aneurysm
- PV fenestrations
- Bi/Quadricuspid PV
- Redo/hostile chest

Patient

- Older age
- Depressed EF
- Previous radiation (mantle)
- Severe inflammatory disease
- Genetic aortopathy
- Endocarditis

Ross in “Older” Age

- 55-60 years is typically felt to be a rough “cut off”
- We need to acknowledge what benefit a Ross adds in patients over 60, especially with a large aortic annulus
- **Do survival benefits still exist in patient population that can achieve “lifetime” valve management with a bio AVR and ViV TAVR???**

Outcomes of the Ross procedure in patients older versus younger than 50 years old

Emily Shih ^{a,b,*}, William H. Ryan^a, John J. Squiers^a, Justin M. Schaffer^a, Katherine B. Harrington^a,
Jasjit K. Banwait^b, Talia G. Meidan^b, J. Michael DiMaio ^{a,b} and William T. Brinkman^a

^a Department of Cardiothoracic Surgery, Baylor Scott and White The Heart Hospital—Plano, Plano, TX, USA

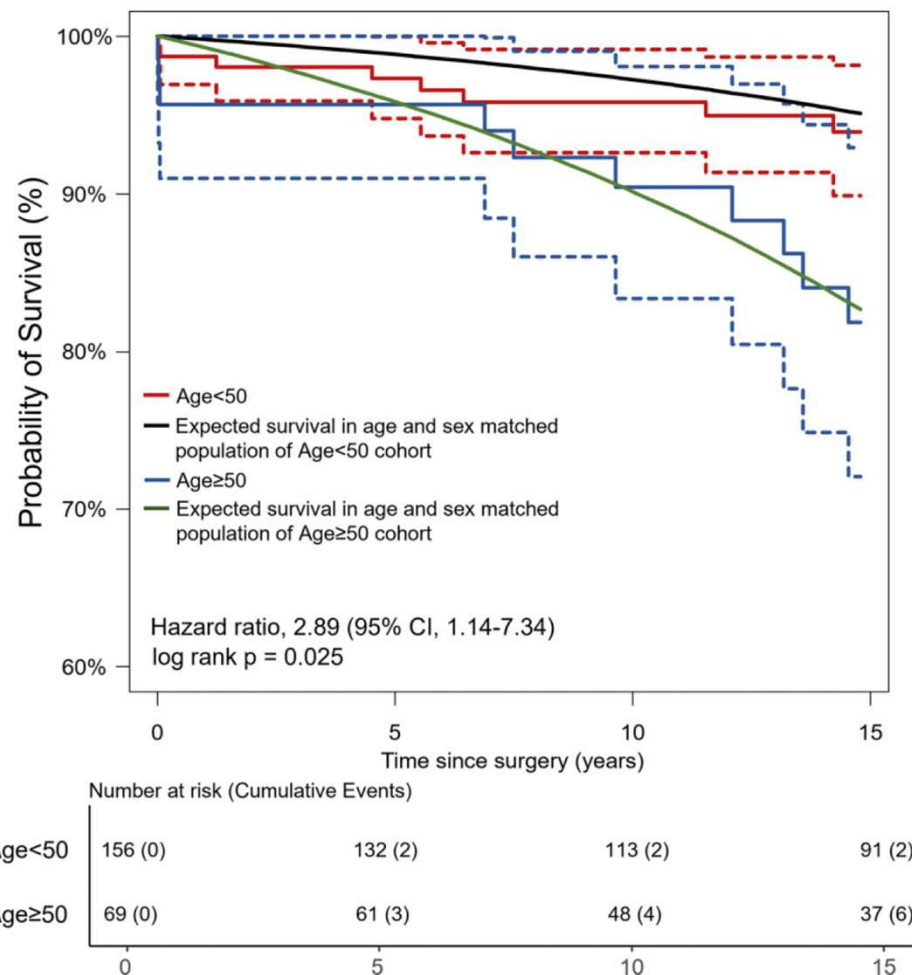
^b Baylor Scott and White Research Institute, Dallas, TX, USA

* Corresponding author. Baylor Scott and White The Heart Hospital—Plano, 1100 Allied Dr., Plano, TX 75093, USA. E-mail: emily.shih@bswhealth.org (E. Shih).

Received 11 December 2022; received in revised form 29 June 2023; accepted 12 July 2023

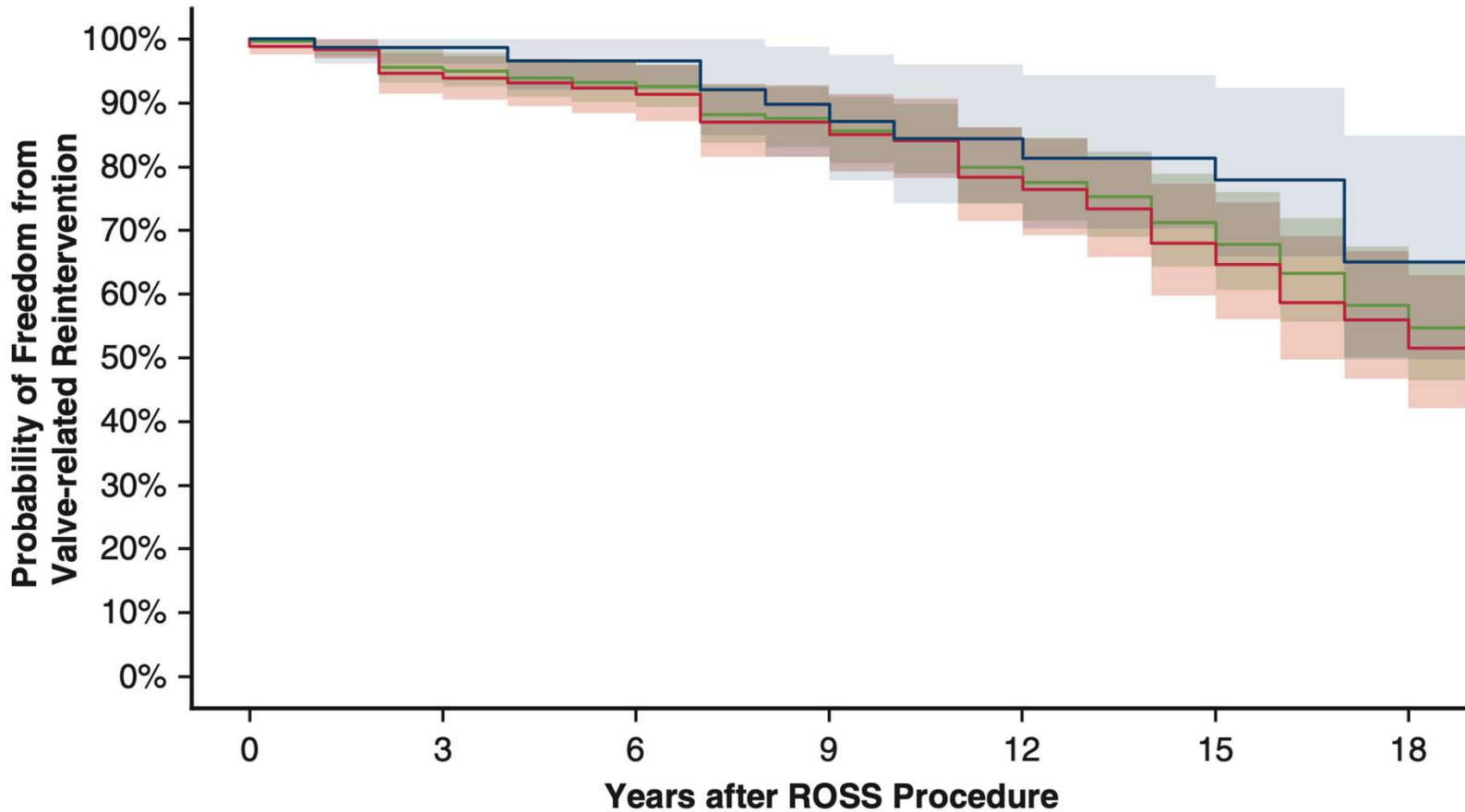
Outcomes of the Ross procedure in patients older versus younger than 50 years old

Emily Shih ^{a,b,*}, William H. Ryan^a, John J. Squiers^a, Justin M. Schaffer^a, Katherine B. Harrington^a,
 Jasjit K. Banwait^b, Talia G. Meidan^b, J. Michael DiMaio ^{a,b} and William T. Brinkman^a



Although survival was worse in the >50 yo cohort, survival was similar to age/sex matched controls for both groups

Probability of Freedom from Valve-related Reintervention Measured in Yearly Intervals



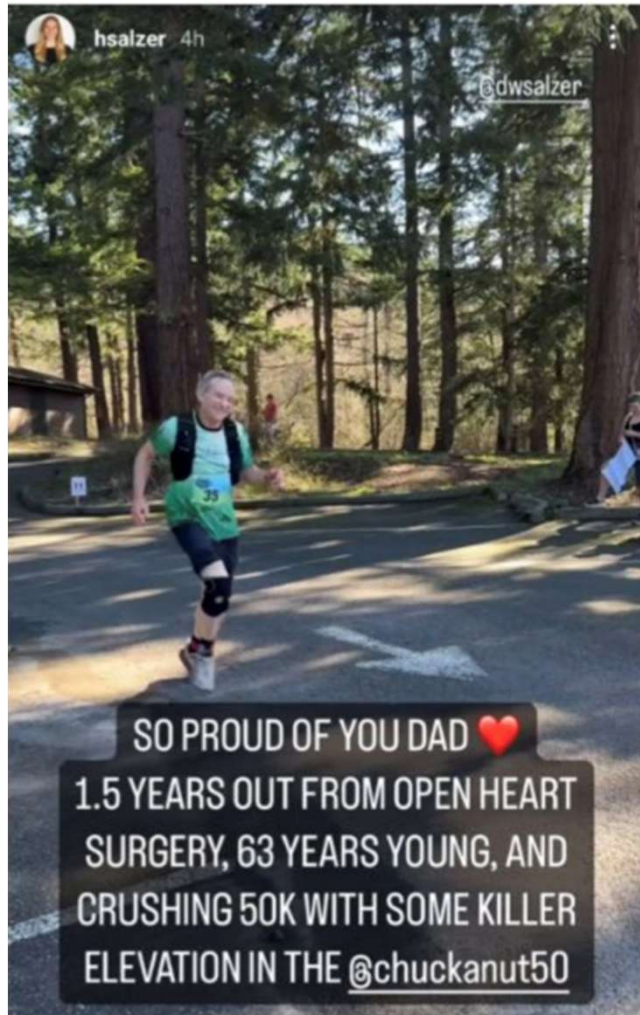Number at risk (number of events)

—	346 (3)	189 (13)	149 (17)	130 (28)	108 (39)	84 (51)	51 (64)
—	262 (3)	138 (12)	106 (15)	96 (22)	80 (31)	60 (42)	38 (52)
—	84 (0)	51 (1)	43 (2)	34 (6)	28 (8)	24 (9)	13 (12)

A

— All Patients — Patient Age < 50 years old — Patient Age ≥ 50 years old

1.5 years s/p Ross



- Age is an incomplete predictor of life expectancy
- Ross > 60 yo should be a **very** selective, individualized occurrence

Expanded Criteria Ross

Anatomic

- AR predominant
- Annular mismatch
- Root aneurysm
- PV fenestrations
- Bi/Quadricuspid PV
- Redo/hostile chest

Patient

- Older age
- Depressed EF
- Previous radiation (mantle)
- Severe inflammatory disease
- Genetic aortopathy
- Endocarditis

Cite this article as: Abeln KB, Becker SL, Müller SE, Schneider M, Schäfers H-J. Role of the Ross Procedure and Stentless Biological Prostheses in Acute Aortic Valve Endocarditis. *Eur J Cardiothorac Surg* 2026; doi:10.1093/ejcts/ezaf460.

Role of the Ross Procedure and Stentless Biological Prostheses in Acute Aortic Valve Endocarditis

Karen B. Abeln ^{*,1,2}; **Sören L. Becker**^{2,3}; **Sophie E. Müller**³; **Maximilian Schneider**²;
Hans-Joachim Schäfers ^{2,4,5}

¹Department Cardiovascular Surgery, Saarland University Medical Center, 66424 Homburg/Saar, Germany

²Saarland University, 66424 Homburg/Saar, Germany

³Institute of Medical Microbiology and Hygiene, Saarland University, 66424 Homburg/Saar, Germany

⁴Prof. Emeritus, Saarland University, 66424 Homburg/Saar, Germany

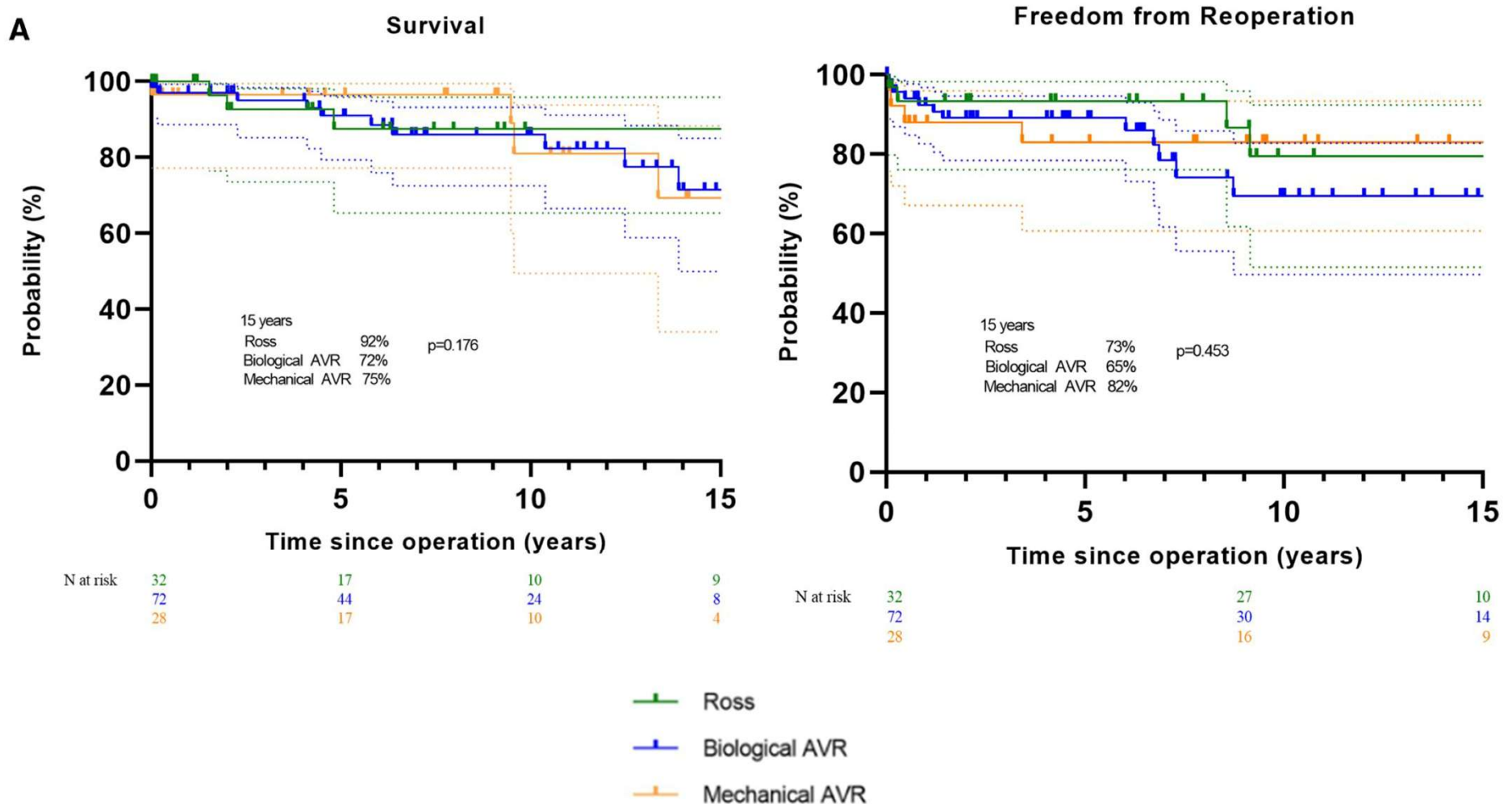
⁵Department of Thoracic and Cardiovascular Surgery, Westpfalz Hospital, 67655 Kaiserslautern, Germany

*Corresponding author. Department of Cardiovascular Surgery, Saarland University Medical Center, Kirrbergerstr. 100, 66424 Homburg/Saar, Germany (karen.abeln@uks.eu).

Received: September 19, 2025; Revised: November 19, 2025; Accepted: December 3, 2025

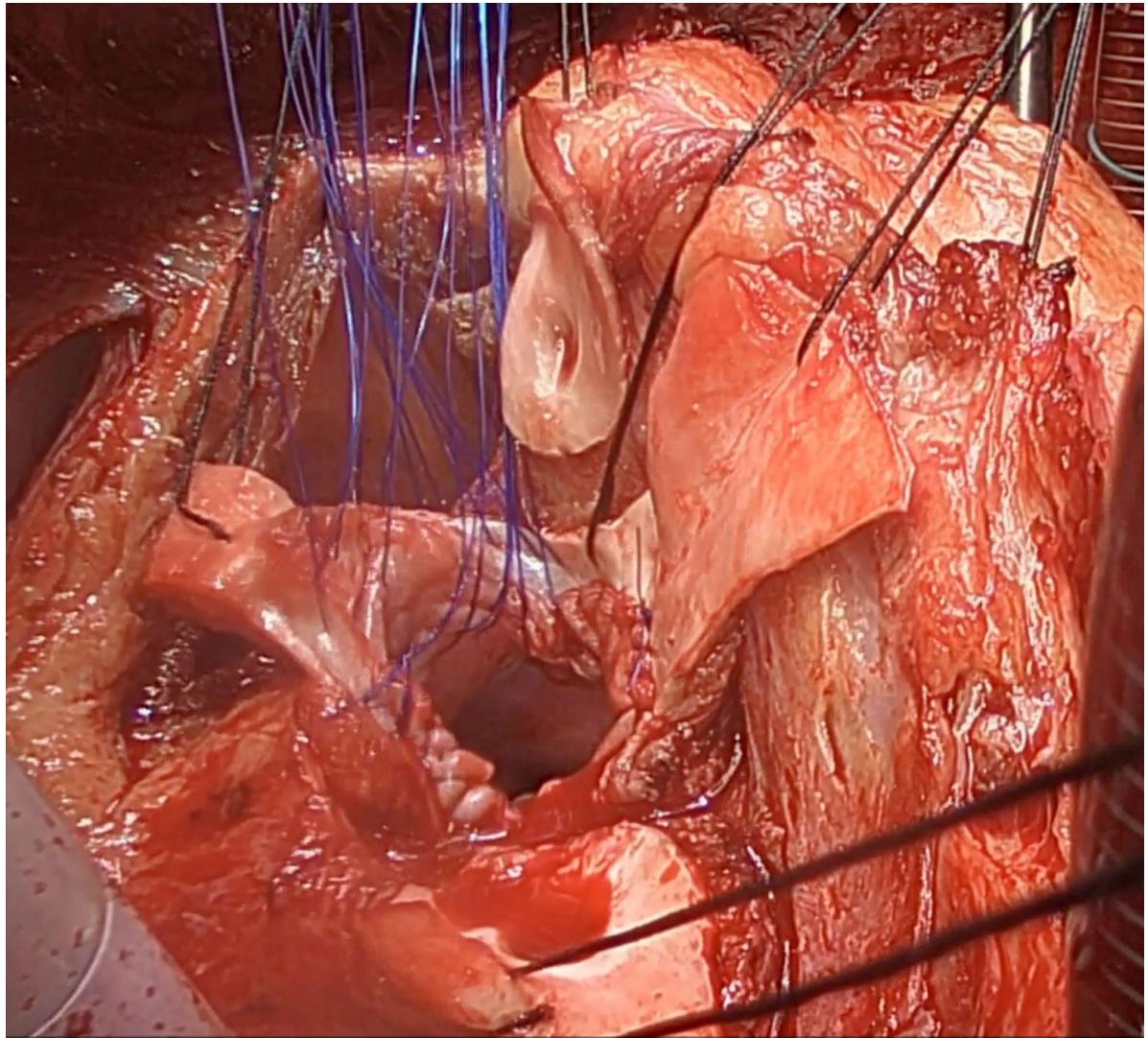
Role of the Ross Procedure and Stentless Biological Prostheses in Acute Aortic Valve Endocarditis

Karen B. Abeln ^{ID}*,^{1,2}; Sören L. Becker^{2,3}; Sophie E. Müller³; Maximilian Schneider²;
 Hans-Joachim Schäfers ^{ID}^{2,4,5}





**Caution with
severe
abscess/annular
destruction!**










Others









- **Depressed EF:** Very selective, AS probably better than AR, LV size?
 - *Role of TAVR to rehabilitate LV followed by Ross??*
- **Mantle Radiation:** Absolute contraindication
- **Inflammatory Disease:** Reasonable if “controlled”
- **Genetic Aortopathy:** Rarely comes up, autograft support essential

Expanded Criteria Ross

Anatomic

- AR predominant  *
- Annular mismatch  *
- Root aneurysm  *
- PV fenestrations 
- Bi/Quadricuspid PV 
- Redo/hostile chest  

Patient

- Older age 
- Depressed EF  
- Previous radiation (mantle) 
- Severe inflammatory disease 
- Genetic aortopathy  
- Endocarditis 

Thank you!

