

Robotic Myectomy

Danny Ramzy, MD PhD

Professor and Chief of Cardiac Surgery
UTHealth Houston Endowed Chair in Cardiac Surgery

Department of Cardiothoracic and Vascular Surgery
McGovern Medical School at UTHealth
Memorial Hermann Heart & Vascular Institute

Department of
**Cardiothoracic &
Vascular Surgery**

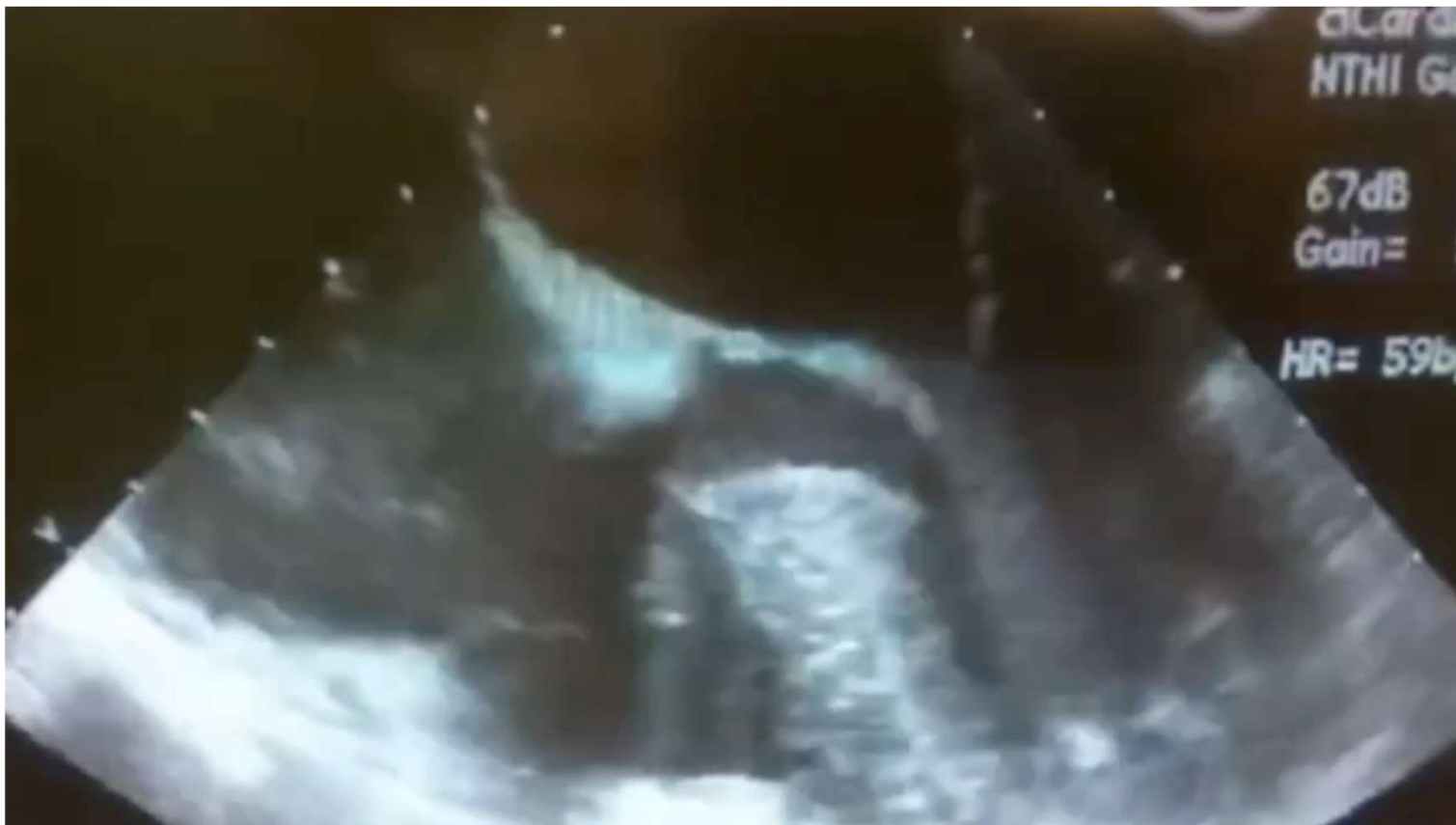UTHealth Houston
Heart & Vascular

MEMORIAL
HERMANN
Heart & Vascular

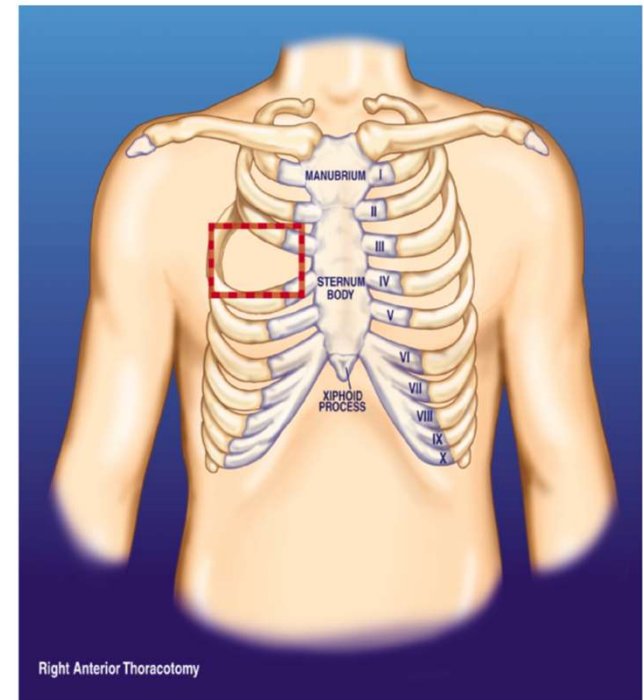
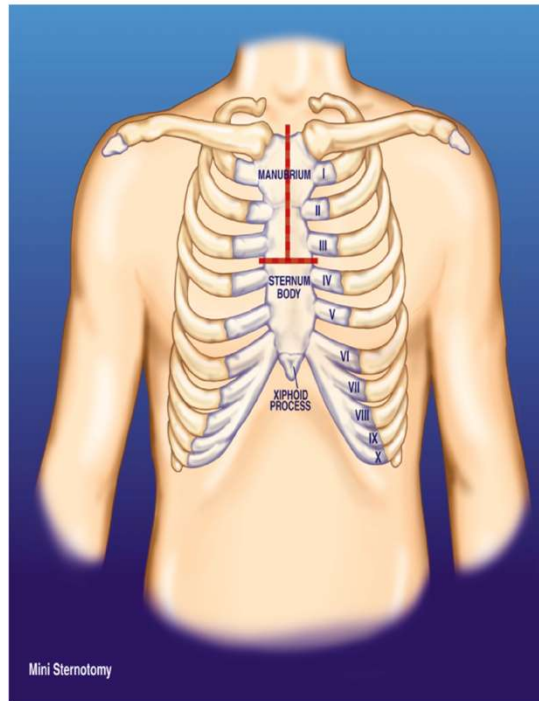
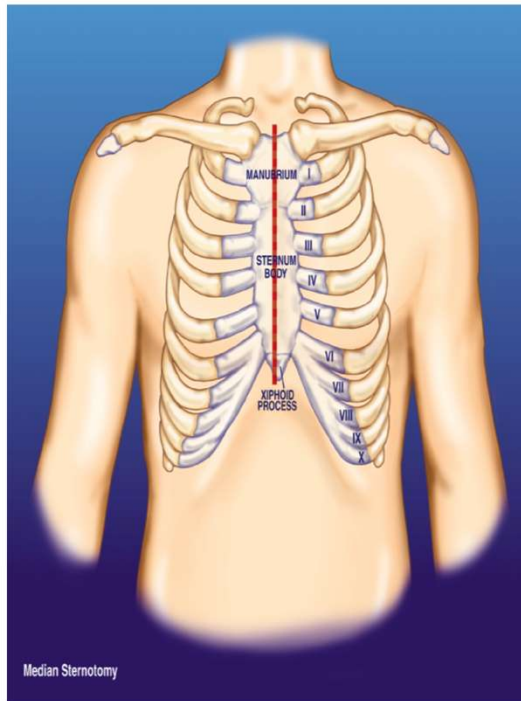
Pre operative History

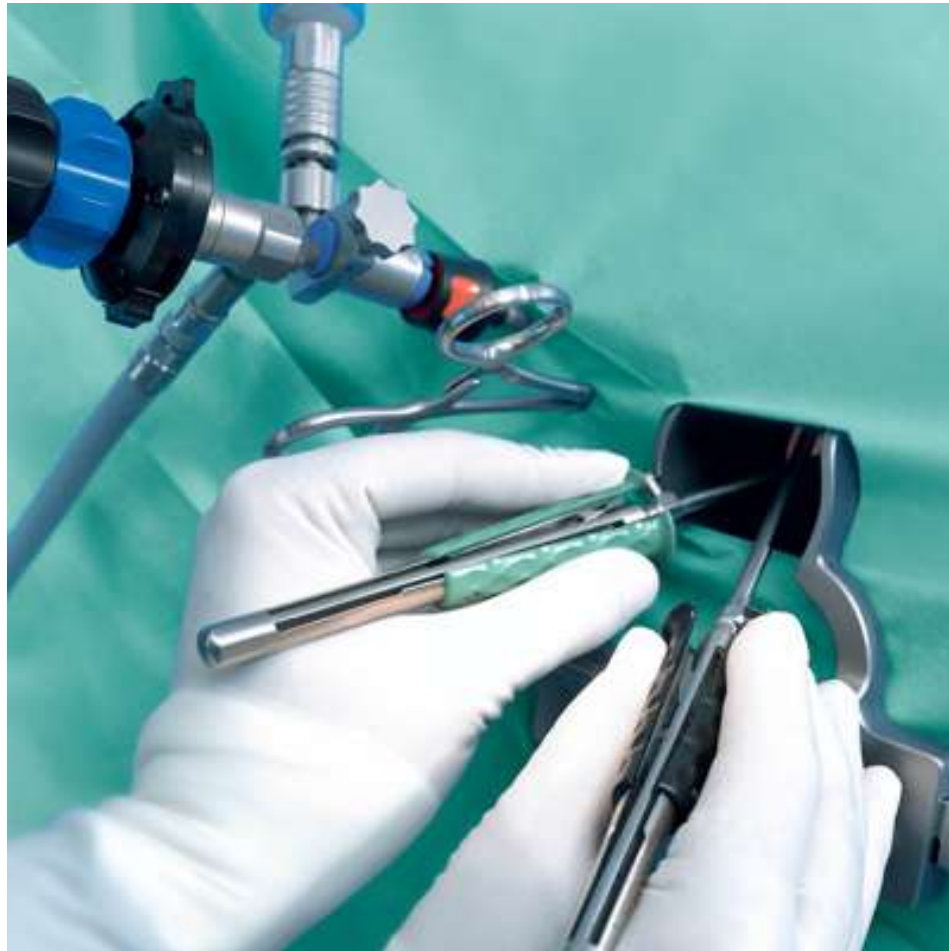- 48-year-old female
- Symptoms of exercise intolerance and fatigue.
- He was found to have asymmetric septal hypertrophy
- Gradient mean 68mmHg peak 129mmhg

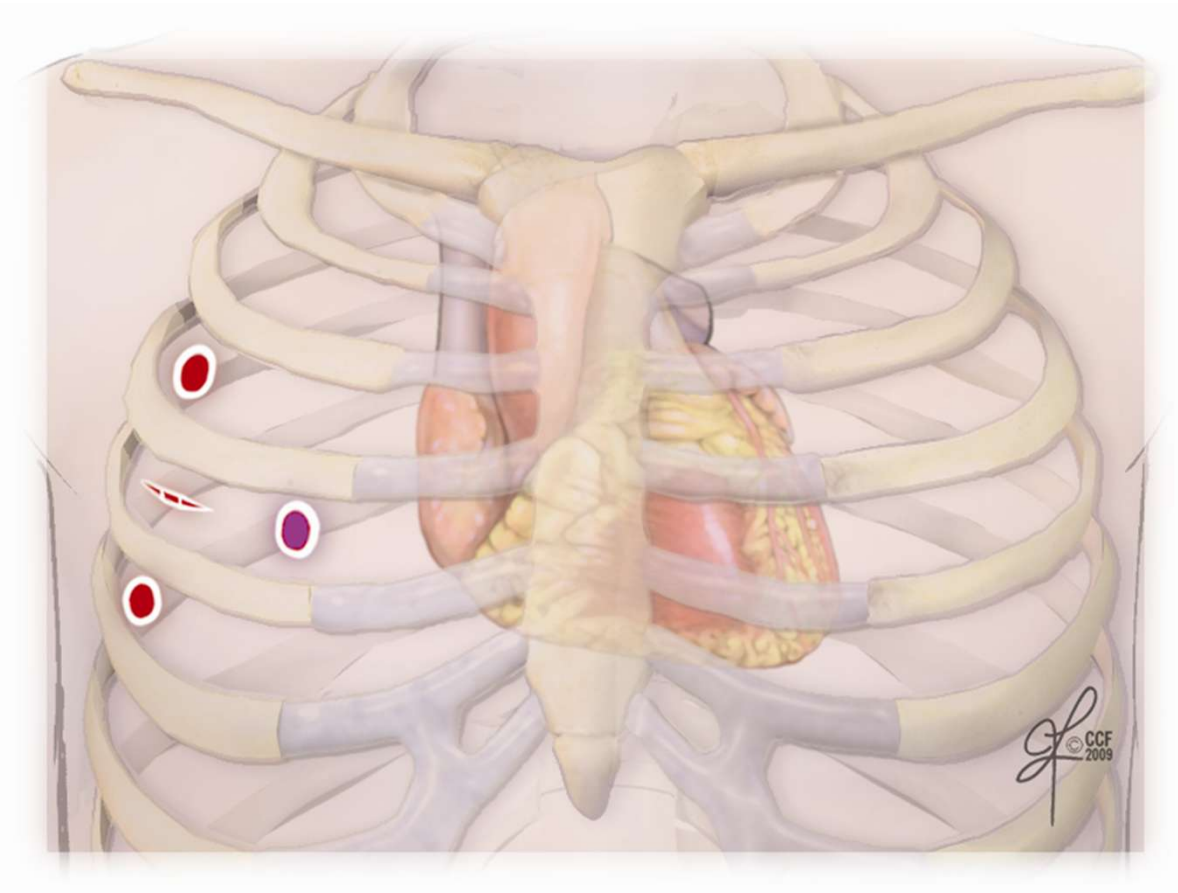
Pre operative Echo



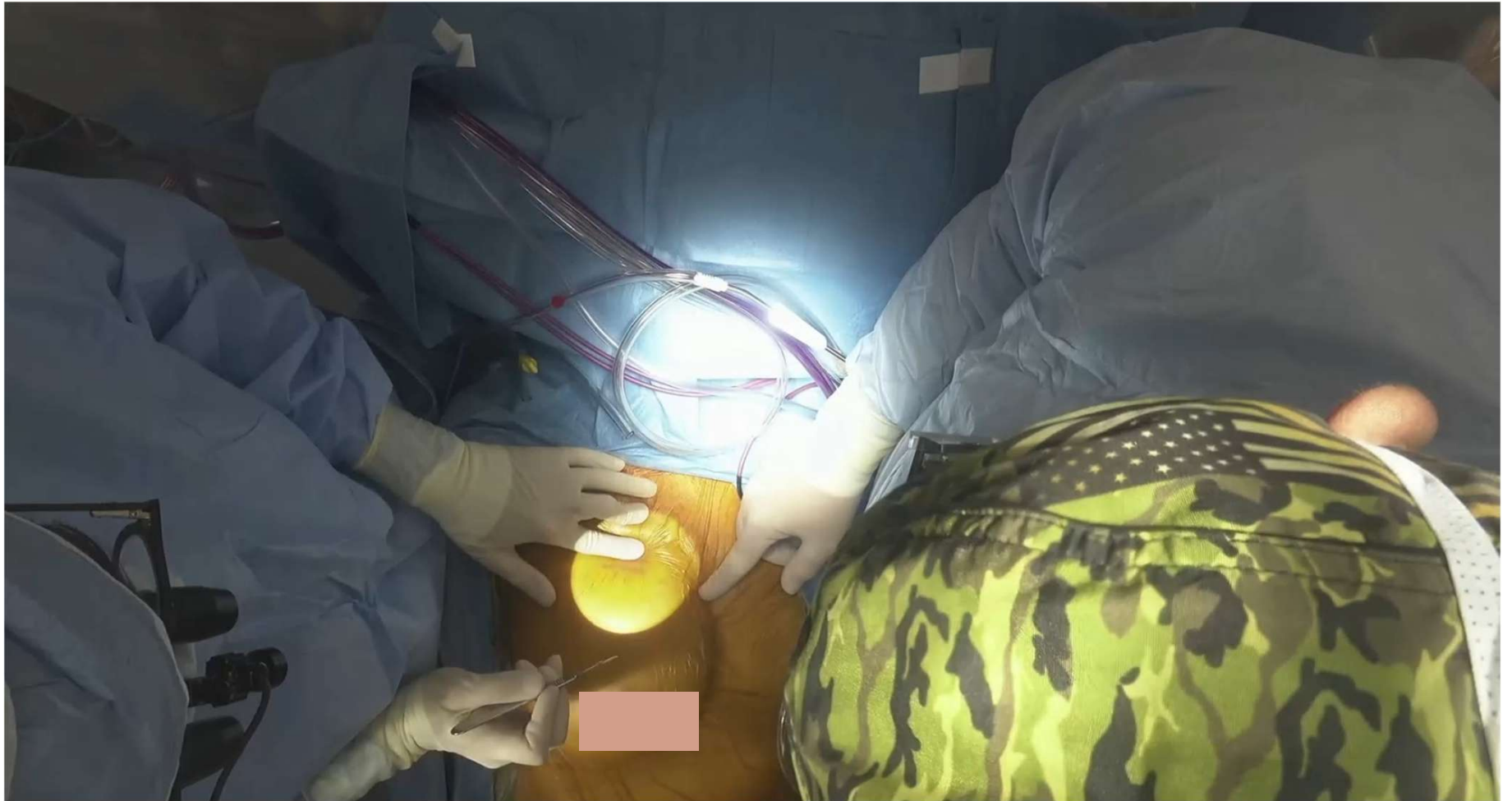Surgical Approaches





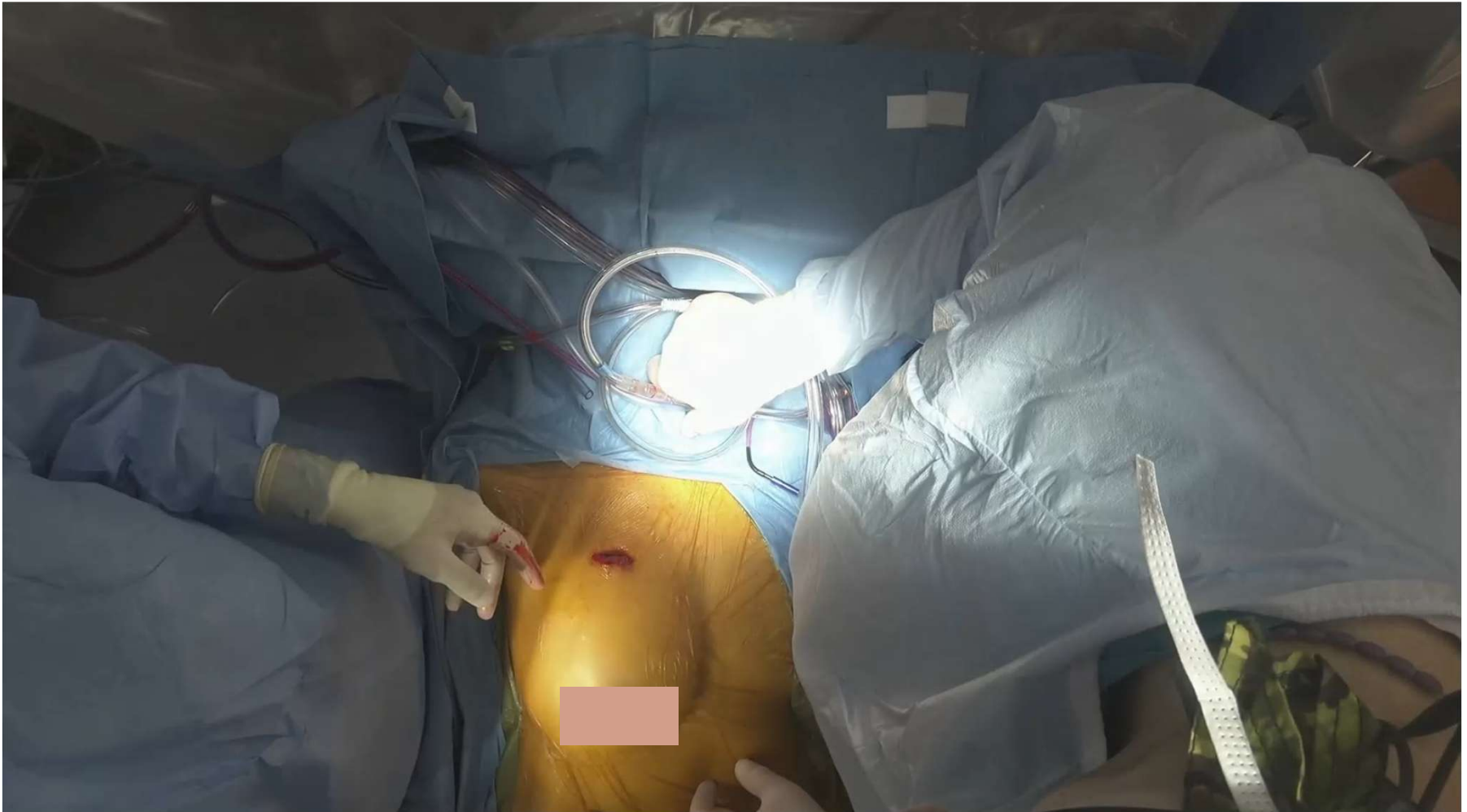

Incision for working port

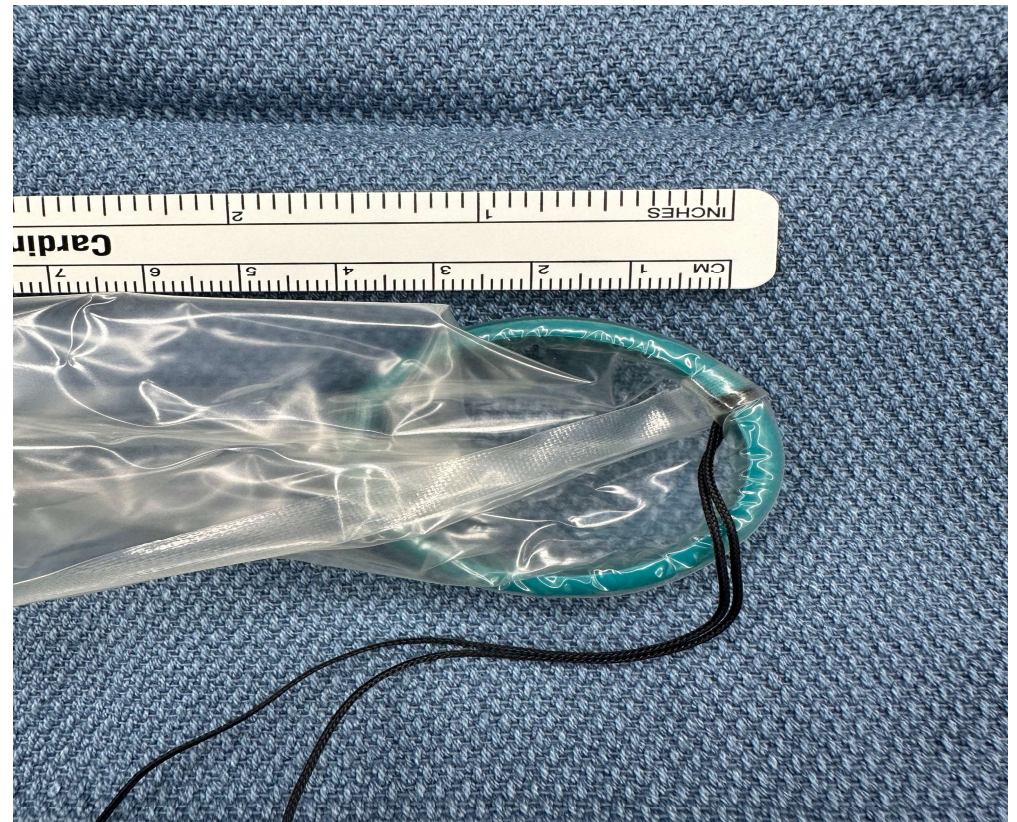
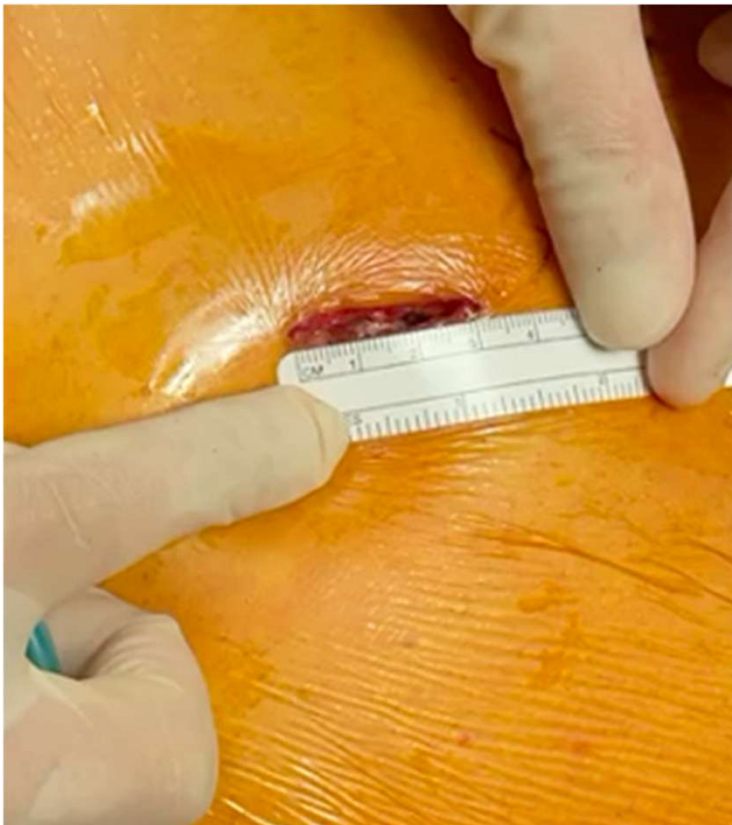
XXS Alexis soft tissue retractor

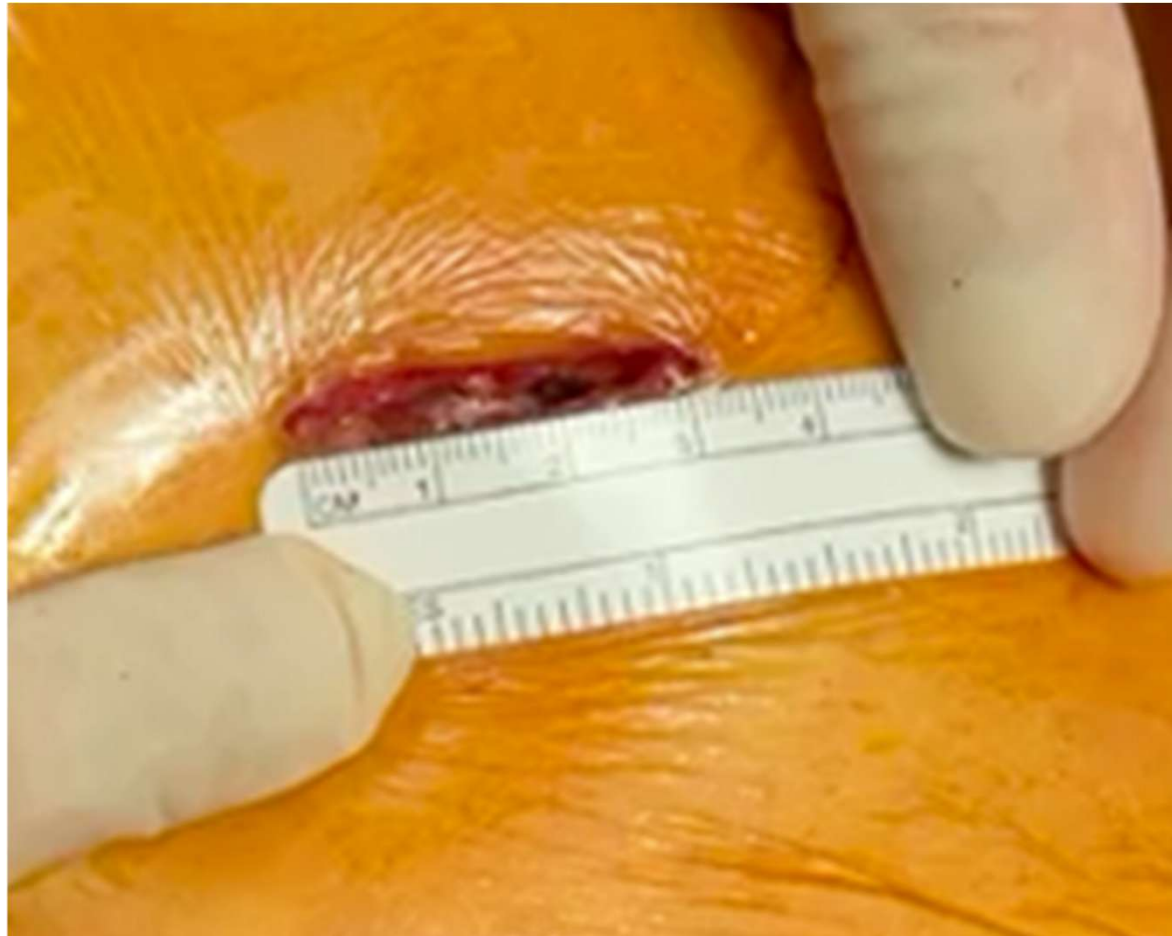UTHealth Houston
Heart & Vascular

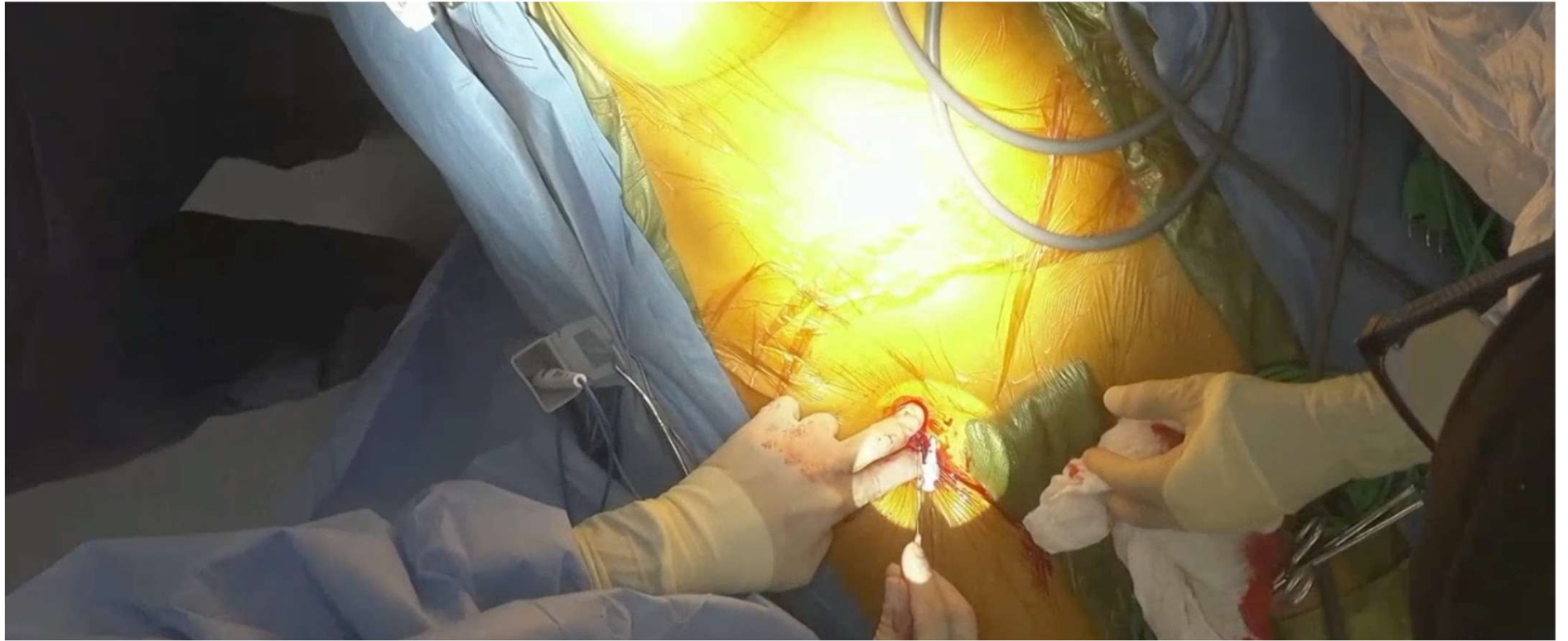


Working Port

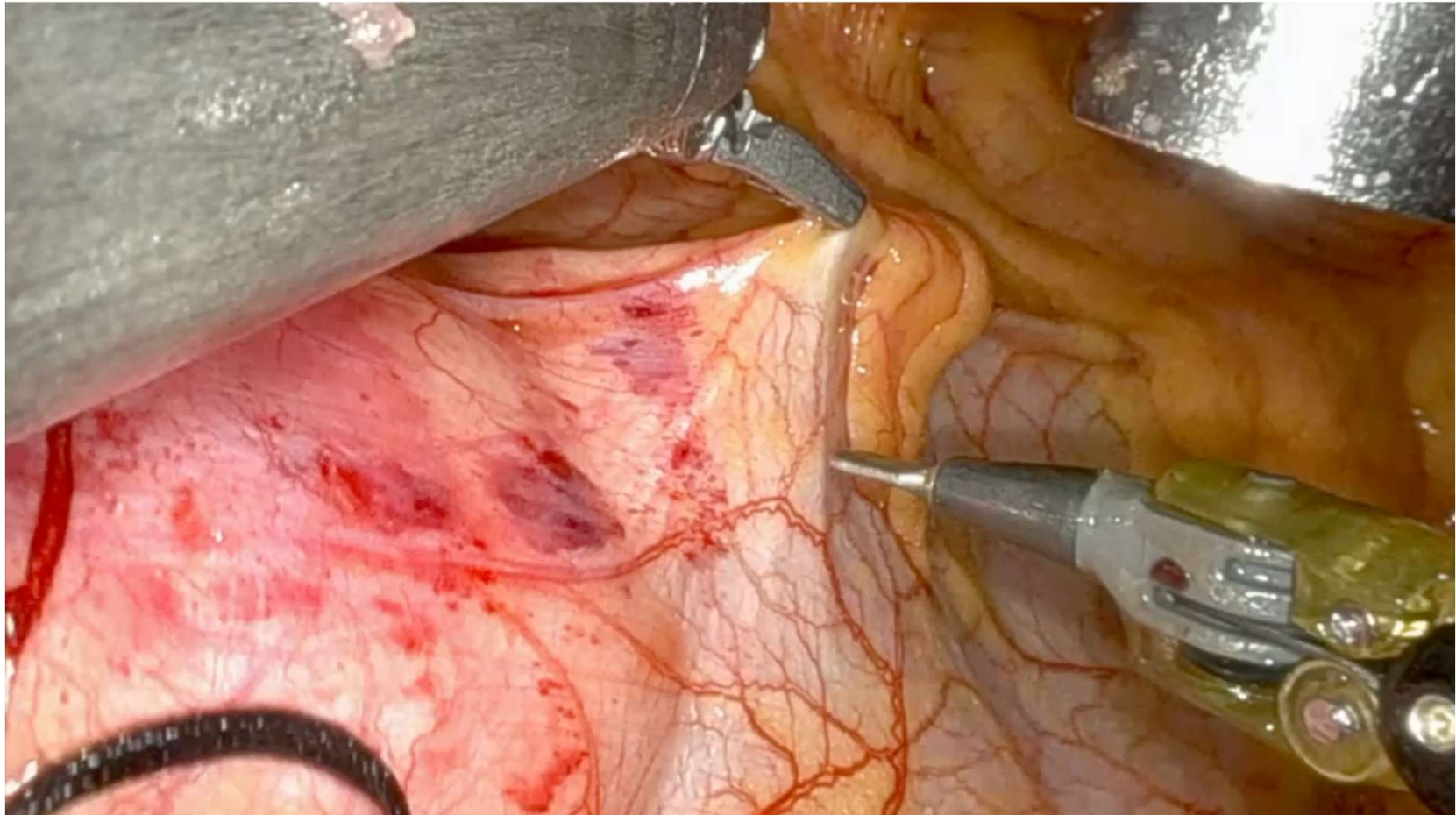


Working Port



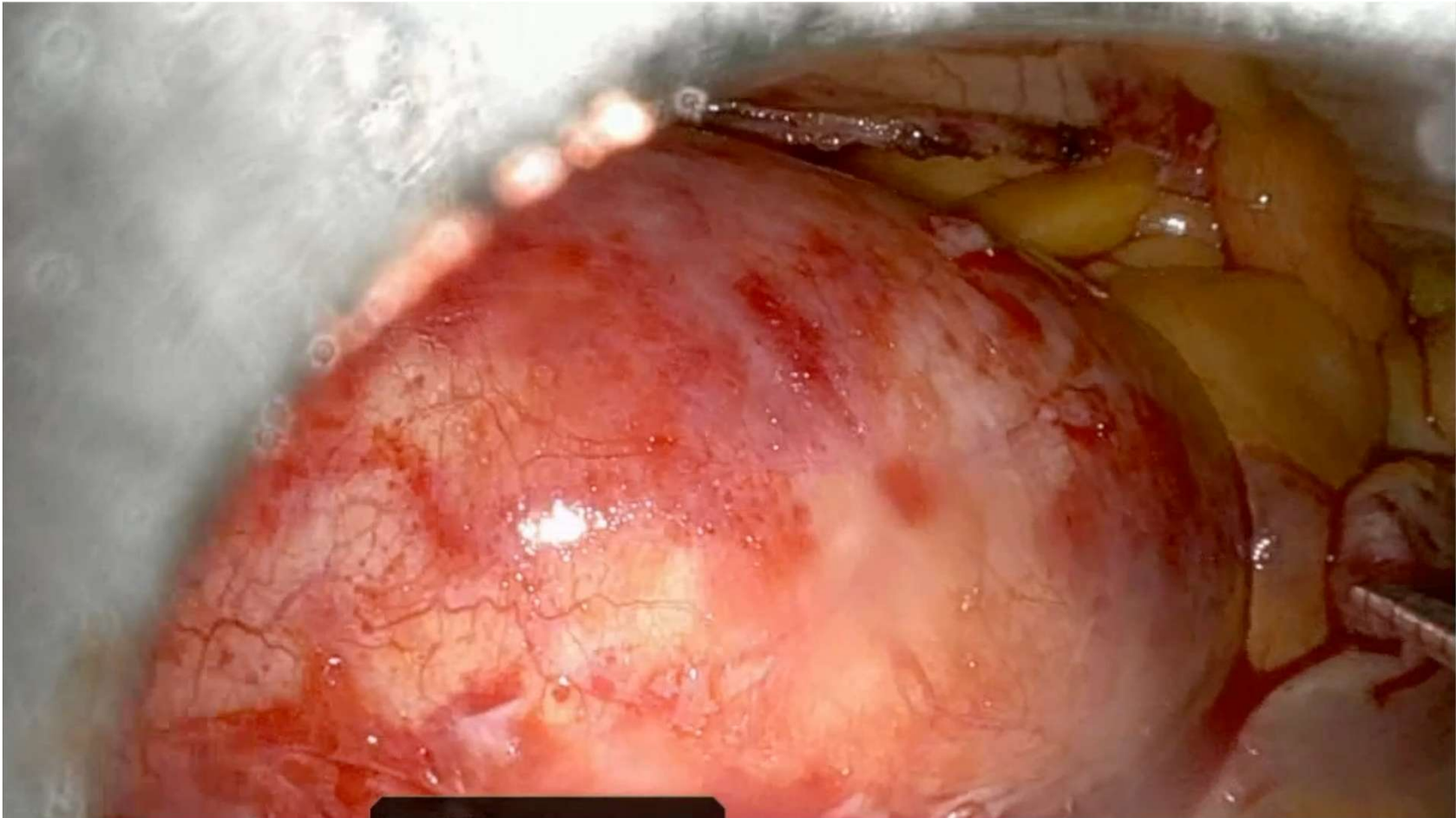


Pericardial Window

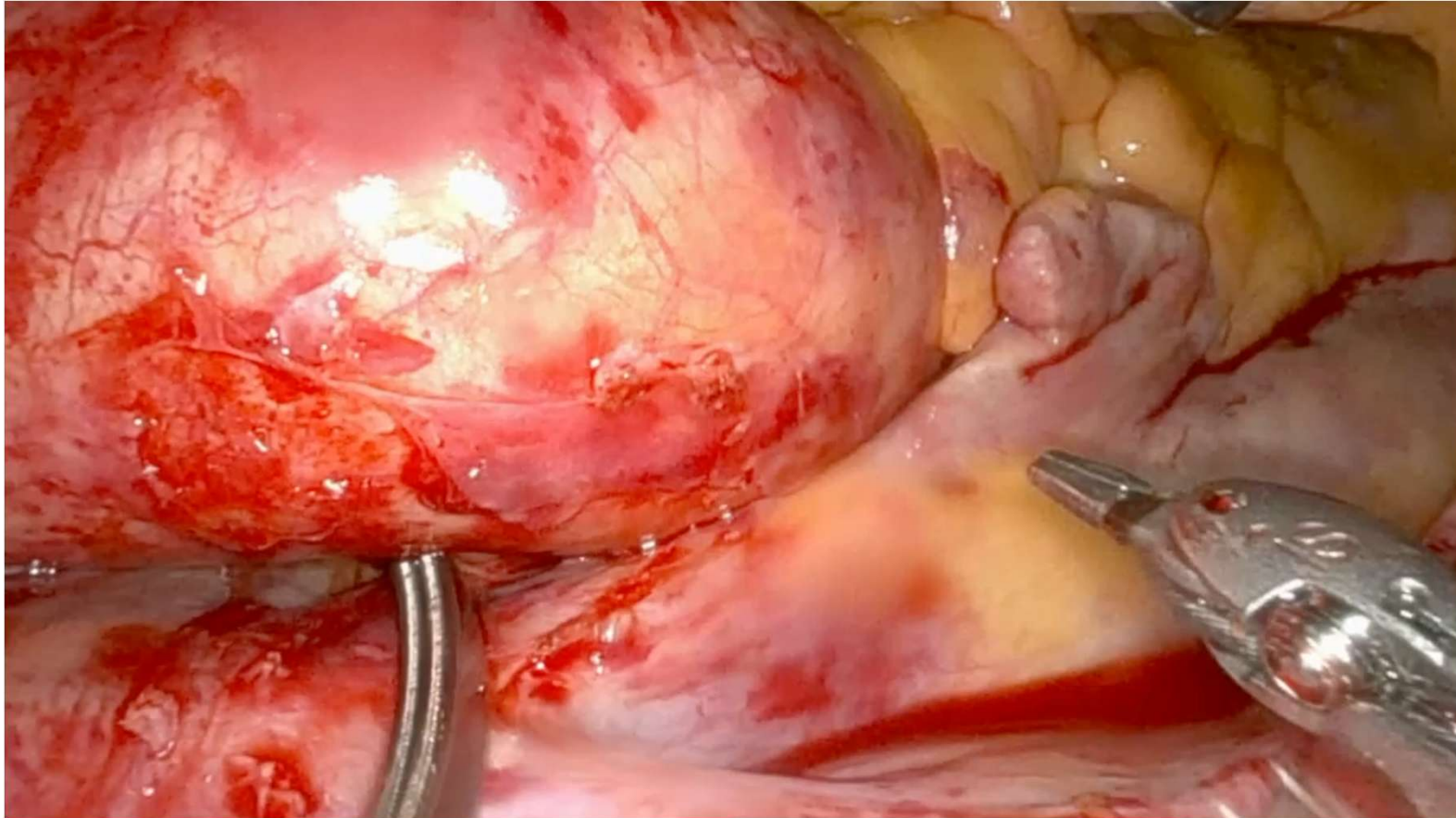


Cross Clamping and cardioplegia

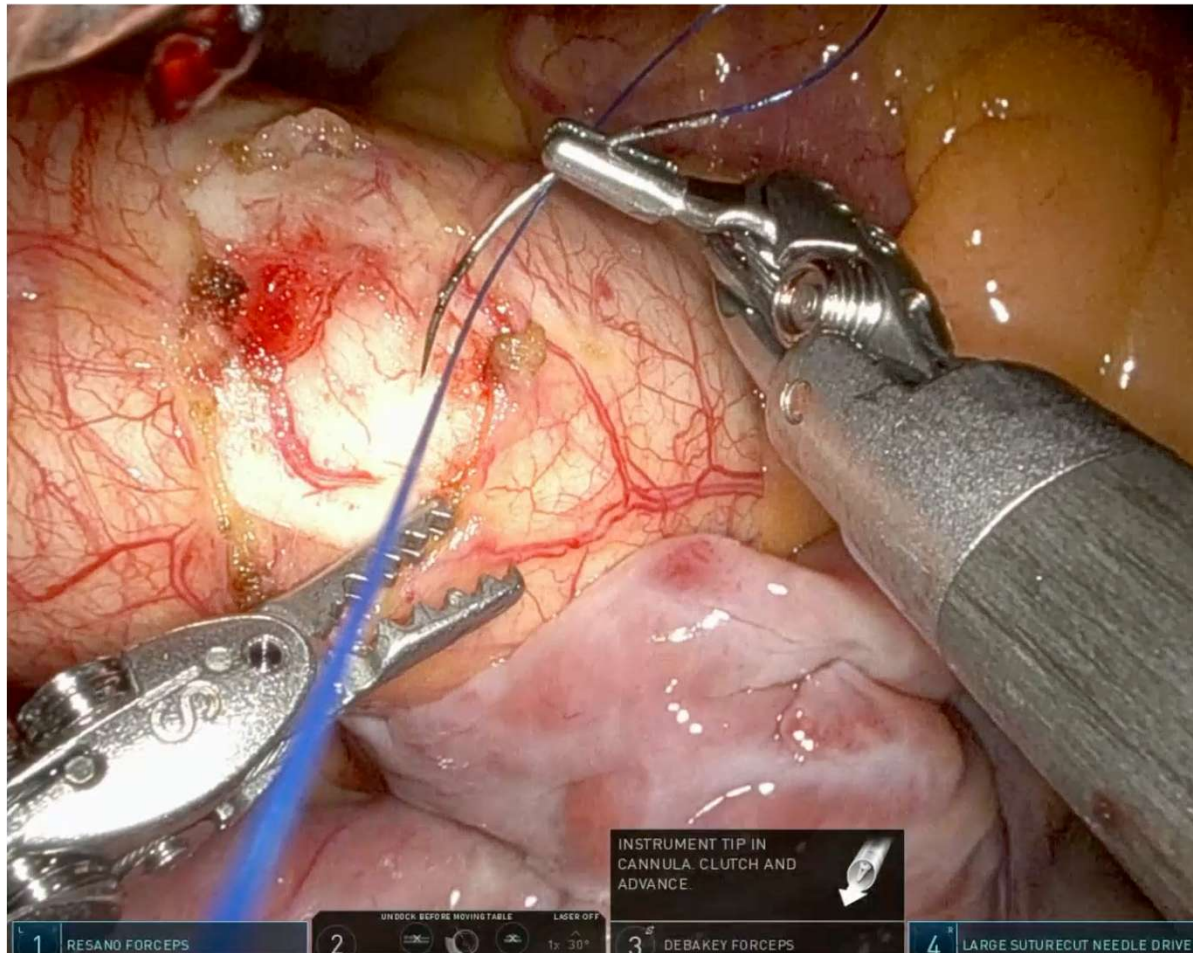
UTHealth Houston
Heart & Vascular

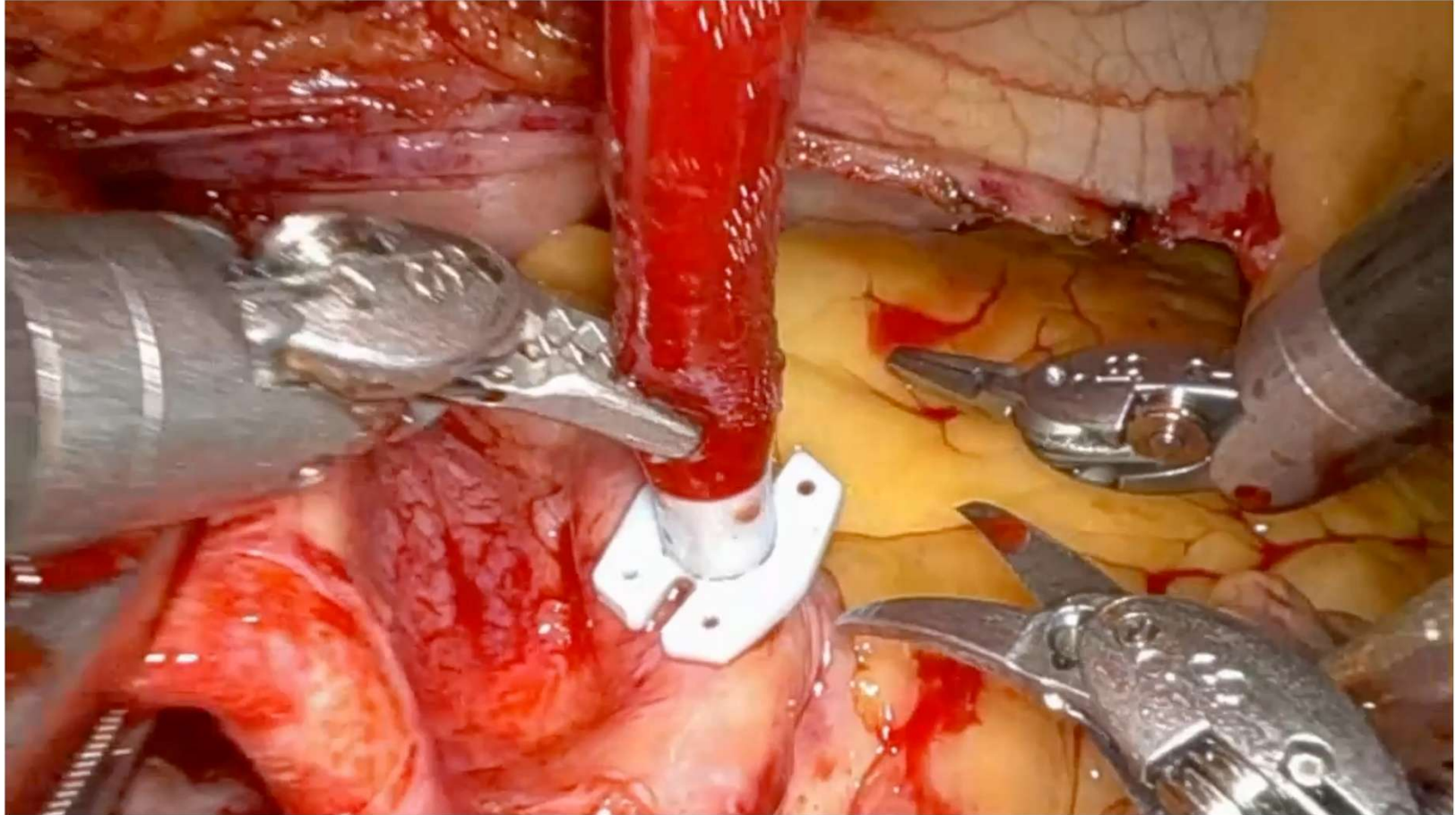


Cross Clamping and cardioplegia

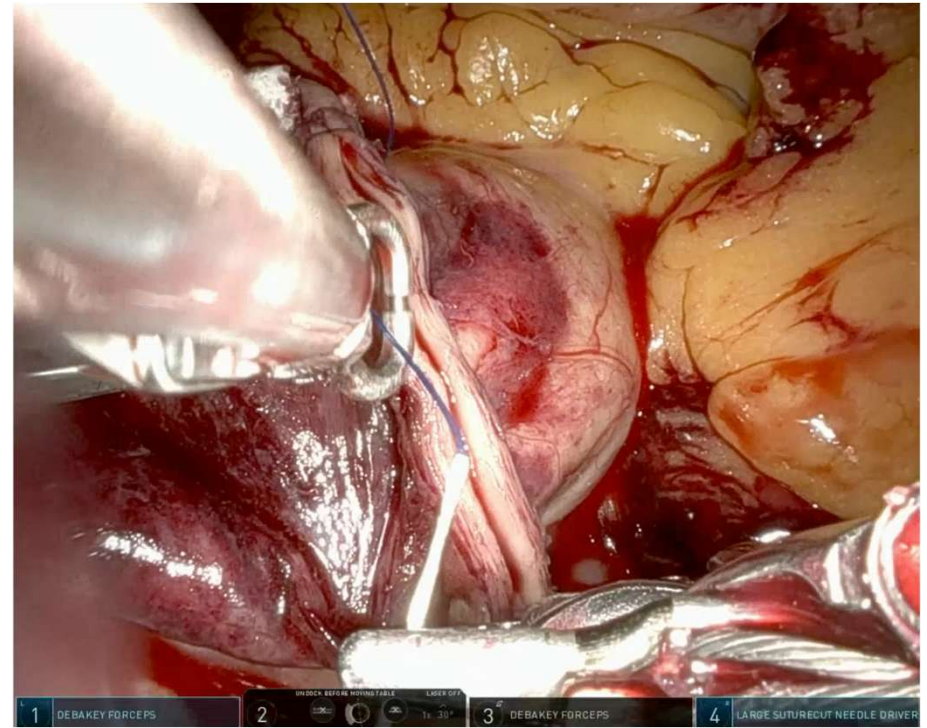
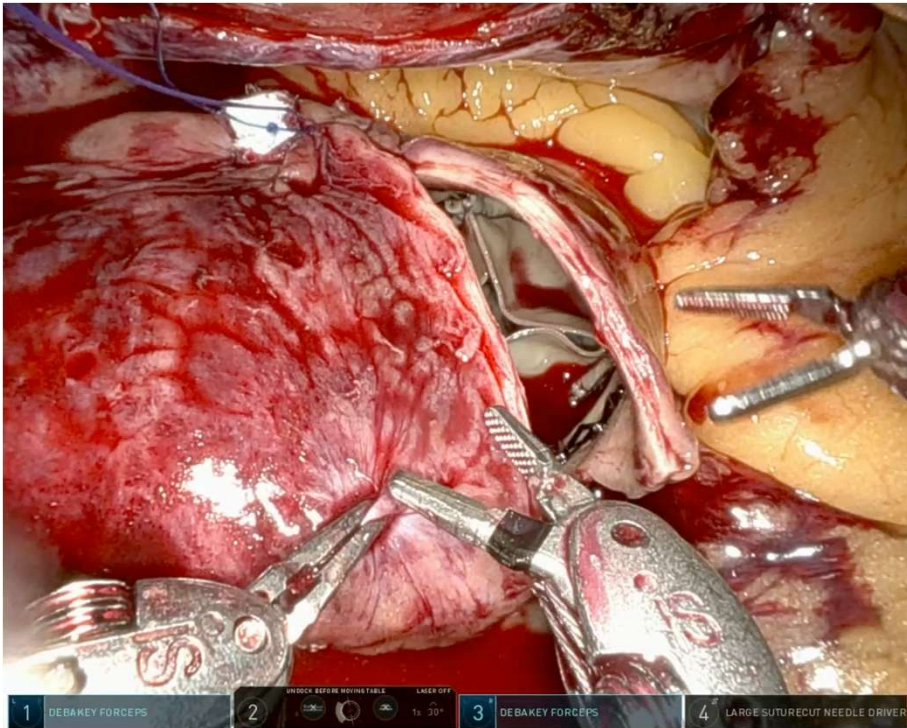


Cross Clamping and cardioplegia

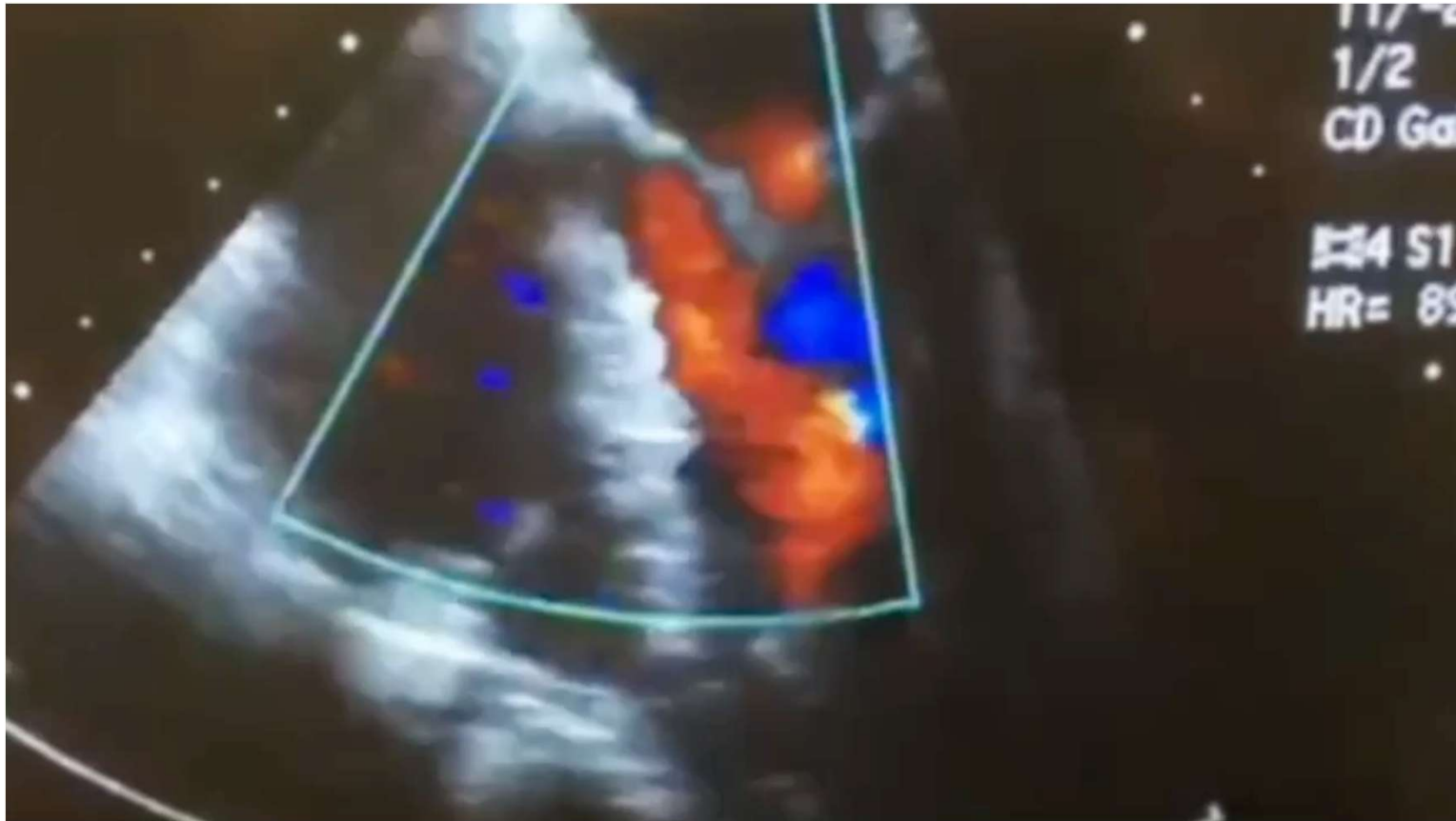




Aortotomy Closure

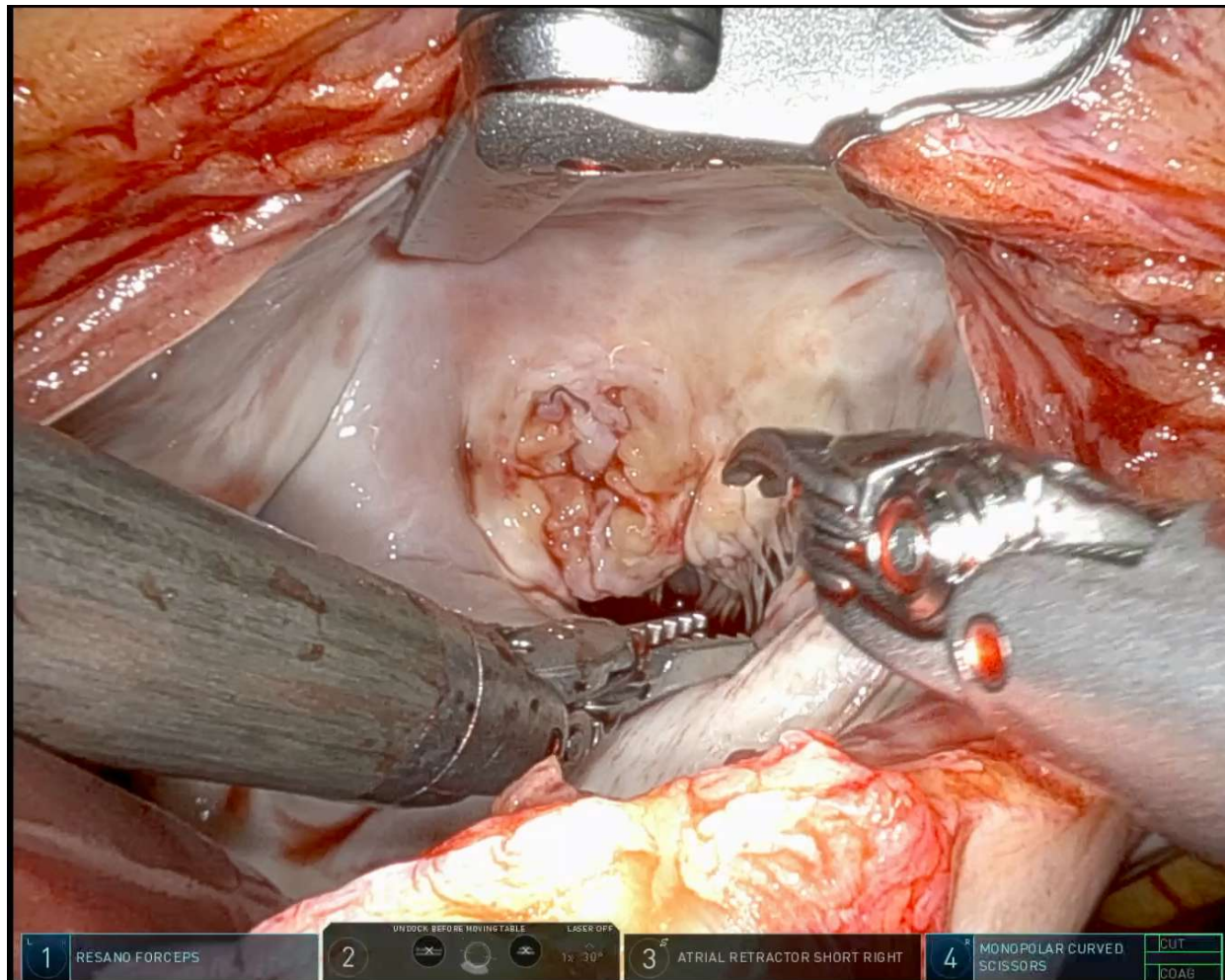


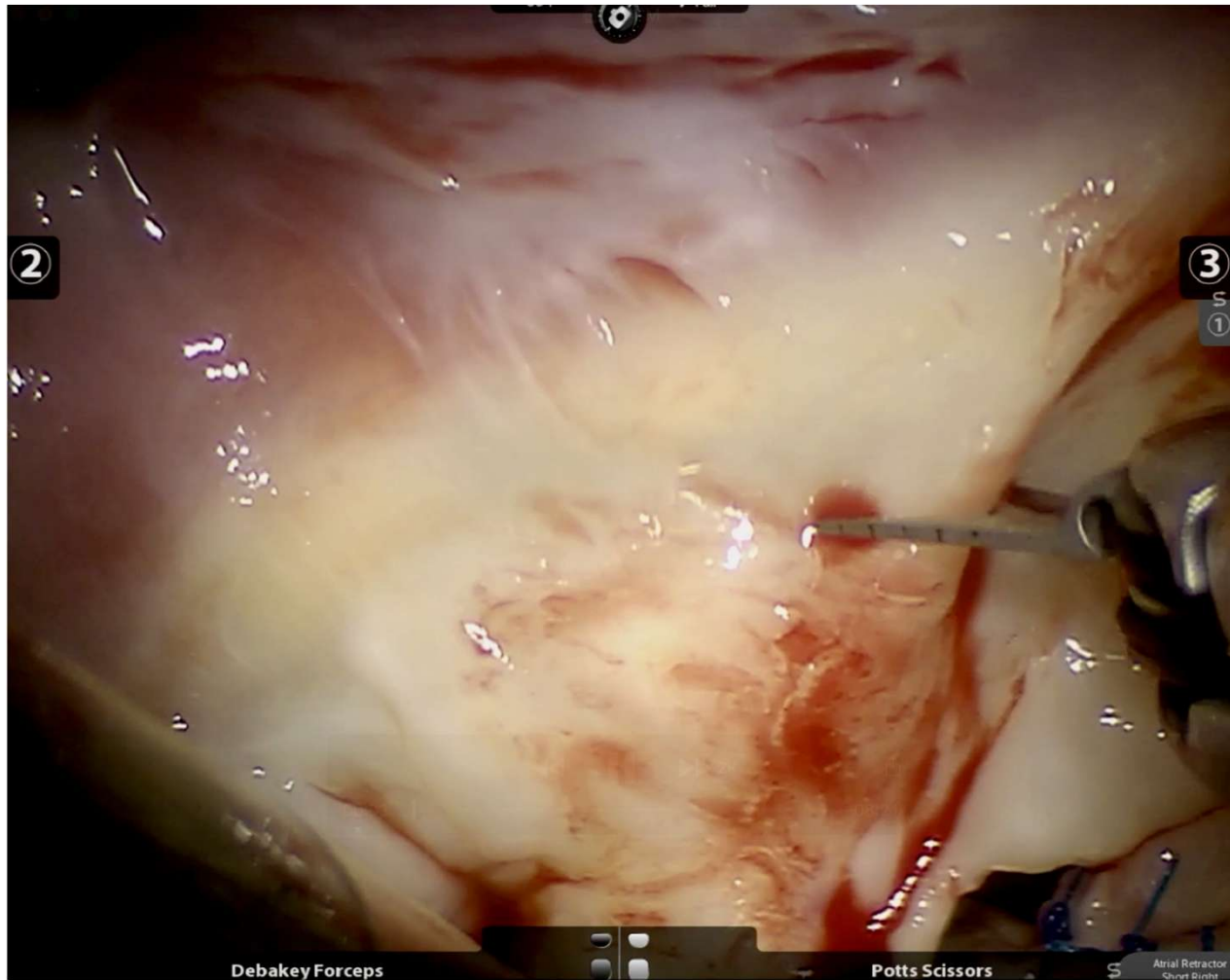
Post operative Echo



Post op Course

- Patient extubated in the OR
- Ambulation post op day zero
- Minimal pain no narcotics. Preop paravertebral block and intraop cryoneuraxial block
- Chest tube removed post op day one and two
- Discharged home on post operative day 2





In Conclusion

- **Robotic myectomy is feasible**
- **Approach is dictated by the need for concomitant procedures**
- **Robotic myectomy offers superior visualization and dexterity**

Thank You!